

LYMPH NODE ASPIRATION CYTOLOGY FINDING IN HIV INFECTED CASES OF A RURAL POPULATION IN SOUTH INDIAAmrutha Gorva¹, Satyanarayana Veeragandham², V. G. Prasad³**HOW TO CITE THIS ARTICLE:**

Amrutha Gorva, Satyanarayana Veeragandham, V. G. Prasad. "Lymph Node Aspiration Cytology Finding in HIV Infected Cases of a Rural Population in South India." *Journal of Evolution of Medical and Dental Sciences* 2015; Vol. 4, Issue 83, October 15; Page: 14576-14581, DOI: 10.14260/jemds/2015/2072

ABSTRACT: OBJECTIVE: To evaluate the findings of aspiration cytology of lymph nodes in HIV infected subjects in a rural population. **STUDY DESIGN:** The study was conducted in rural population of field practice area of Kamineni institute of medical sciences (KIMS), Narketpally, Nalgonda. Fine needle aspiration (FNA) was done from different lymph-node site from 50 HIV infected subjects, both air dried and wet smears were prepared. Routine cytology stains and when required special stain were done. Detailed cytomorphological study was conducted. **RESULTS:** Tuberculus lymphadenitis 28(56%) was most common finding followed by reactive lymphadenitis 14(28%), Granulomatous lymphadenitis 6(12%) and suppurative lymphadenitis 2(4%). No other opportunistic infection or malignancy was seen in our study. **CONCLUSION:** Tuberculus lymphadenitis is the most common cause of lymphadenopathy in HIV infected individuals followed by reactive lymphadenitis. Fine needle aspiration cytology (FNAC) is a very useful tool in early diagnosis of opportunistic infection and in providing appropriate treatment.

KEYWORDS: Lymphadenopathy, HIV infected subjects, FNAC, Rural population.

INTRODUCTION: Profound immunosuppression caused by Human Immunodeficiency Virus(HIV) is the second and third most common cause of death worldwide in HIV infected AIDS patients among them common age group is 25 to 44 years in men and women respectively. And incidence in pediatric age group is about 2%.^[1] The incidence of HIV is increasing in Africa (65%) and Asia (20%), particularly in Indian subcontinent with prevalence of both HIV 1 & HIV 2.^[1] Great advances in investigating techniques and treatment protocol, providing patients with HIV an opportunity to prolong life, despite the presence of disease.^[2] Lymphadenopathy is one of the earliest manifestation of HIV infection. HIV is associated with number of opportunistic infections like mycobacterial tuberculosis, mycobacterium avium-intracellulare, Cryptococcus, histoplasmosis etc.^[2] Malignancy involving the lymph node in the form of lymphoma.^[2] In developing countries like India with huge population and socio-economic constraints, there is need for simple feasible investigative technique for HIV infected lymphadenopathy.^[2] FNAC is one such technique which is less time consuming and well tolerated by patients and it can be carried out in out-patient setting.^[2]

MATERIALS AND METHODS: The study was conducted on rural population covered under rural health center at KIMS hospital, Narketpally, Nalgonda district, Telangana, India during the period September-2011 to August-2013. The clinical subjects include 56 HIV positive patients with lymphadenopathy attending Cytology OPD/admitted to KIMS hospital. All the cases were proved to be HIV positive as per NACO guidelines. Ethical approval was taken for this study from the institutional ethics committee KIMS, Narketpally. Prior to FNAC, the patients were examined in detail, which included thorough physical examination regarding size and multiplicity of lymph nodes. After a brief explanation of the technique, an informed consent of the patient was obtained.

ORIGINAL ARTICLE

Subsequently, FNAC was done using 23G needle attached to 20CC syringe. Smears were air dried and wet fixed and stained with hematoxyline and eosine, Giemsa and Z-N stain for AFB. Periodic Acid Schiff (PAS) stain for fungi was performed whenever required. After staining, a detailed cytomorphological study was conducted.

RESULTS: In present study FNAC of lymph nodes were done in 56 patients coming to Kamineni hospital, Narketpally, Nalgonda district. Material was obtained in 50 cases and rest 6 cases had insufficient material. Lymphadenopathy in HIV cases were studied with respect to age distribution, sex distribution, site and cytological finding. In present study individuals between 11-70 years were included, HIV was more prevalent among 21-30 years (44%) of age group. (Table: 1). of 50 HIV infected patients, 35(70%) male patient are more prevalent then female patients (30%). In our study cervical lymphadenopathy (92%) was most common presentation.

Two cases showed axillary lymphadenopathy along with cervical lymphadenopathy, one case presented with bilateral inguinal lymphadenopathy, and one case with generalized lymphadenopathy. (Table: 2) Various cytological finding were seen in present study (Table: 3), among these Tuberculous lymphadenopathy (56%) was most common cytological finding. Caseous tuberculous lymphadenitis was most common patterns of tuberculous lymphadenitis, where caseous necrosis was seen in 25(78.57%) out of 28 cases. Tuberculous lymphadenitis was categorized into patterns namely only caseous, caseous with epithelioid cell granuloma, only epithelioid granuloma without caseous necrosis and suppurative.

(Table: 4) Among these caseous with epithelioid cell granuloma were the predominant finding in 21(75%) followed by only caseous 4(14%), 2(7%) cases with only epithelioid cell granulomas. In cases with both caseous necrosis and epithelioid cell granulomas, only 6 cases out of 21 cases showed AFB positive on ZN stain, in other cases diagnosis was given on the presence of caseous necrosis and epithelioid cells. Only caseous necrosis was seen in 4 out of 28 cases, out of these 3 cases showed AFB positive bacilli on ZN stain. Two cases out of 28 cases showed only epithelioid cells granulomas with no caseous necrosis, but showed AFB positive bacilli on ZN stain. One case showed suppurative background with no caseous necrosis or epithelioid cells granulomas, which showed strong positivity for AFB bacilli on ZN stain.

Reactive lymphadenitis was second most common finding with 13(26%) cases showing predominantly small lymphocytes, transforming lymphocytes, centrocytes, centroblasts, tingible body macrophages and few histiocytes. Followed by granulomatous lymphadenitis 6(12%) with only epithelioid cell granuloma and negative for caseous necrosis and AFB bacilli on ZN stain, these were categorized as non-specific granulomatous lymphadenitis. Suppurative lymphadenitis was seen in 4%.(2) of cases with featur of dense acute inflammatory infiltrate with predominant neutrophils, few lymphocytes and necrotic debris in the background, and were negative for caseous necrosis, epithelioid granuloma and AFB. One case of Cryptococcus infection was diagnosed (2%).

DISCUSSION: According to WHO there are about 5 million people living with HIV in South, South- East and East Asia.^[3] People with HIV have 20–30 times higher lifetime risk of developing active TB, compared to people without HIV.^[4] In 2010, people living with HIV accounted for about 13% of tuberculosis cases worldwide, and about 3,60,000 died from HIV-related tuberculosis.^[5] Lymph nodes are the usual target organs affected in HIV/AIDS. FNAC has proven to be an easy, quick, reliable, and cost effective tool for lymphadenopathies.

ORIGINAL ARTICLE

It is suitable for an initial rapid diagnosis in HIV positive patients with lymphadenopathies.^[6] In present study cervical lymphadenopathy (92%) is most common presentation. Two cases showed axillary lymphadenopathy along with cervical lymphadenopathy, one case presented with bilateral inguinal lymphadenopathy, and one case with generalized lymphadenopathy. The presented study findings were comparable with those of Guru et al.^[2] which observed cervical lymphadenopathy 78.76% and axillary lymphadenopathy 21.23%.

HIV was found more prevalent among age group 21-30 years (44%) followed by 30-40 years (42%). Which is comparable with other authors like Shenoy et al.^[7] [44% between 25-30 years] and Vanishri et al.^[8] [44.4 % between 21-30 years of age group] (Table:1). In our study male (70%) patients are more prevalent than female patients (30%), which is comparable with Vanishri et al.^[8] with male predominant 72.22%, Shenoy et al.^[7] 5:1 and Guru et al.^[2] 2.3:1 for M:F ratio.

Among various cytological findings in our study, Tuberculous lymphadenopathy (56%) was most common cytology which was comparable with Shenoy et al.^[7] (50%) and Jayaram et al.^[9] (53.84%). Caseous tuberculous lymphadenitis was most common patterns of tuberculous lymphadenitis, where caseous necrosis was seen in 25 (78.57%) out of 28 cases. Tuberculous lymphadenitis was categorized into three patterns namely only caseous, caseous with epithelioid cell granuloma, only epithelioid granuloma without caseous necrosis. Among these caseous with epithelioid cell granuloma were the predominant finding in 21 (75%) followed by only caseous 4 (14%), 2 (7%) cases with only epithelioid cell granulomas.

These findings correlated with Vanishri et al.^[8] and Shenoy et al.^[7] In cases with both caseous necrosis and epithelioid cell granulomas, only 6 cases out of 21 cases showed AFB positive on ZN stain, in other cases diagnosis was given on the presence of caseous necrosis and epithelioid cells. Only caseous necrosis was seen in 4 out of 28 cases, out of these 3 cases showed AFB positive bacilli on ZN stain. 2 cases out of 28 cases showed only epithelioid cells granulomas with no caseous necrosis, but showed AFB positive bacilli on ZN stain. One case showed suppurative background with no caseous necrosis or epithelioid cells granulomas, this case showed strong positivity for AFB bacilli on ZN stain.

Reactive lymphadenitis was second most common finding 14 (28%) showing small lymphocytes, transforming lymphocytes, centrocytes, centroblasts, tingible body macrophages and few histiocytes.

The findings were consistent with Vanishri et al.^[8] [13 (36%)] and Shenoy et al.^[7] [17 (36%)].

Followed by granulomatous lymphadenitis 6 (12%) showing epithelioid cell granulomas, they were negative for caseous necrosis and AFB on ZN stain. These were categorized as non-specific granulomatous lymphadenitis. 7.3% (17) cases were nonspecific granulomatous lymphadenitis in study done by Guru et al.^[2] 4% (2) of cases showed features of dense acute inflammatory infiltrate with predominant neutrophils, few lymphocytes and necrotic debris in the background, these were negative for caseous necrosis, epithelioid granuloma, AFB on ZN stain. They were categorized as suppurative lymphadenitis. Shenoy et al.^[7] and Guru et al.^[2] had 2% and 1.3% suppurative lymphadenopathy in their study respectively. One case of Cryptococcal infection was encountered (2%), similar finding was made by Jayaram et al.^[9] and Guru et al.^[2]

The comparison of various other similar studies with the present study is shown in Table: 5 FNAC of lymph nodes in HIV/AIDS patients with clinical correlation can provide most useful information to physicians to determine the further mode of management. With today's increasing cost of medical practice, technique which speeds up the process of diagnosis is of great value.

ORIGINAL ARTICLE

AGE	POSITIVE
11 to 20 years	0
21 to 30 years	22(44%)
31 to 40 years	21(42%)
41 to 50 years	4(8%)
51 to 60 years	2(4%)
61 to 70 years	1(2%)

Table 1: Age Distribution of HIV Positive Cases

SITE	Present study(N-50)
Cervical	92%(46)
Axillary	4%(2)
Inguinal	2%(1)
Generalised	2%(1)

Table 2: Distribution of Lymphadenopathy in HIV Cases

DIAGNOSIS	NO. CASES
TB lymphadenitis	28(56%)
Granulomatous lymphadenitis	6(12%)
Reactive lymphadenitis	13(26%)
Acute suppurative lymphadenitis	2(4%)
Cryptococcus	1(2%)

Table 3: Distribution of cytological pattern in lymph-nodes in HIV positive cases(N-50)

Caseous with epithelioid granuloma	21(75%)
Only caseous	4(14%)
Only epithelioid granuloma	2(7%)
Suppurative	1(4%)

Table 4: Cytological pattern of Tuberculous Lymphadenitis (N=28)

Author	Bottles et al N=113 (1988). ⁽¹⁰⁾	Martin et al N=23 (1993). ⁽⁶⁾	Reid et al N=52 (1998). ⁽¹¹⁾	Jayaram et al N=39(2000) . ⁽⁹⁾	Shenoy et al N=48 (2001). ⁽⁷⁾	Vanishri et al N=34	Guru et al N=231 (2009). ⁽²⁾	Present study N=50
Reactive LN%	50	41	51	25.64	17	36.1	46.32	26
Mycobacterial TB%	17	22	15	53.84	50	58.3	41.55	56
Non-specific granuloma%	-	-	-	2.56	-	-	7.3	12
Suppurative%	-	-	-	-	2	-	1.29	4
Cryptococcus%	-	-	1.53	2.56	-	-	0.43	2
Others%*	33	37	32.47	15.4	31	5.6	3.11	-

Table 5: Comparison of Present Study with other studies

*= includes primary malignancy, secondary malignancy, other opportunistic infection

CONCLUSION: In our study conducted in rural area we observed that tuberculous lymphadenitis is the most common opportunistic infection in HIV positive cases followed by reactive lymphadenitis. Most of the individuals are male between 21-40 years of age. FNAC can be used as a great tool in early diagnosis of opportunistic infection and appropriate treatment.

REFERENCES:

1. Vinay kumar, Abul K. Abbas, Nelson Fausto, Jon C. Aster: Robbins and Cotran Pathological Basis of Disease, 8th Edition, Saunders, Indian reprint, New Delhi.
2. Kumarguru, M.H.Kulkarni, N.S.Kamakeri: FNAC of peripheral lymphnodes in HIV-positive patients; scientific medicine 2009; 1(2).
3. Global aids epidemic. UNAIDS report. 2012.
4. Time to act save a million lives by 2015. Geneva, Stop TB Partnership, Joint Untitled Nations Programme on HIV/AIDS, World Health Organization. 2011.
5. Global Tuberculosis Control, Geneva. WHO report 2011-[cited 2012 Dec 31]. Available from http://www.who.int/tb/publications/global_report/gtbr12_main.pdf.
6. Martin Bates E, Tanner A, Survana SK *et al*. Use of fine needle aspiration cytology for investigating lymphadenopathy in HIV Positive patients. J Clin Pathol 1993; 46(6): 564-6.
7. Shenoy R, Kapadi SN, Pai KP, Kini H, Mallya S, Khadilkar UN, *et al*: Fine needle aspiration diagnosis in HIV – related Lymphadenopathy in Mangalore, India. Acta Cytol. 2001; 46:35-39.
8. Vanisri H R, Nandini N M, Sunila R, Fine needle aspiration cytology finding in human immunodeficiency virus lymphadenopathy, IJPM -51(4), 2008:481-484.
9. Jayaram G, Chew MT: Fine needle aspiration cytology of lymph node in HIV – infected individual. Acta Cytol. 2000; 44:960-966.
10. Bottles K, McPhaul LW, Volberding P: Fine –needle aspiration biopsy of patients with acquired immuno deficiency syndrome (AIDS): Experience in an out-patient clinic. Ann Int Med 1988; 108:42-45.

ORIGINAL ARTICLE

11. Reid AJC, Miller RF, Kocjan GL: Diagnostic utility of Fine needle aspiration (FNA) cytology in HIV infected patients with lymphadenopathy. *Cytopathology*, 1998; 9:230-239.

FIGURE 1 & 1A-Shows Epithelioid cells with caseous material (100x); **1B-**Shows Epithelioid cells with lymphocytes (100x); **1C-**Shows Classical Langhan's Giant Cell with lymphocytes in background (1000x); **1D-**Shows ZN Stain with Acid fast bacilli (1000x).

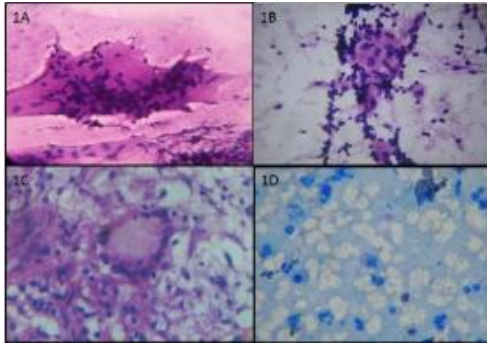


Fig: 1

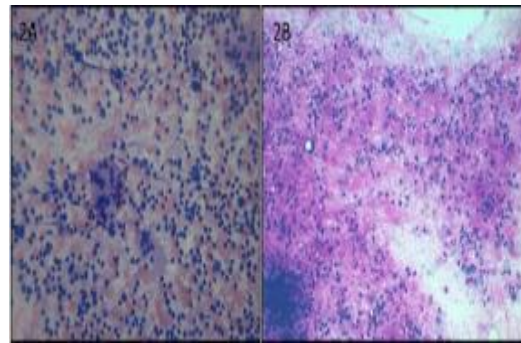


Fig: 2

AUTHORS:

1. Amrutha Gorva
2. Satyanarayana Veeragangham
3. V. G. Prasad

PARTICULARS OF CONTRIBUTORS:

1. Assistant Professor Department of Pathology, KAMS Hyderabad.
2. Professor & HOD, Department of Pathology, KIMS, Narketpally.
3. Professor, Community Medicine, Department of Pathology, KIMS, Narketpally.

FINANCIAL OR OTHER

COMPETING INTERESTS: None

NAME ADDRESS EMAIL ID OF THE CORRESPONDING AUTHOR:

Dr. Amurtha Gorva,
Dr. Amaresh
H. No-DIV/5, KIMS Staff Quatres,
Narketpally,
Nalgonda, Telengana.
E-mail: amugorva@gmail.com

Date of Submission: 19/09/2015.
Date of Peer Review: 21/09/2015.
Date of Acceptance: 05/10/2015.
Date of Publishing: 15/10/2015.