

ACUTE APPENDICITIS A CLINICO-RADIOLOGICAL STUDYGovind Trivedi¹, Rajeev Bhargava², Suruchi Richhariya³, Vertika Singh⁴**HOW TO CITE THIS ARTICLE:**

Govind Trivedi, Rajeev Bhargava, Suruchi Richhariya, Vertika Singh. "Acute Appendicitis A Clinico-Radiological Study". Journal of Evolution of Medical and Dental Sciences 2015; Vol. 4, Issue 67, August 20;

Page: 11708-11713, DOI: 10.14260/jemds/2015/1688

INTRODUCTION: Appendix Latin word means an addition or appendage was first identified as early as 3000 B.C. during the mummification process in Egypt. The prefix vermiform derived its name from its worm like appearance. Appendix was probably discovered by Celsus during dissecting criminals executed by Caesar and was first depicted in anatomic drawings in 1492 by Leonardo da Vinci.

The term Appendix vermiformis was coined by Philipe Verlyan in 1735. The term appendicitis was coined by Reginald Fitz in 1886, whereas Mc Burney in 1894 outlined grid iron incision and also named his point. In 1902 Oschner & Sherren suggested conservative regime to treat appendicular lump. During 1880 and 1903, Murphy introduced concept of internal appendectomies.

First Laparoscopic appendectomy was done by Kurt Karl Stephan Semm of Germany in 1983. Appendicitis still remains a difficult diagnosis despite the presence of several radiological diagnostic tools and clinical scoring system as many of the patient present with atypical findings. Prompt diagnosis is required to prevent negative appendectomies and ruptures.

Chan et al in 2003 reviewed that patients with low Alvarado score given in 1988 does not have appendicitis. Use of radiological tools in accurate diagnosis of appendicitis still remains a debatable topic. Ellis in recommended x-ray (plain) films to be useful in all cases of acute abdomen, where as Ohmann concluded that Alvarado scoring system ideal for diagnosis of acute appendicitis.

In a recent meta-analysis no single clinical finding was found to be effectively rule in or rule out acute appendicitis. Similar, was the case for various radiological diagnosis tools. Yang-et-al, Wu-et-al advocated the values of TLC to be an effective indicator in case of acute appendicitis.

Whereas, many other researchers have reported sensitivity of USG as 83% and specificity as 95%. Weltman-et al advocated use of thin sections CT for improving diagnosis. In most clinical trails CT appears superior to USG in evaluation of acute abdomen. Incesn et al in 2011 found MRI superior to sonography in revealing appendicitis.

Similarly, Ekeh etal concluded that laprascopic appendicectomy was associated with an increased rate of negative appendicectomy and have advocated open appendicectomies and clinical evaluation over radiological investigations.

Many researchers advocated use of MRI over other radiological tools (Ngyuyen 2013, Herliczek 2012) .But the concern that reliance on radiographic studies may distract from careful, timely history and physical examination and may not be cost-effective. The ultimate goal in treating suspected appendicitis is to minimize number of unnecessary lapratomies without increasing complicated appendices.

OBSERVATIONS: The present study has been conducted on 80 patients admitted in Surgery Department as a case of Appendicitis in Rama Hospital, Rama Medical College Kanpur during period from Jan 2013 to Nov- 2014.

The study included 80 patients in which 60 were males (75%) and 20 were females (25%). Male to Female ratio in the study was 3:1 and most of patients were in 11-40 yrs of age group. Study done by Lakhey Pale Swan at TUTH, Nepal showed male dominance as shown in our study. Similar

ORIGINAL ARTICLE

study was done by William NS, Bulsrode CJK; O'Connell PR showed that acute appendicitis was most common in age group of 21-30 year.

Pain in right lower abdomen was most consistent symptom. It was present in all patients. Pain migrating from peri-umbilical area to right lower quadrant was 2nd most common symptom followed by nausea, fever and vomiting. Tenderness at Mc Burney's point was the most common sign elicited (87.5%), psoas sign was least common (11.25%). Only 65% of patients presented with classical history and physical findings.

Young et al reported TLC and Neutrophil shift to left helpful markers in diagnosis of Acute Appendicitis. Similarly, Bener et al also found TLC count of more than 10, 000/cumm in 80-85% of Acute Appendicitis patients. De-Carvallo concluded that raised TLC is a sensitive test for diagnosis of Appendicitis but is less specific and so not diagnostic.

Chan incorporated Alvarado score in algorithm for patient admission for suspected acute appendicitis. In our study patients with Alvarado score of 5 or <5 had less appendicitis and hence negative appendicectomy rate was more while a score of 6 or >6 can be used as a criterion for suspected appendicitis and hence appendicectomy. Love et al observed -ve appendicectomy rate to be 17% and patients with Alvarado score 9-10, 6-8, <5 have a accuracy rate of 88%, 86%, 62% respectively.

In our study, total of 20 % -ve Appendicectomy was seen.

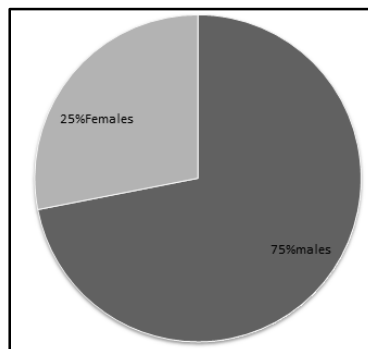
In this study nearly 82% patients were negative for appendicitis on abdominal Roentgenogram (X-Ray). Steven Lee found in his studies that Abdominal Roentgenogram is not useful in making diagnosis of Appendicitis. In contrast USG is a sensitive diagnostic test for suspected appendicitis and in our study sensitivity and sensitivity of USG was found to be 94.8% and 75% respectively. Ds Wade et al found over all accuracy of USG in diagnostic of Appendicitis was statistically superior to that by the Surgeon's clinical impression.

CECT Abdomen was done for highly suspicious patients in whom the clinical diagnosis was challenged by USG. In our study 25 patients underwent CECT Abdomen out of which 20 patients were positive for Appendicitis and 5 were negative. However negative CT patients were also negative on Histo-pathological examination of resected Appendix.

Ozkan etal 2014 reported CT was found to have higher specificity and sensitivity than Alvarado score and USG which are not sufficient on their own for taking the decision for surgery and CT scan has lower -ve lapraotomy rate when compared with other modalities.

OBSERVATIONS:

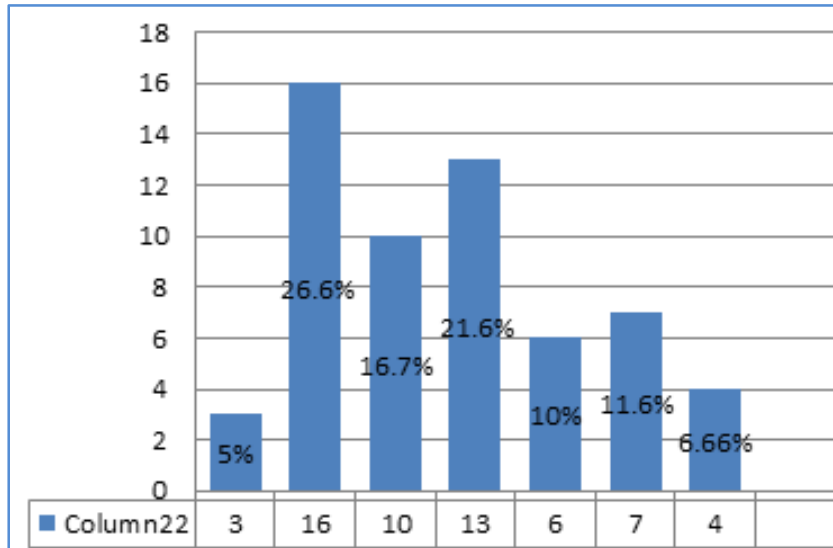
1. SEX INCIDENCE: Our study comprising 80 pt., 60 male (75%) and 20 females (25%). There was male preponderance over females.



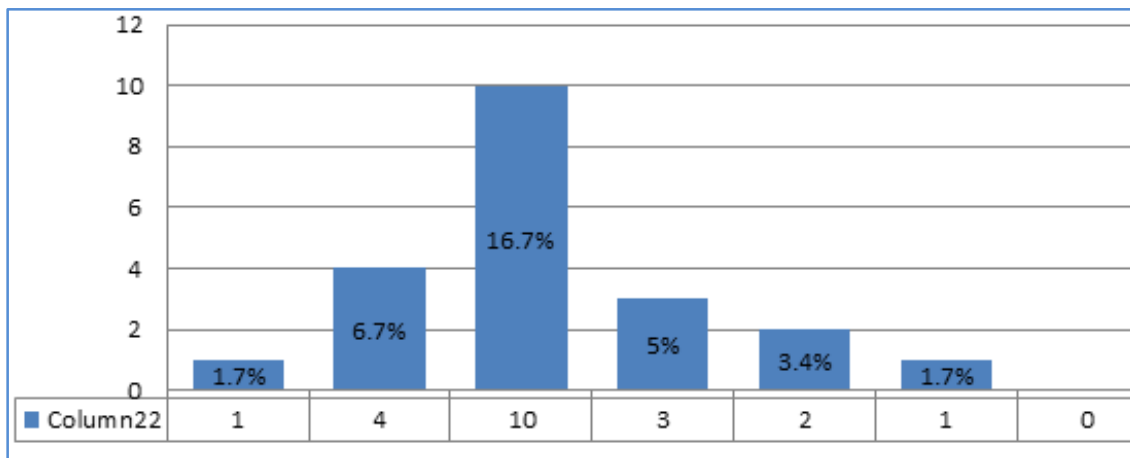
ORIGINAL ARTICLE

2. AGE DISTRIBUTION:

- a. **Age Distribution in Suspected Appendicitis in Males:** Max. no. of cases of appendicitis in males found in age group (11-20 yrs)-26.6% and most of cases were in age group (11-40yrs)-64.9% in children (0-10 yrs)-5% in old males (61-70yrs)-6.65%.



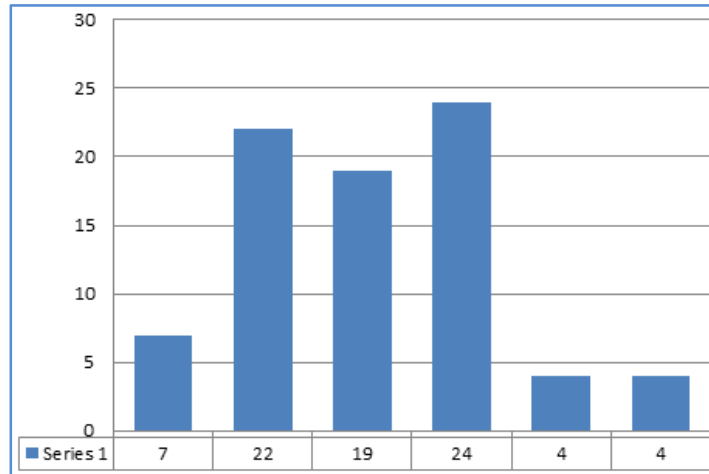
- b. **Age Distribution in Suspected Appendicitis in Females:** Max. no. of cases in females was found in age group of 21-30 yrs of age (16.7%) and most of cases were in age group 11-40 yrs (28.4%).



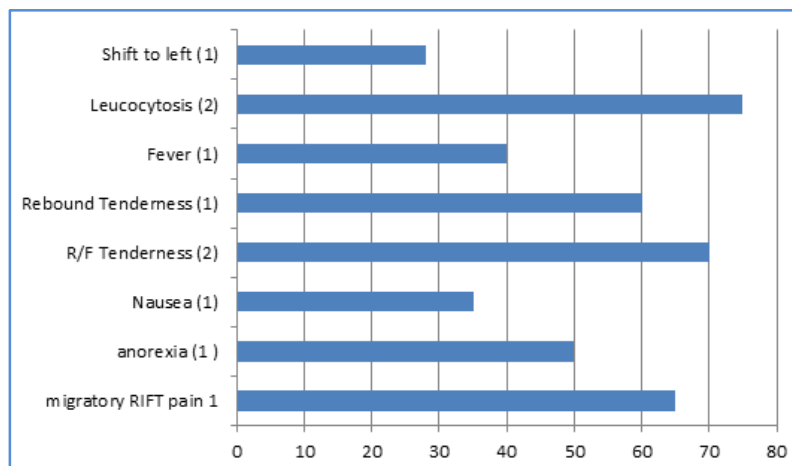
3. ALVARADO SCORE STATS:

- a. Rate of negative Appendicectomy in study was 20% males 16.6%, females 30% Alvarado score 5 or <5 in 7pt. having suspected appendicitis out of which 2(28.5%) were negative for appendicitis on HPE. Total 65 pt. having score 6-8 out of which 55 were positive for appendicitis on HPE. Total 8 pt. with score 9 – 10 out of which 7 were +ve for appendicitis on HPE (87.5%).

ORIGINAL ARTICLE

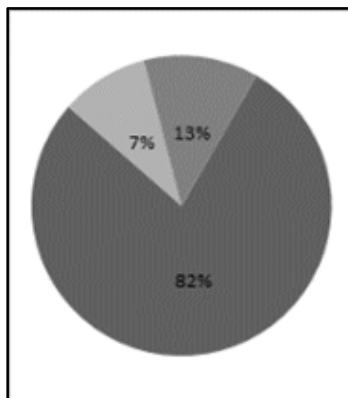


b. Parameter of Alvarado Score Showing no. of pt. Presented with following Parameters:



4. Radiological Parameters: Further for diagnosis pt. were investigated by radiological imaging technique like X – ray, USG abdomen and in some cases where USG reported negative or conclusive, CECT abdomen was done.

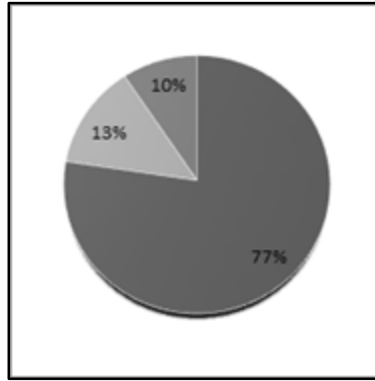
a. X-ray abdomen in case of suspected appendicitis in 80 pt:



ORIGINAL ARTICLE

5 pt. +ve for acute appendicitis -7%
 65 pt. +ve for acute appendicitis -82%
 10 pt. in conclusive-13 %

b. USG abdomen in cases of suspected appendicitis in 80 pt:



65 pt. +ve for acute appendicitis-78 %
 10 pt. -ve for acute appendicitis-13 %
 8 pt. in conclusive-10%

Among 62 pt. who were +ve for appendicitis by USG, 57 were +ve for appendicitis on HPE. Among 10 pt. who were -ve for appendicitis on HPE. Other 8 pt. were -ve for appendicitis on HPE.

c. CECT abdomen: Total 25 pt. out of 80 abdomen for suspected appendicitis under vent CECT abdomen 20 were +ve for appendicitis and 5 were -ve however -ve CT pt. were -ve in HPE also.

REFERENCES:

- Balthazar EJ, Birnbaum BA, Yee J, et al. Acute Appendicitis: CT and Ultrasound correlation in 100 patients. *Radiology*.1994;190:31-35.32.
- Garcia pena BM Mandl KD, Kraus SJ, et al; Ultrasonography and limited CT in the diagnosis and management of Appendicitis in children.*Paediatrics*.1999;104:440-446.35.
- Portman P, Oostvagel HJ, Bosma E, et al. Improving diagnosis of Acute Appendicitis. Results of a diagnostic pathway with standard use of ultrasonography followed by selective use of USG followed by selective use of CT.*J.AM.Coll.surg*.2009; 208(3).
- Gaitini D, Beck-Razi N, Mor. Yosef D, et al. Diagnosing Acute Appendicitis in Adults. Accuracy of Color Doppler Sonography and MDCT compared with surgery and clinical follow up. *Am. J. Roentgenol*. 2008 190(5).
- Effectiveness of Sonography versus CT.*AJR Am. J. Roentgenol* 1997;169:113-8.
- Brown MA. Imaging acute appendicitis. *Semin. USG, CT, MR*.2008; 29: 293-307.
- Wade DS, Marrow SE, Balsara ZN, etal. Accuracy of Ultrasonography in the diagnosis of Acute Appendicitis compared with the surgeon's clinical impression. *Arch Surg*.1993;128:1039-1044.

ORIGINAL ARTICLE

8. Ozkan S, Duman A, Durukan P. Accuracy of Alvarado score, Ultrasonography and CT in the diagnosis of Acute Appendicitis. Niger J. Clin Pract (serial online) 2014 {cited 2015 Aug 19} 17;413-8
9. Chan MY, Teo BS, NG BL. The Alvarado score and Acute Appendicitis .Ann Acad Med Singapore.2001;30Cs:510-512
10. Paleswan JL, Comparative Study of Ultrasonography and Alvarado score in diagnosis of Acute Appendicitis. Dec 2000.Kathmandu University Medical Journal.

AUTHORS:

1. Govind Trivedi
2. Rajeev Bhargava
3. Suruchi Richhariya
4. Vertika Singh

PARTICULARS OF CONTRIBUTORS:

1. Assistant Professor, Department of General Surgery, Rama Medical College Hospital and Research Centre, Kanpur.
2. Professor, Department of General Surgery, Department of General Surgery, Rama Medical College Hospital and Research Centre, Kanpur.
3. Intern, Department of General Surgery, Department of General Surgery, Rama Medical College Hospital and Research Centre, Kanpur.

FINANCIAL OR OTHER

COMPETING INTERESTS: None

4. Intern, Department of General Surgery, Department of General Surgery, Rama Medical College Hospital and Research Centre, Kanpur.

NAME ADDRESS EMAIL ID OF THE CORRESPONDING AUTHOR:

Dr. Govind Trivedi,
Flat No. 206-A, Shiva Apartment,
Sarvoday Nagar, Kanpur.
E-mail: govind_trivedi03@yahoo.co.uk

Date of Submission: 14/07/2015.
Date of Peer Review: 15/07/2015.
Date of Acceptance: 12/08/2015.
Date of Publishing: 19/08/2015.