

PROGNOSTIC VALUE OF OCT IN MACULAR HOLE SURGERYJignesh Gosai¹, Tanuj Limbasiya², Bhagyashree Natu³, Uvesh Mansuri⁴**HOW TO CITE THIS ARTICLE:**

Jignesh Gosai, Tanuj Limbasiya, Bhagyashree natu, Uvesh Mansuri. "Prognostic Value of Oct in Macular hole Surgery". Journal of Evolution of Medical and Dental Sciences 2014; Vol. 3, Issue 66, December 01; Page: 14352-1435261, DOI: 10.14260/jemds/2014/3925

ABSTRACT: PURPOSE: To pre-operatively stage macular hole based on OCT and to calculate Macular Hole Index and Hole Form Factor. To determine post-operative visual outcome and macular hole closure. **METHODS:** Prospectively reviewed 25 eyes of Macular Hole. All the patients with complain of diminution of vision and defective central field of vision were examined. Before and after surgery complete clinical examination and OCT was performed which included macular hole diameter at the level of RPE(base diameter) and at the minimal extent of hole(minimum diameter),Vertical Height, Horizontal Diameter, Left Arm Length, Right Arm Length ,Macular Hole Index and Hole Form Factor. 21 Gauge Pars Plana Vitrectomy with ILM peeling was performed in all patients. **RESULTS:** 25 eyes of 25 consecutive patients were studied. There were 14 (56%) men and 11(44%) women, with an average age of 60 years (50 to 75 years, median 60 years) Mean follow up time was 1 month. At 3 months 6 of 25 patients (24%) attained a visual acuity greater than or equal to 6/36. Patients of macular hole were found to be most in idiopathic (18/25, 72%) in nature .On OCT most of the macular hole in stage 3 and stage 4 were associated with subretinal fluid, epiretinal membrane.12% patients had Grade II,40% had Grade III, 48% had Grade IV Macular Hole.Negative co-relation was found between both the base and minimum diameterand post-operative visual acuity. Post-operative outcome is better in pateints with MHI >0.5, HFF>0.9.

KEYWORDS : Macular hole, optical coherence tomography, predictive factors

INTRODUCTION: Macular hole is a full thickness depletion of neural retinal tissue in the centre of macula. Prevalence rate of macular hole in India is a reported 0.17%,with a mean age of 67 years.⁽¹⁾ It has been reported that idiopathic macular holes (IMHs) may be formed from the tangential traction of the acellular prefoveal vitreous and possibly by a contraction of the cellular constituents in the prefoveal vitreous. Earlier investigators suggested that the macular hole may enlarge by the contractile forces generated by glial cells that migrate onto the inner surface of the internal limiting membrane (ILM).⁽²⁾ Since then, the removal of the ILM during macular hole surgery has been widely advocated and excellent anatomical success rates have been reported.⁽³⁻⁶⁾ Optical coherence tomography (OCT) is a non-invasive, non-contact imaging system which provides high resolution cross-sectional images of the retina, vitreous and optic nerve head. Imaging of the anterior segment (AS-OCT) is also possible using the same technique although at present modified apparatus must be employed. OCT has helped to establish the role of anteroposterior^(7,8) and tangential force caused by contraction of the internal limiting membrane (ILM) in MH development, although the exact pathogenesis has not been determined.⁽⁹⁾ Several authors have described different methods of macular hole measurement using OCT scans, including minimum linear dimension (MLD),⁽¹⁰⁾ hole form factor (HFF),⁽¹¹⁾ macular hole index (MHI),⁽¹²⁾ diameter hole index (DHI)and tractional hole index (THI).⁽¹³⁾ The aim of this study is to preoperatively stage macular hole, calculate of Macular Hole Index (MHI) and Hole Form Factor (HFF) based on OCT and also to determine post-operative visual outcome and macular hole closure based on OCT.

ORIGINAL ARTICLE

MATERIAL AND METHODS: A prospective study of 25 patients of macular at M & J institute of ophthalmology, Civil hospital, Ahmedabad in between June 2011 to November 2013, were included and patients with macular degeneration were excluded.

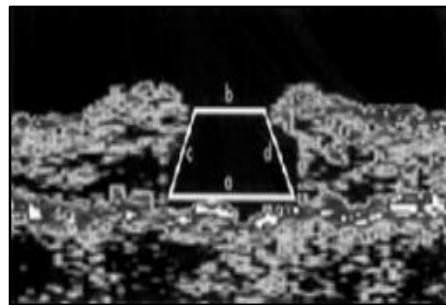
Patients complaining of diminution of vision and black spot in the field of vision were examined as follows.

History evaluation, Vision with/without glasses, Torch light Examination, Slit lamp Examination, IOP by NCT, Slit lamp biomicroscopy, Direct ophthalmoscopic examination, Indirect ophthalmic examination, Optical coherence tomography(OCT).

From these examination a macular hole stage II, III, and IV according to the classification by Gass⁽¹⁴⁾ were examined with optical coherence tomography (OCT) before pars plana vitrectomy. Macular hole diameters were determined at the level of the retinal pigment epithelium (base diameter) and at the minimal extent of the hole (minimum diameter). Calculated hole form factor (HFF) was correlated with the postoperative anatomical success rate and best corrected visual acuity.

OCT PREDICTIVE FACTORS FOR MACULAR HOLE SURGERY:

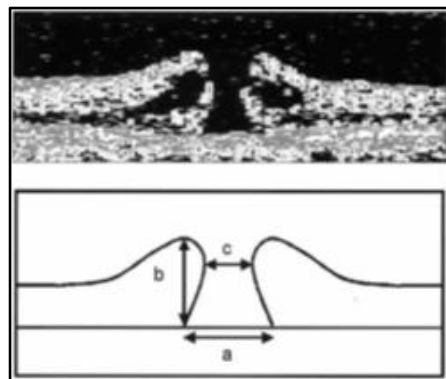
- HFF (Hole Form Factor):** Hole form factor (HFF) = $c + d/a$.



- a = base diameter
- b = minimum diameter
- c = left arm length
- d = right arm length.

- MHI (Macular hole Index):** MHI = b/a

- b = vertical height
- a = maximum base diameter



ORIGINAL ARTICLE

INDICATIONS OF SURGERY:

- Stage 2 MH with VA < 6/12.
- Stage 3 or 4 MH.

Written and informed consent for all the patients was taken according to The Geneva Declaration. Surgery consisted of standard three port pars plana vitrectomy, peeling of the epiretinal membranes if present and the inner limiting membrane with subsequent instillation of a gas tamponade (C₃F₈). No substances such as indocyanine green (ICG) or growth factors such as transforming growth factor β (TGF- β) were used. After surgery patients were asked to maintain a prone position for at least 5 days. Postoperative anatomical success was defined as flattening of the hole with no subretinal fluid.

TYPES OF CLOSURE:

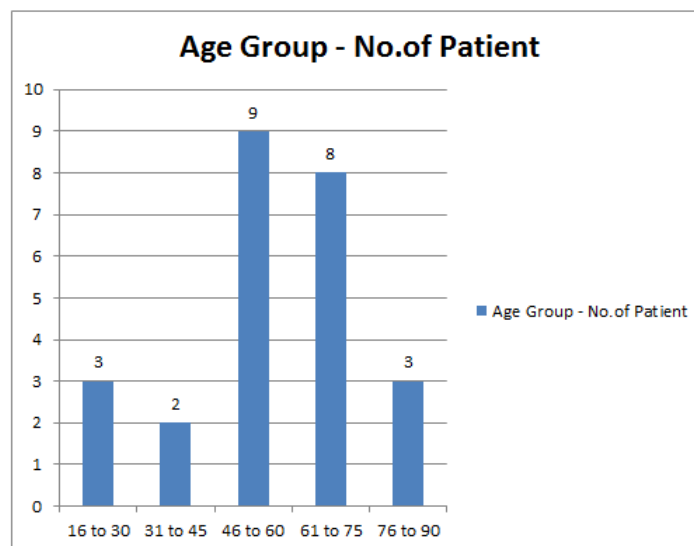
Type 1: closure indicates that the macular hole is closed without foveal defect of the neurosensory retina.

Type 2: closure indicates that a foveal defect of the neurosensory retina persists postoperatively although the whole rim of the macular hole is attached to the underlying RPE with flattening of the cuff.

DATA ANALYSIS AND OBSERVATION: Prospective study of surgical outcome of 25 patients of Macular hole based on OCT was carried out at M & J Western Regional Institute of Ophthalmology, Civil Hospital, Ahmedabad in between June 2011 to November 2013.

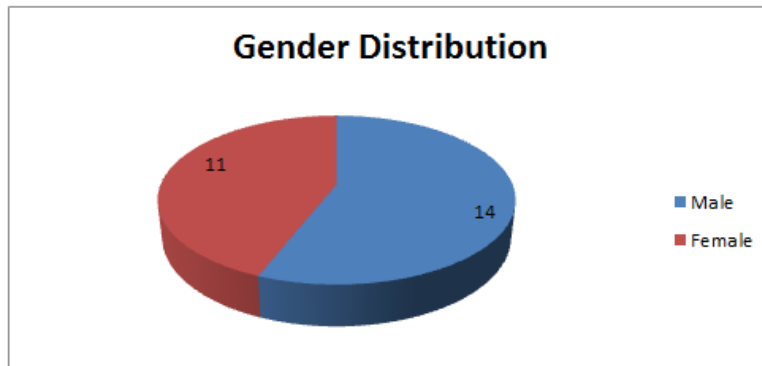
DEMOGRAPHIC RESULT:

1. **Age:** Out of 25 patients 9 patients in between age group of 46 to 60 yrs (36%), and 8 patients in between age group of 61 to 75 (32%) were found and rest of age group have been displayed in chart given below.

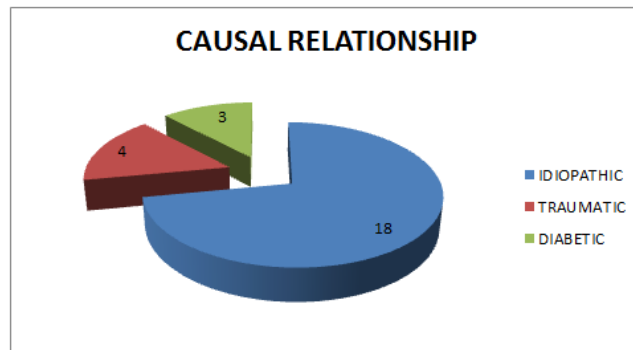


ORIGINAL ARTICLE

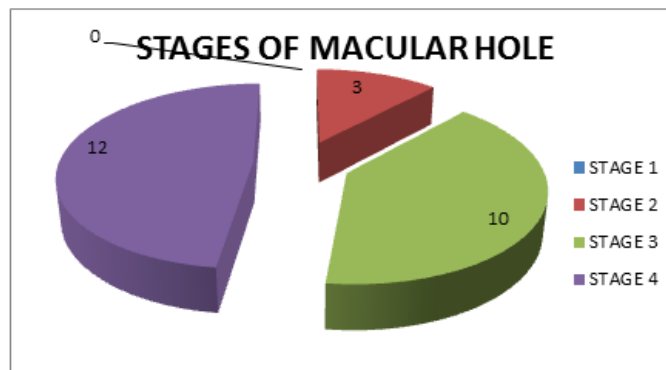
2. **Gender:** 14 patients of males (56%) and 11 patients of females (44%) were observed.



3. **Causal Relationship:** 18 patients of macular hole in idiopathic nature (72%) were found to be most, whereas 4 patients of traumatic origin (16%) and 3 patients of diabetes (12%) were found.

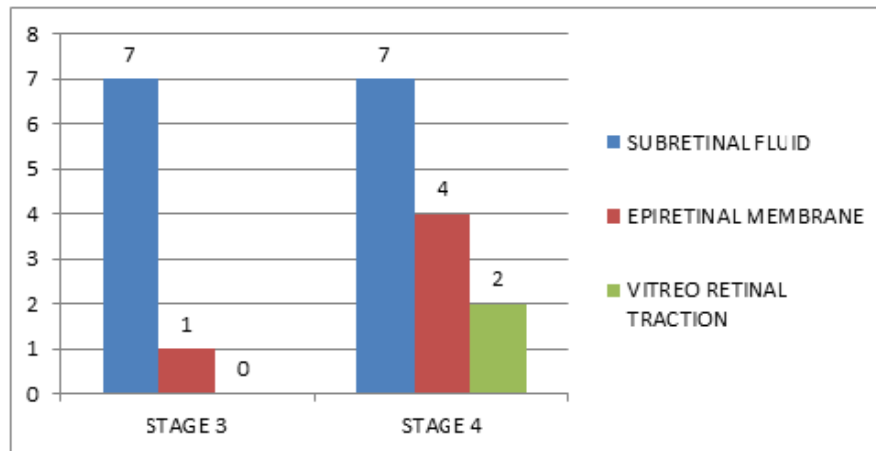


4. **Stages of Macular hole:** based on Indirect ophthalmoscopy and OCT. Macular hole has been divided in four stages 1a, 1b, 2, 3, 4. In our study, 12 patients with stage 4 macular hole (48%) were more in number and 10 patients of stage 3 (40%) and 3 patients stage 2 (3/25,12%) were found.



Subretinal fluid, epiretinal membrane and vitreo retinal traction were found in stage 3, stage 4 macular hole as per statistics given below,

ORIGINAL ARTICLE



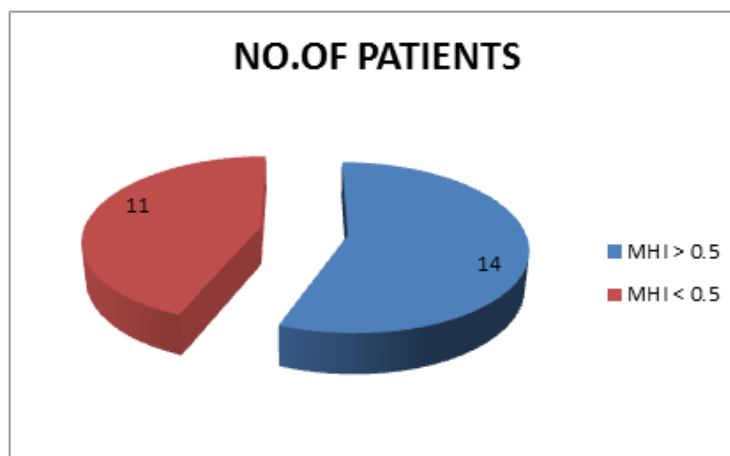
OCT PREDICTIVE FACTORS FOR MACULAR HOLE SURGERY:

Macular Hole Index: MHI has been calculated from VH and HD.

$MHI = VH / HD$.

In various study, if $MHI > 0.5$, chances of macular hole closure would be more.

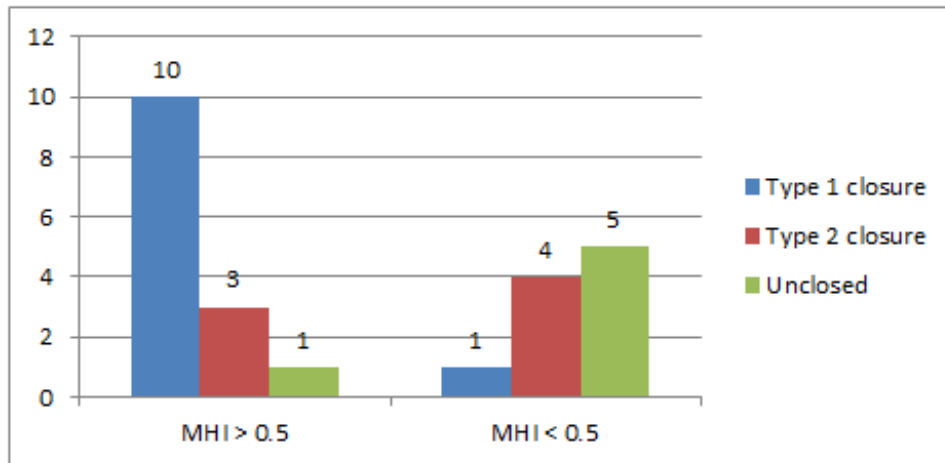
In our study, 14 patients with $MHI > 0.5$ (56%) were found. Out of them, macular hole were set up to be sealed in 10 patients (71%).



Type 1 closure in 10 patients with MHI of more than 0.5(71%) and in 1 patient with MHI of less than 0.5(10%) were observed.

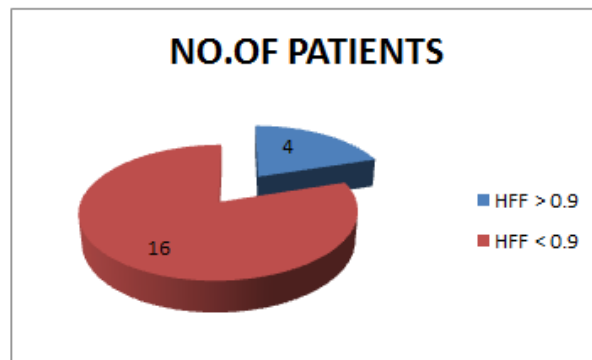
In relation with MHI, types of macular hole closure have been outlined below,

ORIGINAL ARTICLE

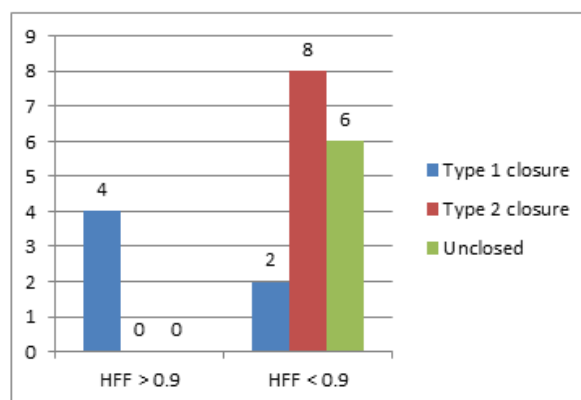


Hole Form Factor (HFF) can be calculated by using RAL, LAL, HD. = (RAL + LAL)/HD.

In studies, if HFF is > 0.9, chances of macular hole sealing would be more. In our study, from 20 patients in those HFF calculation was possible. So 4 patients with HFF > 0.9 and 16 patients with HFF < 0.9 were found. Type 1 closure in 4 patients (100%) with HFF of more than 0.9 and type 1 closure in 2 patients (12.5%) in HFF of less than 0.9 were analyzed.



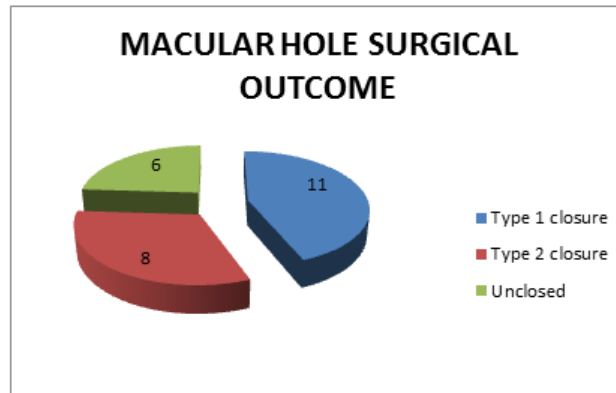
Types of closure of macular hole in relation with HFF have been charted below,



ORIGINAL ARTICLE

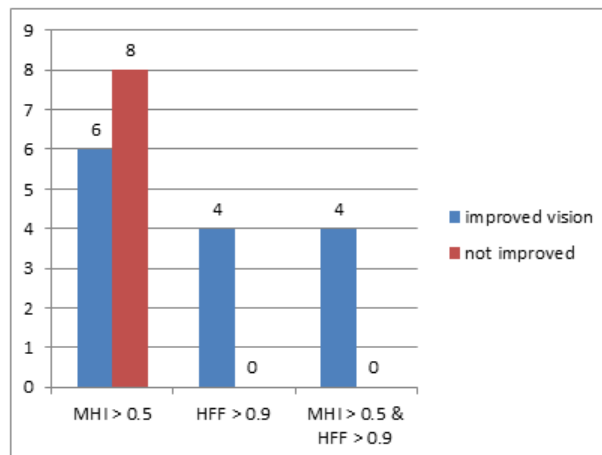
In our study, also 2 patients (10%) with re-detachment after macular hole surgery were found. In these patients surgery was done with injection of intra vitreally C3F8.

Macular hole surgery was performed on 25 patients and out of them, Type 1 closure in 11 patients (44%), Type 2 closure in 8 patients (32%), were found and 6 patients were remain unclosed (24%).



In our study, MHI of more than 0.5 in 14 patients (56%) and HFF of more than 0.9 in 4 patients (16%) were found. Type 1 closure was present in 10 patients (10/14, 71%) with MHI of more than 0.5, out of which 6 patients (6/14, 42.8%) had improved visual acuity. Type 1 closure was present in 4 patients with HFF of more than 0.9 and all of them (4/4, 100%) had improved visual acuity.

Correlation in between postoperative visual acuity and OCT predictive factors for macular hole surgery (MHI, HFF) has been graphed below,



DISCUSSION: The aim of this study was to evaluate the role of a preoperative optical coherence tomography (OCT) measurement in diagnosing and staging of macular holes and its predictive value for the anatomical and functional outcome after macular hole surgery.

The diameter of the macular hole measured by OCT at the level of the retinal pigment epithelium and the minimum diameter seem to provide a prognostic factor for postoperative visual outcome and anatomical success of macular hole surgery. The base diameter, which can only be

ORIGINAL ARTICLE

measured by OCT, as it reflects the real size of the retinal lesion. Similar results have been published by Freeman and coworkers, who found that a macular hole with a small diameter was associated with better functional outcome⁽¹⁵⁾ The reason for this might be that a small hole diameter indicates a better preserved macula.

A macular hole stage I, II, III, and IV according to the classification by Gass were examined with optical coherence tomography (OCT) before pars plana vitrectomy. Macular hole diameters were determined at the level of the retinal pigment epithelium (base diameter) and at the minimal extent of the hole (minimum diameter). Calculated hole form factor (HFF) was correlated with the postoperative anatomical success rate and best corrected visual acuity.

We calculated the hole form factor (HFF), originally created by Puliafito. He considered the ratio between the overlying tissue dimensions and the hole base diameter to be of greater influence on the anatomical success rate than the base diameter alone. Puliafito found an 80% anatomical success rate in patients with HFF greater than 0.9 and an anatomical success rate of less than 25% in patients with HFF under 0.5.^(16,17) The association between HFF and anatomical success rate was found to be statistically significant. With respect to the correlation coefficient, r , the minimum diameter measured with OCT seemed to be a better predictor than the HFF.

In our study all patients with an HFF greater than 0.9 were operated on successfully in the first surgical approach and the anatomical success rate was 12.5% in patients with HFF under 0.5. Type 1 closure was present in 4 patients with HFF of more than 0.9 and all of them had improved visual acuity.

Besides same anatomical results compared to those of Puliafito and colleagues, we also found a significant correlation between HFF and anatomical success rate. A possible explanation for the higher success rate in our patients compared with those of Puliafito et al might be that eventual existing epiretinal membranes including the inner limiting membrane were removed during surgery in our series.

Prediction of postoperative visual outcome based on hole configuration by, optical coherence tomography in eyes with idiopathic macular Holes⁽¹⁸⁾: This study was performed in Japan and it shows retinal thickness values in the inner ring area were decreased at the 1-month postoperative period. MHI significantly correlated with the postoperative decrease in macular thickness in the inner ring area at 6 months (Correlation coefficient = -0.632, $P = .030$, Spearman analysis) and with the postoperative BCVA ($P = .013$, multiple regression analysis). Postoperative BCVA in the MHI ≥ 0.5 group was better than that in the MHI < 0.5 group ($P = .032$, Mann-Whitney test).

In our study MH thickness was decreased in 10 patients (71%) with MHI of more than 0.5 and out of them 6 patients (6/14, 42.8%) had improved vision. So it has been postulated that MHI has significant value in MH surgery.

RESULTS: A total of 25 eyes of 25 consecutive patients with macular holes were included in the study. There were 14 (56%) men and 11(44%) women, with an average age of 60 years (50 to 75 years, median 60 years). The postoperative follow up ranged from 1 week to 3 months. Mean follow up time was 1 month. At this time 6 patients were pseudophakic and 19 were phakic. 2 patients with their crystalline lens revealed lens opacities which clinically interfered with visual acuity. At 3 months 6 of 25 patients (24%) attained a visual acuity greater than or equal to 6/36. Furthermore, no

ORIGINAL ARTICLE

changes being suggestive for phototoxicity were noted postoperatively. There were two cases of postoperative macular detachment found.

By using OCT the macular hole was staged grade II in 04 eyes (3/25, 12%), grade III in 10 eyes (10/25, 40%), and grade IV in 12 eyes (12/25, 48%).

Patients of macular hole were found to be most in idiopathic (18/25, 72%) in nature. On OCT most of the macular hole in stage 3 and stage 4 were associated with subretinal fluid, epiretinal membrane.

A significant negative correlation between both the base and the minimum diameter of the hole and postoperative visual acuity was found. The better postoperative visual outcome was positively correlated with a higher HFF value.

In this study, MHI of more than 0.5 in 14 patients and HFF of more than 0.9 in 4 patients were found. Type 1 closure was present in 10 patients (10/14, 71%) with MHI of more than 0.5, out of which 6 patients (6/14, 42.8%) had improved visual acuity.

14 eyes without anatomical closure after the first surgical procedure (14/25, 56%) the base diameter of the hole was significantly larger than in cases with immediate closure.

In all patients with HFF >0.9 (4/4, 100%) the macular hole was closed following one surgical approach whereas in eyes with HFF ≤0.9 anatomical success rate after one operation was only 12.5% (2/16).

CONCLUSION: Post-operative outcome can be predicted from optical coherence tomography by measuring MHI and HFF. Post-operative outcome would be better in patients with MHI of more than 0.5 and HFF of more than 0.9.

REFERENCES:

1. Sen P, Bhargava A, Vijaya L, George R. Prevalence of idiopathic macular hole in adult rural and urban south Indian population. *Clin Experiment Ophthalmol* 2008; 36: 257–60.
2. Yoon H, Brooks HL, Capone A Jr, et al. Ultrastructural features of tissue removed during idiopathic macular hole surgery. *Am J Ophthalmol* 1996; 122: 67–75.
3. Park DW, Sipperley JO, Sneed SR, et al. Macular hole surgery with internal-limiting membrane peeling and intravitreal air. *Ophthalmology* 1999; 106: 1392–7 (discussion 1397–8).
4. Brooks HL. Macular hole surgery with and without internal limiting membrane peeling. *Ophthalmology* 2000; 107: 1939–49.
5. Mester V, Kuhn F. Internal limiting membrane removal in the management of the full-thickness macular holes. *Am J Ophthalmol* 2000; 129: 769–77.
6. Kwok AK, Li WW, Pang CP, et al. Indocyanine green staining and removal of internal limiting membrane in macula hole surgery: histology and outcome. *Am J Ophthalmol* 2001; 132: 178–83.
7. Gaudric A, Hauchine B, Massin P, et al. Macular hole formation: new data provided by optical coherence tomography. *Arch Ophthalmol* 1999; 117: 744–51.
8. Haouchine B, Massin P, Gaudric A. Foveal pseudocyst as the first step in macular hole formation: a prospective study by optical coherence tomography. *Ophthalmology* 2001; 108: 15–22.
9. Niwa H, Terasaki H, Ito Y, et al. Macular hole development in fellow eyes of patients with unilateral macula hole. *Am J Ophthalmol* 2005; 140: 370–5.

ORIGINAL ARTICLE

10. Ip MS, Baker BJ, Duker JS, et al. Anatomical outcomes of surgery for idiopathic macular hole as determined by optical coherence tomography. *Arch Ophthalmol* 2002; 120: 29e35.
11. Ullrich S, Haritoglou C, Gass C, et al. Macular hole size as a prognostic factor in macular hole surgery. *Br J Ophthalmol* 2002; 86: 390e3.
12. Kusuhara S, Teraoka Escan˜o MF, Fujii S, et al. Prediction of postoperative visual outcome based on hole configuration by optical coherence tomography in eyes with idiopathic macular holes. *Am J Ophthalmol* 2004; 138: 709e16.
13. Ruiz-Moreno JM, Staicu C, Pin˜ero DP, et al. Optical coherence tomography predictive factors for macular hole surgery outcome. *Br J Ophthalmol* 2008; 92: 640e4.
14. Gass JD: Reappraisal of biomicroscopic classification of stages of development of a macular hole. *Am J Ophthalmol* 119: 752-759, 1995
15. Freeman WR, Azen SP, Kim JW, et al. Bailey I for the vitrectomy for treatment of macular hole study group. Vitrectomy for the treatment of full-thickness stage 3 or 4 macular holes. *Arch Ophthalmol* 1997; 115: 11-21.
16. Hee MR, Puliafito CA, Carlton W, et al. Optical coherence tomography of macular holes. *Ophthalmology* 1995;102:748-56.
17. Desai VN, Hee MR, Puliafito CA. Optical coherence tomography of macular holes. In: Madreperla SA, McCuen BW, eds. *Macular hole: pathogenesis, diagnosis and treatment*. Oxford: Butterworth-Heinemann 1999: 37-47.
18. *Am J Ophthalmology* 2004 Nov; 138 (5): 709-16

AUTHORS:

1. Jignesh Gosai
2. Tanuj Limbasiya
3. Bhagyashree Natu
4. Uvesh Mansuri

PARTICULARS OF CONTRIBUTORS:

1. Assistant Professor, Department of Ophthalmology, M. & J. Institute of Ophthalmology.
2. 3rd Year Resident, Department of Ophthalmology, M. & J. Institute of Ophthalmology.
3. 3rd Year Resident, Department of Ophthalmology, M. & J. Institute of Ophthalmology.

4. 4th Year Resident, Department of Ophthalmology, M. & J. Institute of Ophthalmology.

NAME ADDRESS EMAIL ID OF THE CORRESPONDING AUTHOR:

Dr. Jignesh Gosai,
T4/103, Devnandan Heights,
Opp. Avkar Villa,
New Cg Road,
Chandkheda, Ahmedabad-382424.
Email: dr_jigneshgosai@hotmail.com

Date of Submission: 28/10/2014.
Date of Peer Review: 29/10/2014.
Date of Acceptance: 25/11/2014.
Date of Publishing: 29/11/2014.