

A STUDY ON THORACIC VERTEBRAL SYNOSTOSIS & ITS CLINICAL IMPORTANCEMd. Khaleel Ahmed¹, Taqdees Fatima², Priyanka M³**HOW TO CITE THIS ARTICLE:**

Md. Khaleel Ahmed, Taqdees Fatima, Priyanka M. "A Study on Thoracic Vertebral Synostosis & its Clinical Importance". Journal of Evolution of Medical and Dental Sciences 2015; Vol. 4, Issue 02, January 05; Page: 156-159, DOI: 10.14260/jemds/2015/26

ABSTRACT: Vertebral anomalies are of interest not only to anatomist, but also to orthopedician, neurologist & neurosurgeons. Various vertebral anomalies of anatomic interest have been reported namely; occipitalisation, sacralisation, lumbarisation, absence of posterior elements of vertebral arch & vertebral synostosis. The fusion of vertebral column is rare anomalies usually congenital in origin. The fusion of thoracic vertebrae can present many clinical sign including congenital scoliosis. A study on 594 dry adult human vertebrae of unknown age & sex collected from the department of anatomy and phase I students of KBNIMS, Kalaburagi, Karnataka. The study was done over a period of 6 months (July to December 2014) during routine osteology classes for 1 year MBBS, we found the fusion of typical thoracic vertebrae between T₃ & T₄. The cause could be failure of re-segmentation of somitomeres or acquired.

KEYWORDS: Fused vertebrae, congenital scoliosis, vertebral anomalies.

INTRODUCTION: Vertebral anomalies are of interest not only to anatomist, but also to Orthopedician, neurologist & neurosurgeons. Various vertebral anomalies of anatomic interest have been reported namely; Occipitalisation, Sacralisation, Lumbarisation, absence of posterior elements of vertebral arch & vertebral synostosis.¹The vertebral column is derived from the sclerotomes of somites.²The fusion of two or more vertebrae is a congenital anomaly of vertebral column may occur in the cervical, thoracic & lumbar.³It is one among the chief manifestation of body segmentation or metamerism. The fusion of two or more vertebrae may occur in the cervical region (Klippel-Feil's syndrome), atlas to the occipital bone (Occipitalisation), fifth lumbar to the sacrum (Sacralisation of fifth lumbar vertebrae) in the thoracic region.⁴Fusion of vertebrae & intervertebral disc between them.⁵The prevalence of vertebrae synostosis in Lithuanian population is 2.6% of cervical vertebral fusion, 1.6% of thoracic vertebral fusion & 0.5% of lumbar vertebral fusion.⁶The fusion of thoracic vertebrae is the rare among the three types. The surgical fusion two vertebrae are known as spondylodesis or spondylosyndesis. Acquired fusion can be due to disease like tuberculosis, juvenile rheumatoid arthritis & trauma.⁷

MATERIALS AND METHOD: A study on 594 dry adult human vertebrae of unknown age & sex collected from the department of anatomy and phase I students of KBNIMS, Kalaburagi, Karnataka. The study was done over a period of 6 months (July to December 2014). All the vertebrae were examined carefully for any variations by visual inspection. Appropriate measurements were taken and specimen was photographed. The embryological and clinical importance due to variations are discussed. The broken, neonatal or non-dried specimens were excluded from the study.

OBSERVATIONS: In present study, a fusion of typical thoracic vertebra between T₃&T₄ of unknown sex was found and symmetric fusion of vertebra near the junction of fusion of both lamina and

ORIGINAL ARTICLE

spinous processes, there is a groove with over hanged linear crest on both sides, which demarcates the fusion of both the bodies of thoracic vertebrae. As a result of fusion, there is absence of superior facet of lower vertebra and inferior facet of upper vertebra. The costal facets are seen on either side of the body near its junctions. The inter-vertebral foramen is persisting, though size is reduced. The size of the body of lower vertebra is increased compared to other. Transverse process of lower vertebra is larger comparatively.

TABLE: Showing dimensions of fused typical thoracic vertebrae (in centimeters)

Parts of vertebra	view	Upper vertebra	Lower vertebra
Body	Antero-posterior	1.4cm	1.7cm
	transverse	2.6cm	2.9cm
Spinal canal	Antero-posterior	1.3cm	1.2cm
	transverse	1.6cm	1.6cm
Vertebral foramen	On right side	0.7cm	
	On left side	0.8cm	
Fused lamina	2.1cm		

Table 1

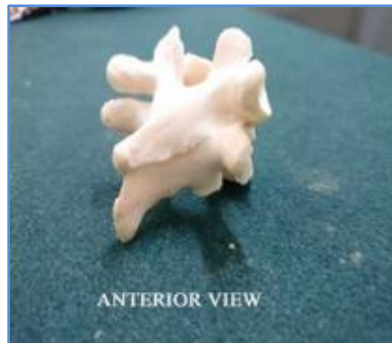

Figure 1

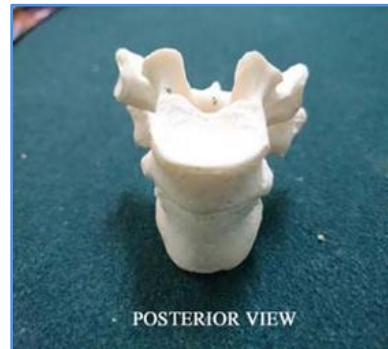


Figure 2

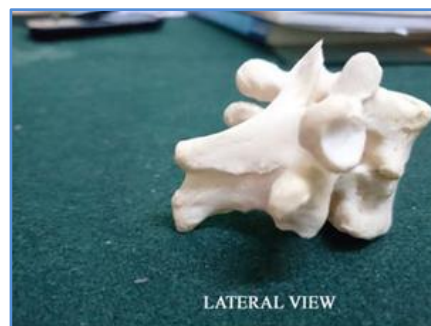


Figure 3

ORIGINAL ARTICLE

DISCUSSION: The vertebral column develops from paired somites, each composed of a dermatome, myotome and sclerotome. They arise initially in cervical region (4th week), increasing in number cranio-caudally. In the 5th week, the sclerotomic cells of the somites lose their adherence and migrate to the vertebral centrum, neural processes and costal processes. Each thoracic neural process gives rise to a cartilaginous pedicle, transverse process and lamina. The ossification Centre arises, one for the centrum and one for the neural process. Their timing is idiosyncratic, starting in the 4th month at T₁₀ & L₁ (centra) and C₂ and T₁ (neural process) and spreading up and down the column.⁸

Radiologically, three types of vertebral fusion have been described single fused cervical segment seen in 25% of patients, multiple contiguous fused segments seen in 25% patients and multiple non-contiguous fused seen in 50% patients.⁹

The segmentation of the vertebra occurs at the time of organogenesis. The non-segmentation of the primitive sclerotome is the cause of the fused vertebra or block vertebra. The embryological time period for the occurrence of synostosis can be analyzed from the anatomical features. In this case, transverse process are not fused, it indicates that the initially development was normal.

CLINICAL IMPORTANCE: Anatomically, the intervertebral discs form a fifth of the post axial vertebral column.¹¹ The absence of intervertebral disc therefore leads to shortening of the column and thereby shortening of the trunk. The thoracic vertebrae and the intervening disc along with the ribs help to maintain the shape and length of the thorax. Fusion of the vertebrae and the absence of the disc will narrow the thorax and can lead to respiratory distress. Asphyxiating thoracic dystrophy is caused by narrow thorax and short ribs.¹²

Apart from the developmental anomalies the vertebral fusion can be associated with radiculopathy and myelopathy. The other associated complications mentioned are:

- Neural axis-diastematomyelia, tethered cord, Arnold- Chiari malformation
- Renal-unilateral horse-shoe kidney, duplicated kidney or ureters, hypospadias.
- Congenital heart disease.
- Musculoskeletal-club feet, Sprengel's deformity, Klippel-Feil syndrome, dysplasia of hip, scoliosis.
- Jaw and external deformities, cleft palate, cervical rib.

CONCLUSION: Fusion of the vertebra can be congenital or acquired. Embryologically, failure of resegmentation of the vertebra is the cause. Knowledge about any deviation from the normal anatomy of vertebral column can lead to wide complications affecting different system of the body.

REFERENCES:

1. Thomas D, Kulkarni BG. A case of fusion of thoracic vertebra. *Journal of Ayurveda and Holistic Medicine*. 2013; 1 (5): 23-2.
2. Singh I, Pal GP. *Human Embryology*. 8th ed. India: Mac Millan Publishers Limited; 2007: 116.
3. Seaver LH, Boyd E. Spondylocarpotarsal synostosis syndrome and cervical instability. *PubMed Am J Med Genet* 2000; 91 (5): 340-4.
4. Singh I, Pal GP. *Human Embryology*. 8th ed. India: Mac Millan Publishers Limited; 2007: 119.
5. Datta AK. *Essentials of Human Embryology*. 6th ed. Kolkata: Current Books International; 2010: 278.

ORIGINAL ARTICLE

6. Masnicova S, Benus R. Developmental anomalies in skeletal remains from the Great Moravia and Middle Ages cemeteries at Devin. *International journal of osteoarchaeology*. 2003; 13: 266-74.
7. Erdil H, Yildiz N, Cimen M. Congenital fusion of cervical vertebrae and its clinical significance. *Journal of Anatomical Society of India* 2003; 52 (2): 125-7.
8. Brookes M, Zietman A. *Clinical Embryology*. USA: Library of Congress; 1998: 293.
9. Jin-Kyu Park, Han – Young Huh, Kyeong-Sik Ryu and Chun-Kun Park. Traumatic Hemiparesis associated with Type III Klippel Feil syndrome. *Journal of Korean Neurosurgical Society*. 2007; 42: 145-8.
10. Vasudha K, Ramesh BR. A spectrum of Vertebral Synostosis. *International Journal of Basic and Applied Medical Sciences*. 2012; 2 (2): 71-7.
11. Bhargava S. *Radiological Differential Diagnosis*. 1sted. New Delhi: Jaypee Brothers; 2005: 528.
12. Sameer B, Sashin A. *Congenital Scoliosis: Management and future directions*. *Actaorthopeda Belgica* 2008; 74: 147-60.

AUTHORS:

1. Md. Khaleel Ahmed
2. Taqdees Fatima
3. Priyanka M.

PARTICULARS OF CONTRIBUTORS:

1. Assistant Professor, Department of Anatomy, KBNIMS, Kalaburagi, Karnataka.
2. Assistant Professor, Department of Anatomy, KBNIMS, Kalaburagi, Karnataka.
3. Assistant Professor, Department of Anatomy, KBNIMS, Kalaburagi, Karnataka.

NAME ADDRESS EMAIL ID OF THE CORRESPONDING AUTHOR:

Dr. Md. Khaleel Ahmed,
Department of Anatomy,
KBNIMS, Roza Buzurg,
Kalaburagi-585104,
Karnataka.
E-mail: dr.mohammedkhaleel786@gmail.com

Date of Submission: 19/12/2014.
Date of Peer Review: 20/12/2014.
Date of Acceptance: 24/12/2014.
Date of Publishing: 02/01/2015.