

# REVIEW ARTICLE

## STURGE-WEBER SYNDROME: REVIEW OF LITERATURE

Mamatha P<sup>1</sup>, N. Mariappan<sup>2</sup>, Khushbu Tanitia<sup>3</sup>, D. R. Shekar<sup>4</sup>

### HOW TO CITE THIS ARTICLE:

Mamatha P, N. Mariappan, Khushbu Tanitia, D. R. Shekar. "Sturge-Weber Syndrome- Review of Literature". *Journal of Evolution of Medical and Dental Sciences* 2015; Vol. 4, Issue 80, October 05; Page: 14086-14093, DOI: 10.14260/jemds/2015/2002

**ABSTRACT:** The Sturge-Weber syndrome is a sporadic congenital neurocutaneous disorder with port-wine stain affecting the facial skin in the distribution of the ophthalmic branch of the trigeminal nerve, abnormal capillary venous vessels in the leptomeninges of the brain and choroid resulting in glaucoma, seizures, stroke and intellectual disability.<sup>[1]</sup> Sturge-Weber syndrome and port-wine stains are believed to be caused by Somatic Mutation in GNAQ.<sup>[2]</sup> We present a case of 18 years old patient of SWS for its rarity of occurrence and the difficulties posed in the management of this condition. The aim of this article is to stress the importance of this condition that may be overlooked in the diagnosis.

**KEYWORDS:** Angioma, Port-wine stain, Sturge-Weber syndrome, Epilepsy, Glaucoma, Facial asymmetry.

**INTRODUCTION:** Sturge-Weber syndrome was first described by Schirmer in 1860 and later more specifically by Sturge in 1879. He described the association of the dermatological and ophthalmic changes of the disease to neurological manifestations. Kalischer in 1897 demonstrated the cerebral involvement. Weber in 1929 documented the radiological alterations.<sup>[3]</sup> It is important to note that NOT all individuals with port-wine stain have SWS. Sturge-Weber Syndrome is the only phakomatosis that is NOT associated with intracranial neoplasms. (Di Rocco and Tamburrini, 2006). "Phakos" (Gr.) = birth mark, spot mole. Phakomatosis may be defined as syndromes produced by mutations in tumor suppressor genes. This neurocutaneous syndrome is due to vascular malformations resulting from the failure of the fetal veins to develop normally in the brain, skin and eyes.

### Phakomatoses Consists Of:

- Tuberous sclerosis: AD, mutation on chromosome 16p13.3, 12q14,9q34.
- Neurofibromatosis type-1: AD, mutation on chromosome 17q11.2.
- Neurofibromatosis type- 2: AD, mutation on chromosome 22q12.2.
- Von-Hippel-Lindau: AD, mutation on chromosome 3p26-p25.
- Ataxia-Telangiectasia: AR, mutation on chromosome 11q22.3.

### Synonyms of Sturge Weber Syndrome:

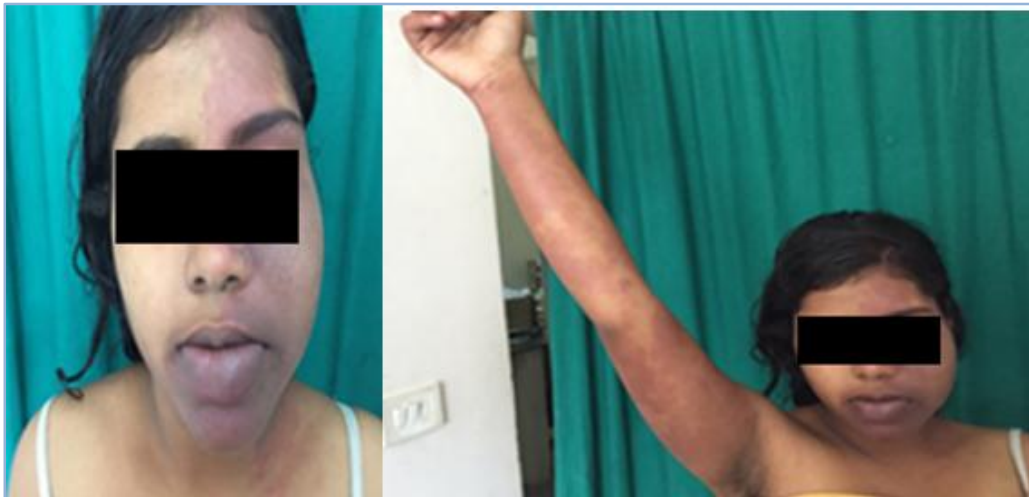- Dimitri Disease.
- Encephalofacial Angiomatosis.
- Encephalotrigeminal Angiomatosis.
- Leptomeningeal Angiomatosis.
- Sturge-Kalischer-Weber Syndrome.
- Sturge-Weber-Krabbe Syndrome.
- Sturge-Weber Phakomatosis.
- Sturge-Weber Syndrome (SWS).

## REVIEW ARTICLE

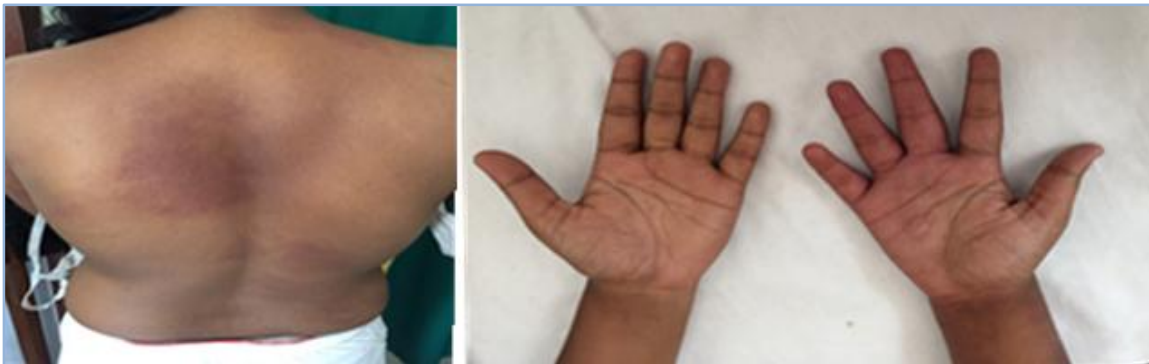### The Classic Symptoms of Encephalotrigeminal Angiomatosis are:

- Capillary-venous malformation (Leptomeningeal angiomatosis).
- Facial port-wine stain (PWS or Nevus Flammeus) in trigeminal V1-V3 distribution.
- Congenital Glaucoma.
- Intractable epilepsy and
- Progressive mental retardation.

Case Report: A female patient aged 18 years old presented with a facial angioma localised in the Trigeminal nerve region on the left side of the face present since the age of 4 years. She had angiomas in the face, upper and lower limbs and the back.



**Fig. 1: The patient has facial angiomas and facial asymmetry**



**Fig. 2: The patient has angioma of both upper and lower limbs and back Asymmetry of development of upper limbs and hand is seen**

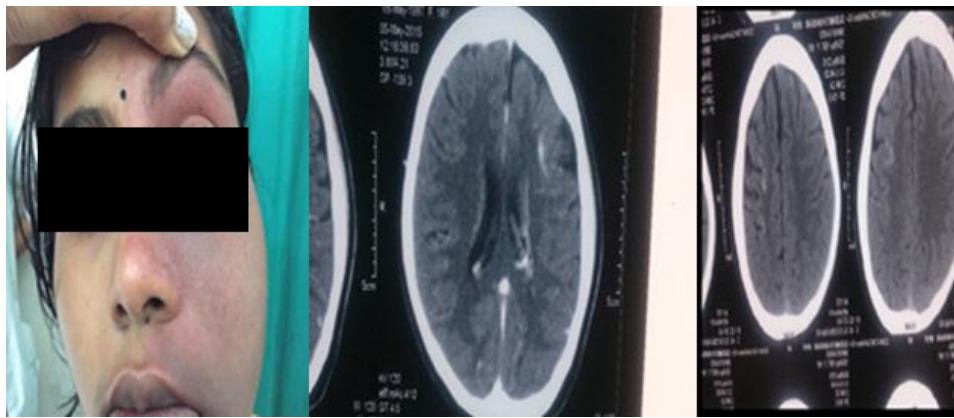
There was facial asymmetry and disparity in the growth of the upper limbs and hand development. She has generalised tonic-clonic seizures since the age of 12 years. The epilepsy is becoming more intractable and difficult to manage. The patient is on antiepileptic treatment with Levetiracetam 1000mg/day, Valproic Acid 1500mg/day and Clonazepam 2mg/day. Neurologist's

## REVIEW ARTICLE

opinion was sought for management of her condition. EEG performed on this patient did not reveal any discharges. The patient obtained opinion from the Dermatology department for Laser treatment for her facial angioma. The patient also had dental abnormalities associated with gingivitis for which she was referred to the Dental surgeon. The patient had glaucoma of the left eye was on treatment from the Ophthalmologist.

### CT Scan Showed:

- Left fronto-temporal leptomenigeal angioma.
- With cortical calcification and
- Atrophy of the left cerebral hemisphere features suggestive of Sturge-Weber neurocutaneous syndrome.



**Fig. 3: The patient has glaucoma of the left eye. \CT showed left fronto-temporal leptomenigeal angioma with cortical calcification And atrophy of the left cerebral hemisphere**

**Epidemiology:** A port-wine stain is a cutaneous capillary malformation that occurs in approximately 3 of every 1000 newborns and usually involves the head and neck regions.

Sturge-Weber syndrome is also known as encephalofacial angiomatosis

- Rare (Estimated 1/50 000 live births)
- Sporadic
- Equal in male and female
- No racial bias

A child born with a port-wine stain on the face has 6% chance of having the Sturge-weber Syndrome and this risk increases to 26% when the port-wine stain is in the distribution of the Ophthalmic branch of the Trigeminal nerve. Port-wine stains usually have underlying soft tissue and bony-tissue overgrowth which may be mild to massive.

**Classification of Sturge-weber syndrome:** SWS is referred to as complete when both CNS and facial angiomas are present. They are termed as incomplete when only one area is affected without the other.

## REVIEW ARTICLE

---

The Roach Scale is used for classification, as follows.<sup>[4]</sup>

SWS type	Clinical features
1. (Classic)	Facial and intracranial manifestations: Glaucoma is present
2.	Facial lesion only (Primarily dermatological)
3.	Isolated leptomeningeal angioma (Intracranial manifestations without facial lesions): No Glaucoma

(Tortori\_-Donati et al, 2005)

### **SWS: Pathogenesis**

Angiomas of Sturge-Weber syndrome develop from localized PRIMARY VENOUS DYSPLASIA, unrelated to any trigeminal nerve dysfunction. During development at 4-5 weeks gestation, a primordial sinusoidal VASCULAR PLEXUS forms around the cephalic portion of the neural tube and under the ectoderm that later becomes the facial skin.

This vascular plexus regresses at 9 weeks of gestation (Tortori- Donati et al, 2005)

In SWS, the cortical bridging veins fail to form, the vascular plexus persists, and the remaining veins become engorged with redirected blood flow. Cerebral veins are Emissary Veins which lack valves and they allow for BIDIRECTIONAL flow.<sup>[5]</sup>

**Neurological Deterioration:** Normal brain development and Seizures increase the oxygen and glucose demand of the brain tissue and leads to increased cerebral blood flow. These changes exacerbate the pre-existing venous engorgement and further elevate the venous pressures and subsequent hypoperfusion of the underlying cortex causing chronic cerebral ischaemia, atrophy and neurological deterioration. This results in severe cerebral ischemia and tissue damage.

### **Differential Diagnosis of Intracranial calcifications:**

- Sturge-Weber syndrome.
- Arteriovenous malformation.
- Hemangiomas.
- Choroid plexus.
- Craniopharyngioma.
- Glioma.
- Tuberculosis.
- Idiopathic.

(Reeder, 2003)

Calcifications develop over time, usually beginning at greater than 2years and remain stationary after second decade of life. These calcifications are gyriform and curvilinear and most commonly seen in parietal and occipital lobes.

### **Diagnosis:**

- An infant or child with PWS with associated neurological complications and the MRI which shows leptomeningeal angiomatosis and other cortical abnormalities are diagnostic of SWS.

## REVIEW ARTICLE

---

- When MRI is unavailable CT of the brain will demonstrate the the linear, parallel configuration of brain calcification (“Tram sign”).

**‘Tram-tracking’** in SWS is due to Gyriiform cortical calcifications is due to:

- Altered vessel wall permeability.
- Dystrophic calcification.

**Brushfield and Wyatt stated that these tram-line calcifications are pathognomonic of SWS.**

- Nuclear imaging

**Positron Emission Tomography:**

- F-18-FDG (Fluorodeoxyglucose) - Determines the brain tissue metabolism.

Used for prognostic evaluation and to aid surgical planning. The extent and severity of FDG hypometabolism correlates with seizure severity and cognitive decline (Lee et al, 2001).

**CLINICAL FEATURES:**

**CUTANEOUS MANIFESTATIONS:** The most evident clinical manifestation is the presence of nevus flammeus or port-wine stains on the face within the distribution of the Trigeminal nerve especially the ophthalmic division they are present at birth and range from small red macules to large red patches which blanch on pressure They occur commonly on the right side and do not extend over midline.

They can be bilateral or completely absent or may extend to neck, limb or other parts of the body. The classical form of SWS has port-wine stains along the ophthalmic branch distribution.

**LEPTOMENINGEAL MANIFESTATIONS:** The leptomeningeal angiomas is most often ipsilateral to the facial nevus. The occipital and parietal lobes are most commonly involved but anterior parts of the brain may also be involved. Histopathology reveals large tortuous venous structures in the thickened and discoloured leptomeninges. The underlying cortex is atrophied and calcified deposits are noticed. Vascular Steal Phenomenon plays an important roll in causing cerebral ischaemia and its consequences.

**Oral manifestations:** In Sturge-Weber syndrome patient’s oral manifestations occur in 38% of the patients. They have hemangiomas lesions in the lip, gingiva, tongue and palate. They are usually unilateral and stop abruptly at midline

**The Common Oral Manifestations are:**

- Port-wine stain of the oral mucosa with hypervascular changes.
- Angiomatous lesion of the Gingiva.
- Macroglossia.
- Maxillary bone hyperplasia with malocclusion and facial asymmetry.
- Gingival hyperplasia due to anticonvulsant therapy.
- Poor oral hygiene.

**Ocular Features:** Glaucoma affects two-thirds of Sturge-Weber syndrome patients, two-thirds of whom are diagnosed before the age of two to two decades in those with port wine stain in the dermatomes of the first and second division of the Trigeminal nerve Bupthalmos seen in upto 50% of newborns with SWS The risk of glaucoma is highest in the First two years of age.

## REVIEW ARTICLE

---

Klippel-Trenaunay syndrome shares the same pathophysiology as SWS, but affects veins elsewhere in the body where more prominent lymphatic effects are noted.

**Neurological Involvement:** The presence of leptomeningeal angiomas involving the pia mater is noted. 74% to 90% of the patients have epileptic crisis. Patients with late onset of epilepsy have lesser probability of developing neuropsychomotor retardation. About 80% of affected persons have focal seizures involving the contralateral side of the contralateral stain.<sup>[6]</sup>

### **Complications associated with Sturge -Weber Syndrome:**

1. **Seizures and convulsions:** Occur in 72% - 80% of SWS patients with lesions on one side of the brain and in 93% of patients with bilateral lesions. Seizures can begin anytime from birth to adulthood with 75% of patients having epilepsy within first year of life, 86% by age 2 and 95% before age 5.
2. **Port-wine Birthmark:** A person born with a PWB has 8%- 15% chance of having SWS. The risk of SWS increases to 25% in patients with a birthmark covering half of the face.
3. **Glaucoma:** 50% of patients with SWS will develop glaucoma if the birthmark involves the Trigeminal area of the eye.
4. **Migraine and Headaches:** 44% to 62% of patients suffer from migraines and headaches.
5. **Developmental Delays:** 50% - 75% of patients will show developmental Delays.
6. **Mood and behavior problems:** in 85% of those with seizures and 58% without.
7. **Paralysis:** 25% - 56% of SWS patients have weakness or paralysis of the opposite side of the portwine stain.
8. **Forme Fruste:** Type 3 SWS has vascular malformations of the brain, with no facial birthmark or Glaucoma.
9. **Hormonal Abnormalities:** Risk of hypothalamic-pituitary dysfunction is increased in patients with SWS.

### **Prevention and Treatment:**

#### **No preventive measures are known:**

- Port wine stain may be camouflaged by make up or treated with Laser surgery and cryotherapy.
- Anticonvulsant Therapy:
- Removal of large part of brain (Hemispherectomy) is very rarely done for intractable epilepsy.
- Hemiparesis and hemiatrophy need regular physiotherapy, Splinting and Braces.
- Management of headache, Depression and emotional problems.
- Glaucoma: Treated with eye drops, pills, Laser Surgery, eye surgeries or a combination of methods.

#### **Emergency situations:**

- Status epilepticus-Seizures lasting more than 10 minutes.
- Injury- bruising, concussion, fractures or even drowning, if seizures occur during bath
- Trouble breathing.<sup>[7]</sup>

**Prognostic Factors:** Prognosis depends mainly on the extent of the leptomeningeal angiomatosis. The presence or absence of seizures and the age of onset of seizures are the most important prognostic

## REVIEW ARTICLE

---

indicators. Of children who do not have epilepsy before the age of two, only 14% developed epilepsy later on. Children with late onset of epilepsy had lesser risk for development of developmental delay and the need for special education. Around 60% of children with SWS required special education. This risk increases to 83% if the seizures started before one year of age. Only 6% of children without epilepsy had developmental delay and with only 11% required special education.

**DISCUSSION:** This condition is a rare, genetic-related disease, due to mutations in the genes responsible for the regulation of the structure and function of blood vessels, innervation of blood vessels, and expression of extracellular matrix and vasoactive molecules. Only two mutations were noted one in chromosome 4q and another in trisomy. The treatment and prognosis of SWS depends upon the nature and severity of the clinical features. The facial lesions causes deep psychological trauma to the patients which affects the personality of the patients. Port-wine stains can be improved by treatment with flash lamp pulsed dye lasers, dermabrasion and tattooing.

Gingival overgrowth is managed by scrupulous oral hygiene and in extreme cases may even need gingivectomy.

Glaucoma can be treated with beta-blockers and carbonic anhydrase inhibitors. This treatment combined with surgical cryo-coagulation is effective. Patients need regular ophthalmologic surveillance till adulthood. Glaucoma could develop as late as in the 4<sup>th</sup> decade.

Epilepsy is the most common and the first neurological complication of SWS. About two-thirds of the patients have seizures that are resistant to anti-epileptic treatment. Only 10% of patients with SWS could be weaned off medication after being seizure-free. For children with drug-resistant seizures, epilepsy surgery must be considered before cognitive impairment sets in.

**CONCLUSIONS:** This case report is presented for its rarity and for the fact it may be easily overlooked in the diagnosis of the condition. The treatment of this condition is difficult and patients suffer from intractable epilepsy and have mental retardation. The treatment is often lifelong and frustrating for both the patient and the treating Physician. With better understanding of the genetic basis of this condition we can hope to have a better insight of the disease in future.

### REFERENCES:

1. Royle HE, Lapp R, Ferrara ED. The Sturge Weber Syndrome. *Oral Surgery, Oral Medicine, Oral Pathology* 1966; 22(4):490-7.
2. *N Engl J Med.* 2013 May 23; 368(21):1971-1979. doi:10.1056/NEJMoa1213507.
3. Neto FXP, Junior MAV, Ximenes LS, de Souza Jacob CC, Junior AGR, Palheta ACP. Clinical Features of Sturge-Weber Syndrome. *Intl Arch Otorhinolaryngol* 2008; 12(4):565-70.
4. Roach E.S. Neurocutaneous syndromes. *pediatr clin North Am.* 1992; 39:591-620.
5. Takeoka M, Riviello JJ. Sturge Weber Syndrome. Available From: <http://emedicine.com>.
6. Sujansky and Conradi, "Outcome of Sturge-Weber Syndrome in 52 Adults" *American journal of Medical Genetics* 57:33-45(1995).
7. Pascaul Casroviejo I, Diaz Gonzalez C, Garcia Melian RM. Sturge Weber Syndrome: Study of 40 patients. *Pediatr Neurol* 1993 Jul-Aug; 9(4):283-88.

## REVIEW ARTICLE

### AUTHORS:

1. Mamatha P.
2. N. Mariappan
3. Khushbu Tanitia
4. D. R. Shekar

### PARTICULARS OF CONTRIBUTORS:

1. Assistant Professor, Department of Dermatology, Vydehi Institute of Medical Sciences and Research Centre, Bengaluru.
2. Associate Professor, Department of Plastic Surgery, Vydehi Institute of Medical Sciences and Research Centre, Bengaluru.
3. Post Graduate, Department of Dermatology, Vydehi Institute of Medical Sciences and Research Centre, Bengaluru.

### FINANCIAL OR OTHER

**COMPETING INTERESTS:** None

4. Professor and HOD, Department of Plastic Surgery, Vydehi Institute of Medical Sciences and Research Centre, Bengaluru.

### NAME ADDRESS EMAIL ID OF THE CORRESPONDING AUTHOR:

Dr. Mariappan,  
B-311, Rsum Palms, Sy. No. 42, 7<sup>th</sup> Cross,  
1<sup>st</sup> Main Road,  
Ramagondanahalli to Borewell Road,  
Whitefield, Bengaluru-560066.

E-mail: drn\_m@hotmail.com

mariappannatarajan@gmail.com

Date of Submission: 28/08/2015.

Date of Peer Review: 29/08/2015.

Date of Acceptance: 24/09/2015.

Date of Publishing: 05/10/2015.