

## ROLE OF B-SCAN ULTRASONOGRAPHY IN CATARACT PATIENTS IN A TERTIARY CARE CENTRE

Vepa Meenakshi<sup>1</sup>, Tammana Jyothirmayi<sup>2</sup>, Bharani Sree<sup>3</sup>

### HOW TO CITE THIS ARTICLE:

Vepa Meenakshi, Tammana Jyothirmayi, Bharani Sree. "Role of B-Scan Ultrasonography in Cataract Patients in a Tertiary Care Centre." *Journal of Evolution of Medical and Dental Sciences* 2015; Vol. 4, Issue 83, October 15; Page: 14525-14530, DOI: 10.14260/jemds/2015/2066

**ABSTRACT:** **AIM:** To study the role of B-SCAN as a diagnostic tool in preoperative evaluation of posterior segment in mature cataract patients posted for surgery. **MATERIALS & METHODS:** B-SCAN ultrasonography was performed using a standard USG machine (sonomed B5500) equipped with a real-time high-frequency probe with the contact method in 490 eyes of 475 patients with mature cataract who came for cataract surgery to R.S.P.R Govt. Regional Eye hospital Visakhapatnam, Andhrapradesh from surrounding villages and tribal areas between December 2014 to March 2015. Detailed history and the basic examination with Slit lamp biomicroscopy, Tonometry, A-Scan biometry etc were done in all the patients and any H/O trauma, Hypertension, Diabetes etc. were noted and the results were analyzed. **RESULTS:** Out of 490 eyes of 475 patients 54 [11.02%] patients were found to be having some posterior segment pathology diagnosed by B-SCAN. Out of the 54 positive cases 15 cases were seen in patients with history of Trauma. In 15 cases bilateral mature cataracts were noticed. Out of the Positive cases RD was noticed in 14 cases [2.85%], Vitreous haemorrhage was noticed in 10 cases [2.09%], PVD was noticed in 6 cases [1.22%], Posterior staphyloma was noticed in 4 cases [0.8%], Asteroid Hyalosis was noticed in 4 cases [0.8%], Vitreous opacities were noticed in 8 cases [1.6%], Difference in the axial length of eye ball was noticed 6 cases [1.22%], and coloboma choroid was noticed in 1 patient [0.2%] and IOFB in 1 patient [0.2%]. **CONCLUSION:** B-Scan ultrasonography is useful in evaluating the posterior segment lesions in mature cataract patients and helpful in assessing the prognosis where the media haziness do not permit the evaluation of posterior segment.

**KEYWORDS:** B-Scan, Ultrasonography, posterior segment evaluation, cataract

**INTRODUCTION:** Ultrasound is an acoustic wave that consists of an oscillation of particles within a medium. The history of 'ultrasound diagnosis' in medicine is relatively short, dating back to the end of second world war. Ultrasound was first used in ophthalmology in 1956 by the American ophthalmologists, Mundt and Hughes.<sup>1</sup> They used A-scan mode to evaluate an intraocular tumor. B-scan was introduced in ophthalmic practice by Baum and Greenwood in 1958.<sup>2</sup> Later it was Bronson and Turner produced the first contact B-scan method, that ultrasonography became a more practical investigation. Orbital ultrasonography is a non-invasive, efficient, reliable and inexpensive diagnostic technique for evaluation of orbital pathology. Both A-scan and B-scan techniques are important for the diagnosis of posterior segment lesion. B (Brightness) mode is useful for a better demonstration of the shape and topographic relationship of lesions in the posterior segment.<sup>3</sup> B-scan provides cross sectional display of diseased tissues and is valuable in detecting unsuspected posterior segment diseases.<sup>4</sup> The frequency used in the diagnostic ophthalmic ultrasound for posterior segment is 8–10 Mhz. Over the last 30 years ultrasonography has greatly advanced and this has enabled us to study posterior segment of the eye in the presence of opaque media.<sup>5</sup> Its most common use is in a contact mode for evaluation of the posterior segment in eyes with media opacification,<sup>6</sup> and provides a

## ORIGINAL ARTICLE

method of assessing the structural changes in the posterior segment of the eye in such patients.<sup>7,8</sup>. The purpose of the study is to visualize the status of posterior segment of eye with the diagnostic tool of B-scan ultrasound and to find out any posterior segment lesions are present in mature and hyper mature cataracts where fundus cannot be evaluated with other means.

**MATERIALS AND METHODS:** The study was conducted in patients with mature cataracts where the posterior segment evaluation could not be done by routine methods. Diagnostic B-Scan Ultrasonography was performed in these patients preoperatively. The study was conducted from December 2014 to March 2015 in R.S.P.R Government Regional eye Hospital, Visakhapatnam, Andhra Pradesh. 1666 patients were operated for cataract surgery between December 2014 and March 2015. Out of these cases 666 cases were camp cases brought from various villages and Tribal areas of Visakhapatnam district. 1000 patients are selected from patients attending OPD at Govt. Regional Eye hospital. Total 490eyes of 475patients with mature cataracts were screened. H/o Trauma was present in 30patients. Out of 475patients with mature Cataract 175patients were males and 300 were females ranging from 5years to 75years. 15patients were having Bilateral mature cataracts and 75% of mature cataracts were found in camp cases.90% of patients belong to low socioeconomic group. Detailed history was taken and examination with Slit Lamp and Tonometry were done. A. Scan Biometry was performed in all the cases. Informed consent was taken. B-Scan ultrasonography using a standard USG machine (Sonomed B5500) equipped with a real-time high- frequency probe with the contact method was done. Ultrasonic probe was placed over the globe with closed lid after application of the gel and then transverse, antero posterior and longitudinal scans were taken. High Gain [80-90 db] and low gain [60-70 db] sensitivity were selected during Ultrasonography.

**RESULTS:** Out of the 490eyes of 475patients 54[11, 02%] cases Showed posterior segment lesions in Ultrasound. The age range was 5years to 75years. Out of the 47patients 300patients were females and 175 were males and most of the patients were of 50 to 70[75%] years of age indicating senile cataracts [Table1]. History of trauma present in 30 cases that are of the age group of 10 to 35. Out of these cases posterior segment lesions were found in 15 cases. [50%] Out of the54 cases,[Table 2] 14cases[2.85%] found to be Retinal detachment [Figure1], Vitreous haemorrhage in 10cases [2.5%][Fig.2] Posterior staphyloma in 4cases [0.8%] [Fig 5], PVD in 6 cases [1.2 %][Fig7], Asteroid hyalosis in 4cases [0.8%] [Fig 8], Vitreous opacities & exudates in 8cases [1.6%] [Fig3]Variation in Axial length of eyeball was found in 6cases [1.22%], Coloboma choroid in 1 case [0.2%] [Fig6] IOFB in one case [0.2%][Fig4].

Age [yrs.]	No. of Pts [475]
1-9	10
10-19	12
20-29	20
30-39	23
40-49	40
<b>50-59</b>	<b>210</b>
<b>60-69</b>	<b>150</b>
70-79	10

Table :1

## ORIGINAL ARTICLE

Type of Post.seg lesion	No of cases	%
Retinal detachment	14	2.85
Vitreous haemorrhage	10	2.5
Posterior vitreous detachment	6	1.2
Posterior Staphyloma	4	0.8
Vitreous opacities & Exudates	8	1.6
Asteroid hyalosis	4	0.8
IOFB	1	0.2
Coloboma choroid	1	0.2
Variation in Axial length	6	1.22

Table: 2

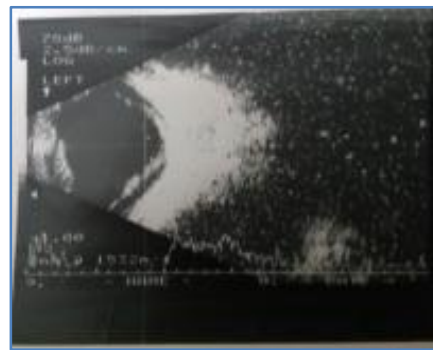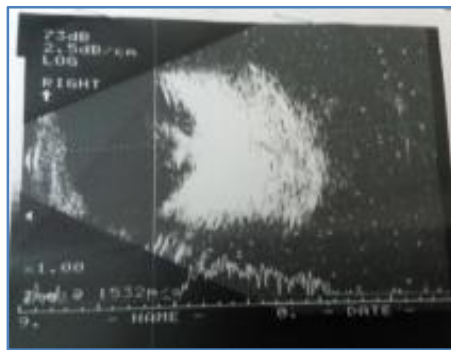
**DISCUSSION:** Under the NPCB [National programme for control of blindness] rural eye camps will be conducted regularly and eligible patients were brought from various interior villages and tribal areas for cataract surgery to Govt. Regional eye hospital, Visakhapatnam. Most of the patients belong to Lower socioeconomic group mostly attending the hospital for the first time with mature cataracts. H/O blunt trauma in the past is also very common in these patients in such patients we cannot assess the posterior segment by any other means except with B-SCAN Ultrasonography. BSCAN ultrasonography is simple, cheaper and easier Technique by which we can exclude most of the posterior segment diseases. In our study out of 490 eyes of 475 patients posterior segment lesions were found in 54 cases [11.02%] where as in the study done by Hanif M and colleagues<sup>9</sup> that showed that 13.87% of the eyes were found to have significant posterior segment pathologies, In another study done by Ali SI and colleagues<sup>10</sup> showed that 11% of the patients with non-traumatic mature cataracts have posterior segment pathologies. In the same study B-scan ultrasonography was performed. Out of 82 post-traumatic mature cataract patients, 54 patients (65.85%) had ultrasonically detectable posterior segment pathologies. The figures of traumatic mature cataracts with posterior segment pathologies were much higher than non-traumatic mature cataracts. In our study 15 out of 30 patients with history of trauma were having posterior segment pathologies.

Out of the 54 cases where posterior segment lesions were found Retinal detachment is the most common 14 cases [2.85%] followed by vitreous haemorrhage 10 cases [2.09%] and PVD in 6 cases [1.22%] especially in cases of trauma. In cases where there is variation in the axial length, Proper care was taken in assessing the IOL power. A-Scan Biometry readings were corresponding with B-Scan findings in the study of Salman A, Parmer P and colleagues (4.1%)<sup>11</sup> of retinal detachments were found 15 eyes (4.2%) had vitreous haemorrhage. Majority of the patients were having history of diabetes as vitreous haemorrhage is more common in proliferative diabetic retinopathy. 16 eyes (4.4%) had PVD. This figure of 4.4% is equal to the study done by Hanif M, and colleagues which showed the percentage of PVD in mature cataracts to be 4.3% other posterior segment pathologies found through B-scan ultrasonography were asteroid hyolosis in 4 eyes (0.8%), posterior staphyloma in 4 cases [0.8%]. In patients with posterior staphyloma extra care must be given while injecting local anesthesia because of the chances of globe perforation

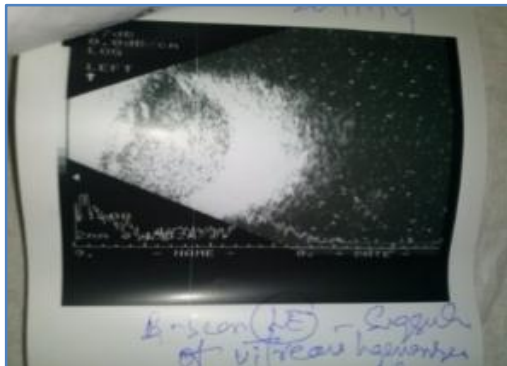**Conclusions:** B-Scan Ultrasound is a useful diagnostic tool for the detection of hidden posterior segment lesions in mature cataract patients and should be performed in preoperative cataract patients. Diagnosis of posterior

## ORIGINAL ARTICLE

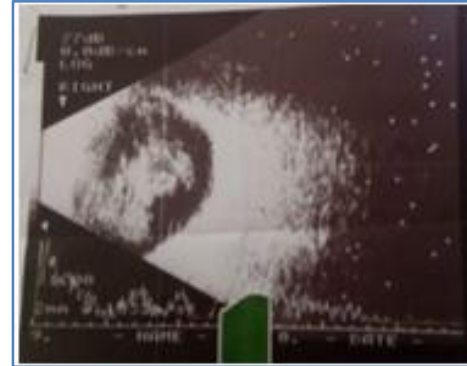segment lesions like RD and vitreous haemorrhage in eyes with traumatic cataract is of immense value in planning and execution of surgery.



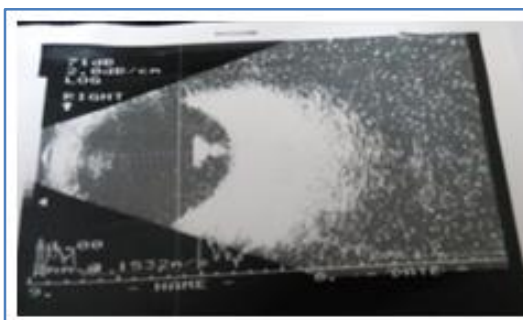
**Fig. 1: Ultrasonography of the Globe Shows a Retinal Detachment**



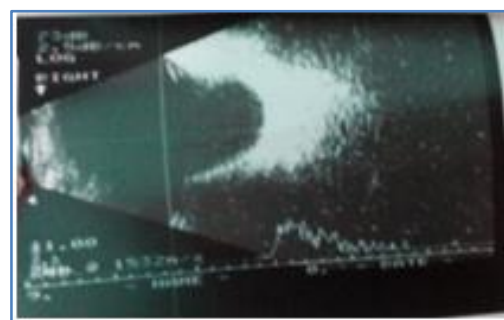
**Fig. 2 Ultrasonography of the Globe Shows Vitreous Hemorrhage**



**Figure 3. Ultrasonography of the globe showing Vitreous exudate**

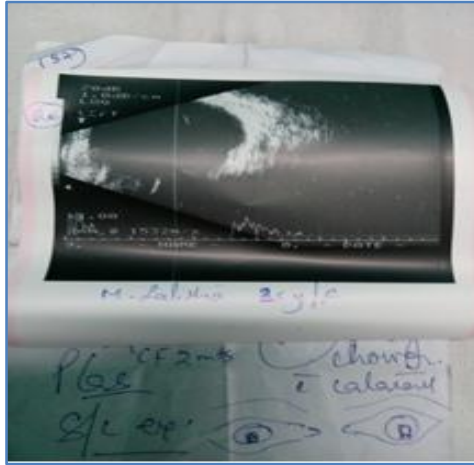


**Fig: 4 Ultrasonography of the Globe Shows Staphyloma Intra Ocular Foreign Body**

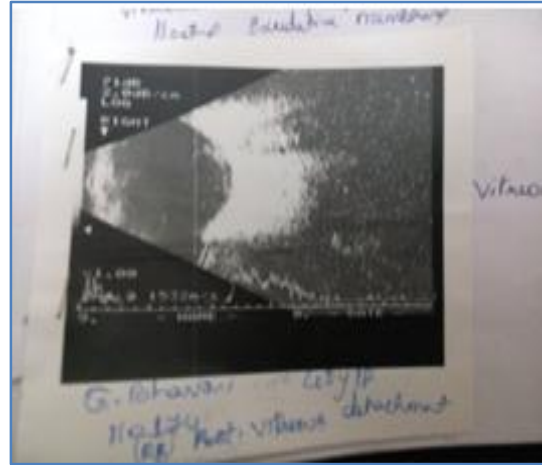

**Figure 5 Ultrasonography of the globe showing Posterior staphyloma**

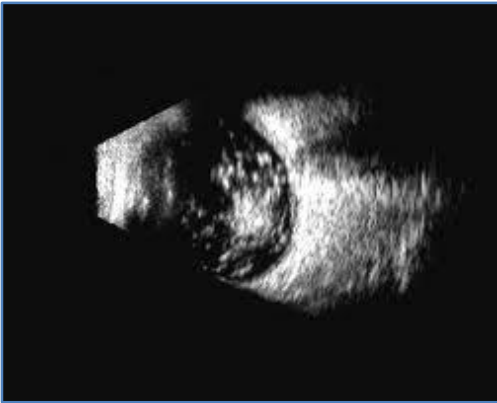## ORIGINAL ARTICLE



**Figure 6 Ultrasonography of the globe shows Coloboma choroid**



**Figure 7: Ultrasonography of the globe shows posterior vitreous detachment**



**Fig: 8 Ultrasonography of Globe Shows Asteroid Hyalosis**

### REFERENCES:

1. Mundt GH, Hughes WF. Ultrasonics in ocular diagnosis. Am J Ophthalmol. 1956; 41:488-98. [PubMed].
2. Baum G, Greenwood I. The application of ultrasonic locating technique to ophthalmology. Arch Ophthalmol. 1958; 60:263-79. [PubMed].
3. Till P, Osoining KC. Ten year study on clinical echography in intraocular disease. Bibl Ophthalmol. 1975; 83:49-62. [PubMed].
4. Hodes BL. Eye disorders: Using ultrasound in ophthalmic diagnosis. J Postgrad Med. 1976; 59:197-203. [PubMed].
5. Zafar D, Sajad AM, Qadeer A. Role of B-Scan ultrasonography for posterior segment lesions. Pak J LUMHS. 2008; 7:7-12.
6. Khan AJ. Malignant melanoma. Pak J Ophthalmol. 1985; 1:3-5.

## ORIGINAL ARTICLE

7. Bello TO, Adeoti CO. Ultrasonic assessment in pre-operative cataract patients. Niger Postgrad Med J.2006; 13(4):326–8. [PubMed].
8. Ahmed J, Shaikh FF, Rizwan A, Memon MF. Evaluation of vitro-retinal pathologies using B-scan ultrasound. Pak J Ophthalmol. 2009; 25:4.
9. Hanif M, Munir MS, Altaf S, Ali M. Role of preoperative B-scan to detect posterior segment pathologies in eyes with age related mature cataract. Al-Shifa J Ophthalmol. 2007;3(2):61-6.
10. Ali SI, Rehman H. Role of B-scan in preoperative detection of posterior segment pathologies in cataract patients. Pak J Ophthalmol. 1997; 13(4):108–112.
11. Salman A, Parmar P, Vanila CG, Thomas PA, Jesudasan CA. Is ultrasonography essential before surgery in eyes with advanced cataracts? J Postgrad Med. 2006; 52(1):19–22. [PubMed].

### AUTHORS:

1. Vepa Meenakshi
2. Tammana Jyothiramayi
3. Bharani Shree

### PARTICULARS OF CONTRIBUTORS:

1. Assistant Professor, Department of Ophthalmology, Govt. Regional Eye Hospital, Andhra Medical College, Visakhapatnam.
2. Assistant Professor. Department Ophthalmology, Govt. Regional Eye Hospital, Andhra Medical College, Visakhapatnam.

### FINANCIAL OR OTHER

**COMPETING INTERESTS:** None

3. Post Graduate, Department of Ophthalmology, Andhra Medical College, Visakhapatnam.

### NAME ADDRESS EMAIL ID OF THE CORRESPONDING AUTHOR:

Dr. Vepa Meenakshi,  
Flat 101 'B' Block, Golden Homesapts,  
Resapuvanipalem,  
Visakhapatnam.  
E-mail: meenakshivepa@gmail.com

Date of Submission: 25/09/2015.  
Date of Peer Review: 26/09/2015.  
Date of Acceptance: 05/10/2015.  
Date of Publishing: 14/10/2015.