

MANAGEMENT OF FRACTURES OF SHAFT OF HUMERUS WITH LOCKING COMPRESSION PLATES: ARE LCPS THE IDEAL IMPLANTS?Prasad Murugappa Gowda¹, Arif Mohammed Shaik², Nabeel Mohammed³**HOW TO CITE THIS ARTICLE:**

Prasad Murugappa Gowda, Arif Mohammed Shaik, Nabeel Mohammed. "Management of Fractures of Shaft of Humerus with Locking Compression Plates: Are LCPs the Ideal Implants?". Journal of Evolution of Medical and Dental Sciences 2014; Vol. 3, Issue 49, October 02; Page: 11687-11694, DOI: 10.14260/jemds/2014/3535

ABSTRACT: BACKGROUND: The recent development of LCP has revolutionized the surgical treatment of fractures by overcoming the few drawbacks of older internal fixators. The fractures of the shaft of humerus are one of the commonest fractures found and the accepted management for fractures shaft of humerus is open reduction and internal fixation using compression plating. Our present study is aimed at the assessment of results of plate osteosynthesis of diaphyseal fractures of humerus using locking compression plate and to assess the functional recovery with this procedure.

MATERIALS & METHODS: In the study period of two years, 20 cases of fracture shaft of the humerus were treated by open reduction and internal fixation using Locking Compression Plate. **RESULTS:** In our series, majority of the patients were males, middle aged, with road traffic accidents being the commonest mode of injury, involving middle third of shaft of humerus. Follow up ranged from 6 weeks to 24 weeks. There was significant improvement in DASH scores ($P=0.001$) in all the 20 cases indicating the functional recovery. According to Rommen's et al grading, 17 cases had excellent results while 3 cases had good results. **CONCLUSIONS:** The age incidence varied from 21-40 years (65%) with male predominance (70%), with type A3 as the commonest fracture (50%) involving the mid shaft (70%) of humerus, underwent open reduction and internal fixation using locking compression plate. The results were assessed using DASH score and the significant functional recovery was achieved in all the cases, with Rommen's grading, excellent and good results were achieved.

KEYWORDS: fracture shaft humerus, LCP, locking compression plate.

INTRODUCTION: With the rapid industrialization and growth of infrastructure facilities requires speedy transport system to cope up with development. The ever increasing vehicular traffic, leads to considerable increasing number of road traffic accidents. Speedy vehicles cause high velocity injuries associated with complicated fractures. Fracture patterns are often grossly comminuted and open resulting in greater morbidity among the working population. The other cause of fractures being direct blow, fall from height, assault, gunshot injuries and blast victims of terrorist activities.

Fractures of shaft of humerus account for 1% to 3% of all fractures and approximately 20% of all fractures involving the bone, but little is known about their epidemiology.¹ More and more, devices and implants are designed to cope up with various complex fracture patterns. Gone are the days when open fractures are treated with pin and plaster and other techniques allowing the wounds to heal by secondary intention.

The prevalence of humeral shaft non-union as a complication of both non-operative and operative treatment has been reported to range from 8% to 12%.² In elderly patients to give early mobility and better functional outcome surgical modalities are attempted with better fixation devices to enhance early mobilization.

ORIGINAL ARTICLE

Whatever the orthopedic surgeon does is basically to splint the fracture in a proper alignment and hold it till the union occurs. Union has to occur by itself and surgeon's role is restricted to appropriately aligning the fractures and holding it by the suitable implants. The failure to hold the alignment results in loss of fixation and loosening of the implants, which ultimately leads to malunion and non-union resulting in loss of function. Re-operation increased the overall morbidity.

When operative fixation is indicated for humeral shaft fractures, plate osteosynthesis is the gold standard to which other methods must be compared.³ Plate osteosynthesis provides enough stability to allow early upper extremity weight bearing in poly trauma patients and produces minimal shoulder or elbow morbidity, as shown by Tingstad et al.⁴ The AO group has devised excellent implants for the fixation of fractures like dynamic compression plate for adult's shaft fractures of tubular bones. Locking compression plate is a device in which the screws are locked into the threads provided in the hole of the plates.

So, that the plate and screw become a single assembly. This is a advantage, that backing out of the screw resulting in loosening of the plate with failure of fixation may not occur especially in case of osteoporotic bone, poor quality bone, metaphysical fixation etc. It offers numerous fixation possibilities and has proven its worth in complex fracture situations and in revision operations after the failure of other implants. Biomechanical studies have shown that compared to other types of available implants, the locking plate is comparatively flexible and maximizes fracture stabilization by minimizing the peak stresses at the bone-implant interface.⁵

The two main approaches to fracture are plate fixation, compression plating and internal splinting-result in differing biomechanics and subsequent healing response patterns. A number of advantages to using the newer internal fixators have been described, but there are still several indications for traditional compression plating.⁶ It has also been theorized that locking constructs may have a lower incidence of re fracture because the more exuberant callus created by secondary bone healing may lead to mechanically more stable construct.⁷ This study is undertaken to assess the results of plate osteosynthesis of humeral dyaphyseal fractures with locking compression plate, assess the functional recovery and compare it with that in recent literature.

MATERIALS AND METHODS: Twenty patients with fracture of shaft of humerus were included in this study after obtaining their informed and written consent from the period of October 2012 to March 2013. Our inclusion criteria targeting all patients in age group of 15 years and above, all closed and Gustillo Anderson type 1 open fracture, non-union of fracture shaft of humerus, poly trauma patients and those associated with Radial nerve palsy.

We did not include pathological fractures, open fractures of Gustillo Anderson type 2 & 3, segmental fractures and cases of mal-union. Clearance from institutional ethical committee was obtained before initiating the study. All patients are admitted and subjected to clinical & radiological examination, necessary lab investigations are carried out for proposed surgery. Regular follow up was carried out by clinical examination and with radiographs at 6 weeks, 3months and 6 months.

The primary difference with the locking compression plate is the method of locking head screw insertion. Here since the locking head of the screw has to get locked in the locking part of the combi-hole, the direction of the drilling has to be perfect. Hence drilling for all locking head screws has to be after fixing the screw-in drill sleeve (available with the locking compression plate set). Also, the tactile feel of the surgeon when inserting the regular cortical screw is lost while inserting the

ORIGINAL ARTICLE

locking head screw, as this gets locked regardless of the quality of bone and the depth of insertion. Hence we have determined the length of the screw in each case so as not to miss the far cortex. We also made sure that whenever using the non-locking regular cortical screws in the fixation, they were inserted prior to the insertion of the locking screws.

In this study, antero-lateral approach was used in 12 patients, and posterior approach was used in 8 patients. All the cases were performed without using tourniquet. Blood loss was minimal. Maximum blood loss found was 200 ml. Overall time taken for surgery was 35-45 minutes. In all the cases intraoperative period was uneventful. Haemostasis was achieved using bipolar cautery in all cases. Radial nerve was visible in few cases and was secured. Immediate postoperative period was uneventful. All the cases were put in intensive care unit for 24hrs postoperatively. In the immediate post-operative period, care was given to the general condition and fluid balance.

Parenteral cephalosporins and sulbactam antibiotic combination for 3 days, and analgesics were given. Oral antibiotics were given for next 3-4 days. Oral analgesia was started from 2nd day till adequate pain relief was obtained. Suture removal was done after 1 week. Post operatively shoulder range of motion and elbow movements is begun actively within the third or fourth postoperative day. After around 1 week, sutures were removed and patients were discharged and advised to come for followup after 6 weeks. Patients were advised to continue exercise therapy and arm support with arm pouch for 3-4 weeks.

The first follow up was usually at 6 weeks and later on patients were followed up at 3 months and 6 months. During each follow up each case was examined for pain, functional recovery of shoulder, elbow, and hand. The course of fracture healing was documented radiologically (with minimum of 6 weeks between successive radiographs). The moment of complete healing was defined as radiologically complete bone regeneration at the fracture site.

Radiological assessment of implant position, fracture reduction and healing in progress (i.e., observing whether if there is any widening of fracture line or decrease in the fracture gap) was done. Evaluation of any possible loss of reduction that might have occurred compared to immediate post of radiographs and analysis of any complications observed. All patients were subjected to Disabilities of Arm Shoulder and Hand (DASH) scoring and Rommen's et al Series Grading.⁸ Follow up ranged from six to twenty four weeks and no patients were lost for follow up.

OBSERVATION & RESULTS: We studied twenty patients with fracture shaft (diaphyseal) humerus, who were treated with locking compression plate from the period October 2011 to September 2013. The follow up ranged from 6 weeks to 6 months, and the results were assessed both clinically and radio logically. The age group of the patients in our study ranged from 15 years to 65 years. We had 3 patients (15%) less than 20 years, 6 patients (30%) in 21-30 years, 7 patients (35%) in 31-40 age years and 4 patients (20%) in more than 40 years age groups.

There were 14 males (70%) and 6 females (30%). In our series,10 (50%) fractures are right sided and 10(50%) fractures are left sided. 14(70%) cases were having fracture located in middle third of shaft, in 6(30%) cases the fractures was in lower third of humeral shaft. In our study the most common fracture pattern is A3 (Transverse) in AO classification which accounts to 50% of the overall fracture pattern (Table 1).

The commonest mode of injury was road traffic accidents (55%) seen in 11 patients. Nine patients had a history of fall (45%). In our present study, 1 patient (5%) had ipsilateral fracture

ORIGINAL ARTICLE

radius and ulna along with the fracture shaft of humerus. Follow up was done at 6 weeks, 12 weeks and 24 weeks and observations tabulated as in (Table 2). DASH scores were assessed for all the 20 patients individually at 6 weeks, 3 months and 6 months after the operation (Table 3). There was improvement in the scores indicating the functional recovery with this procedure.

ANOVA statistical analysis was helpful in calculating our result (Graph 1). According to Rommen's grading, we had 17(85%) patients with Excellent and 3(15%) patients with Good results (Table 4). Regarding complications, 3 cases of superficial infection was noted. Suture removal was delayed for these patients and prolonged administration of oral antibiotics was given. Infections subsided and eventually healed without any further complication. We had no case of any pure implant related complication like loosening, screw breakage or plate failure.

DISCUSSION: In the present study the commonest age incidence was 15 to 65 years. Most of the patients belong to middle aged. This is due to the fact that persons of this age group are more exposed to road traffic accidents and other trauma, which are the commonest cause of humeral shaft fractures. The average age incidences in other series are as tabulated in (Table 5). Most of the patients were males. It reflects the general population which visit our both outpatient as well as the emergency trauma section. Sex incidences compared to other series are as (Table 6).

In our series, left humerus was involved in 50% cases, while right was involved in the other 50% of cases which was consistent with other studies.^{9,10} Our commonest site of fracture was over the shaft of the humerus which was consistent with other studies.^{9,10,11,12} The commonest type of fracture in various other studies correspond to our present study which were transverse fractures Type A3. RTA was the most common mode of injury which corresponded to the above studies.

The clinical assessment was done on the basis of shoulder and elbow movements and DASH questionnaire. Radiologically union was taken into account. The patients were asked to come to the outpatient department for follow up after 6 weeks, 12 weeks, 24 weeks. All the complaints were documented and the clinical performance and all patients were examined clinically and radiologically. DASH scores were showing significant ($P=0.001$) improvement in the follow up period indicating the functional recovery with this procedure.

ANOVA statistical analysis was helpful in calculating our results. The functional results were graded into excellent, good, fair and poor. We had 17(85%) patients with Excellent and 3(15%) patients with Good results. Healing or union has been variously defined as the presence of bridging callus on plain radiograph (Aim 1952, Hamza 1956), the absence of pain on deformation at fracture site (Vicoldo et al 1962), the ability of the patient to bear full weight without external support (Groven et al 1972) or a combination of these. 19 (95%) fractures out of our 20 cases were united at the end of 3 months, and 1(5%) case of delayed union seen at the end of 6 months.

There was no case of non-union post operatively (Table 7). Out of 20 patients in our series, all patients had good range of movements at shoulder and elbow. Our results in mobility at shoulder and elbow joints are comparable with those of Bell MJ et al, and McCormack RG et al (Table 8). In the present study, 3 cases of superficial infection were noted. Suture removal was delayed and prolonged administration of oral antibiotics was given and eventually healed without any further complication.

CONCLUSION: This is a prospective study with age incidence varied from 21-40 years (65%) with male predominance (70%), with type A3 as the commonest fracture (50%) involving the mid shaft

ORIGINAL ARTICLE

(70%) of humerus, underwent open reduction and internal fixation using locking compression plate. All the cases had adequate physiotherapy started on 3rd or 4th postoperative day and continued for 3-4 weeks, which had contributed for the excellent functional recovery.

The results were assessed using DASH score and the significant functional recovery was achieved in all the cases (P=0.001), with Rommen's grading, excellent and good results were achieved. It is a very good procedure for fractures of shaft of humerus; however the small sample size and short duration of study were the limitations of this study.

REFERENCES:

1. Ekholm R. et al, Fractures of the shaft of the humerus: The Journal Of Bone And Joint Surgery (Br)., November 2006, 88(11).
2. Hierholzer C, Sama D, Jose B. Toro, Margaret Peterson, and David L. Helfet,, Plate Fixation Of Ununited Humeral Shaft Fractures: Effect Of Type Of Bone Graft On Healing: Journal Of Bone And Joint Surgery (Br). July 2006, 88(7).
3. Scolaro J, Jonas L. Matzon, Samir Mehta, Tips And Techniques- Surgical Fixation Of Extra-Articular Distal Humerus Fractures With A Posterolateral Locking Compression Plate(LCP)., University Of Pennsylvania Orthopaedic Journal, (19).
4. Andrew H. Crenshaw, Jr. and Edward A. Perez., Fractures Of Shoulder, Arm And Forearm; Operative Orthopaedics, Campbell 11th ed; p.no. 3389-98.
5. Kenneth A. Egol et al, Early Complications In Proximal Humerus Fractures(OTA Type 11) Treated With Locked Plates; Journal Of Orthopaedic Trauma; March 2008; 22(3); 159-64.
6. Gardner MJ, Helfet DL, Lorich DG. Has locked plating completely replaced conventional plating? Am J Orthop. 2004 Sep; 33 (9): 439-46.
7. Grant, Richard, N. William, Marc J, and David S., Can Locking Screws Allow Smaller, Low-Profile Plates To Achieve Comparable Stability To Larger, Standard Plates?; Journal Of Orthopaedic Trauma; June 2011; 25(6):347-54.
8. Rommens PM, Verbruggen J, Broos PL. Retrograde locked nailing of humeral shaft fractures. A review of 39 patients. J Bone Joint Surg 1995; 77B: p.84-9.
9. Klennermann, L. Fractures of shaft of humerus. J Bone and J Surg Br 1966; 48: 105-11.
10. Tingstad EM, Wolinsky PR, Shyr Y, Johnson KD. Effect of immediate weight bearing on plated fractures of the humeral shaft. J trauma 2001; 49 (2): 278-80.
11. Bell MJ, Beauchamp CG, Kellan JK, Mc Mutry RY. The result of plating humeral shaft fractures in patients with multiple injuries. J Bone Joint Surg Br 1985; 67 (2): 293-6.
12. Griend RV, Tomasin J, Ward EF. Open reduction and internal fixation of humeral shaft fractures. J Bone Joint Surg Am 1986; 68A: 430-3.
13. Mc Cormack RG, Brien D, Buckley RE, McKee MD, Powell J. Fixation of fractures of the shaft of the humerus by dynamic compression plate or intramedullary nail. J Bone Joint Surg Br 2000; 82 (3): 336-9.
14. Gongol T, Mracek D. Functional therapy of diaphyseal fractures of the humeral bone. Acta Chir Orthop Traumatol Cech 2002; 69 (4): 248-53.
15. Bell MJ, Beauchamp CG, Kellan JK, Mc Mutry RY. The result of plating humeral shaft fractures in patients with multiple injuries. J Bone Joint Surg Br 1985; 67 (2): 293-6.

ORIGINAL ARTICLE

16. Griend RV, Tomasin J, Ward EF. Open reduction and internal fixation of humeral shaft fractures. J Bone Joint Surg Am 1986; 68A: 430-3.

Type of fracture	Frequency	Percent
Type A1	1	5.00%
Type A2	7	35.00%
Type A3	10	50.00%
Type B2	2	10.00%
Total	20	100.00%

TABLE 1: Type of Fracture

Parameters	Overall Observations in 20 patients		
	6 weeks follow up	3 months follow up	6 months follow up
Pain	Pain (mild) was present in 6 cases	No pain	No pain
Course of fracture healing, Radiological assessment of implant position, fracture reduction and healing in progress, Evaluation of any possible loss of reduction	Fracture line was visible in 12 cases, Implant position satisfactory in all the cases, No signs of loss of reduction in any case	Fracture line not visible except in 1 case, Implant position satisfactory in all the cases	Fracture line not visible in all the cases, implant position satisfactory in all the cases
Assessment & analysis of any complications	superficial wound infection seen in 3 cases	No complications	No complications
DASH scoring, Rommen's grading.	DASH: 25.55 ± 4.41	DASH: 16.75 ± 4.07	DASH: 6.05 ± 3.47 Excellent: In 17 cases solid union had seen, no loss of range of movements, and no significant subjective complaints. Good: In 3 cases solid union had seen, 10-20% loss of range of motion at elbow and shoulder.

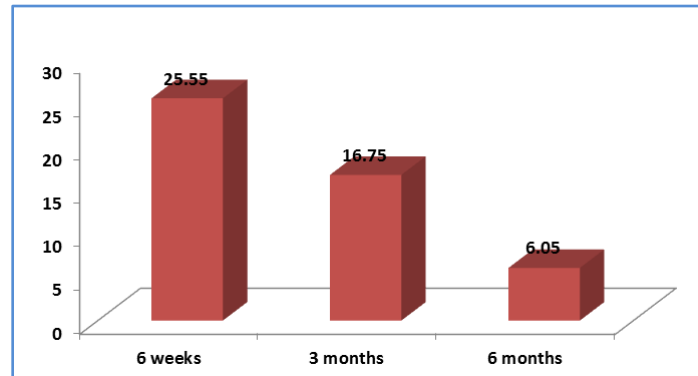
TABLE 2: Follow up Observations

ORIGINAL ARTICLE

DASH score	Mean \pm SD
6 weeks	25.55 \pm 4.41
3 months	16.75 \pm 4.07
6 months	6.05 \pm 3.47

TABLE 3: DASH Scoring

F value: 118.77 P value: 0.001 Interpretation: Significant



GRAPH 1: ANOVA Analysis

Rommens Grading	Frequency	Percentage
Excellent	17	85.00%
Good	3	15.00%
Total	20	100.00%

Table 4: Rommens Grading

Series	Year	Total no. of patients	Average Age
McCormack RG et al ¹³	2000	44	49
Gongol T, Mracek D ¹⁴	2002	32	47
Present Study	2013	20	35

Table 5: Age Incidence as compared to other studies

Series	Year	Total no of patients	Average Age
McCormack RG et al ¹³	2000	44	49
Gongol T, Mracek D ¹⁴	2002	32	47
Present Study	2013	20	35

Table 6: Sex incidence compared to various other studies

ORIGINAL ARTICLE

Series	Total no. of patients	Delayed union	Nonunion	Overall results
Bell MJ et al(1985) ¹⁵	34	-	1(3%)	33(97%)
Griend RV, Tomasin J, Ward et al (1999) ¹⁶	36	5(14.6%)	1(3%)	35(97%)
Gongol T, Mracek D (2002) ¹⁴	32	-	1(3.1%)	31(96.9%)
Present study (2013)	20	1(5%)	-	19(95%)

Table 7: Fracture union rate obtained as compared to other studies

Study	No. of Patients	Good range of Mobility	%
Bell MJ et all (1985) ¹⁵	39	38	97
Griend RV, Tomasin J, Ward et al (1986) ¹⁶	36	30	85.4
McCormack RG et al (2000) ¹³	44	44	100
Gongol T, Mracek D (2002) ¹⁴	32	31	97
Present Study (2013)	20	20	100

Table 8: Range of mobility of Elbow & Shoulder as compared to other studies

AUTHORS:

1. Prasad Murugappa Gowda
2. Arif Mohammed Shaik
3. Nabeel Mohammed

PARTICULARS OF CONTRIBUTORS:

1. Associate Professor, Department of Orthopaedics, Sri Siddhartha Medical College, Tumkur.
2. Resident, Department of Orthopaedics, Sri Siddhartha Medical College, Tumkur.
3. Resident, Department of Orthopaedics, Sri Siddhartha Medical College, Tumkur.

NAME ADDRESS EMAIL ID OF THE CORRESPONDING AUTHOR:

Dr. Nabeel Mohammed,
C/o Department of Orthopaedics,
Sri Siddhartha Medical College,
Agalakote, B. H. Road,
Tumkur, Karnataka-572107.
Email: drnabeel99@gmail.com

Date of Submission: 09/09/2014.
Date of Peer Review: 10/09/2014.
Date of Acceptance: 20/09/2014.
Date of Publishing: 30/09/2014.