

CORRECTION OF MYOPIA USING CORNEA SPARING LASIK (ABLATION ON FLAP)Nikhilesh Wairagade¹, Vikas Mahatme², Atul Borkar³, Sudha Sutaria⁴, Chitra Pande⁵**HOW TO CITE THIS ARTICLE:**

Nikhilesh Wairagade, Vikas Mahatme, Atul Borkar, Sudha Sutaria, Chitra Pande. "Correction of Myopia using Cornea Sparing Lasik (Ablation on Flap)". *Journal of Evolution of Medical and Dental Sciences* 2015; Vol. 4, Issue 18, March 02; Page: 3101-3109, DOI: 10.14260/jemds/2015/450

ABSTRACT: Cornea sparing lasik is useful tool allowing surgeons to preserve the posterior stroma. The study comprised of prospective evaluation of 17 eyes treated with CSL – Cornea Sparing Lasik at Mahatme Eye Bank Eye Hospital, Nagpur India. Our results show that the laser ablation on the corneal flap is safe and effective procedure. The refractive, efficacy and safety outcomes were similar to those in routine Lasik ablation on posterior stroma.

KEYWORDS: Myopia, refractive surgery, Lasik, CSL (Cornea Sparing Lasik), PRK, refraction, keratome, hansatome, spherical equivalent (SE) refraction, BSCVA (Best surgically corrected visual acuity), keratectasia, RST (Residual Stromal Thickness).

INTRODUCTION: LASIK stands for Laser assisted in situ keratomileusis. Since 1980s lasers have been tried to alter corneal curvature for improvement of refractive errors.¹ The development of excimer laser represents a major technological breakthrough in the utilization of lasers for correction of ametropia. Presently LASIK (Laser assisted in situ keratomileusis), PRK (Photorefractive keratectomy), LASEK (Laser sub-epithelial keratectomy) etc are used for correction of myopia. They treat ametropia by employing 193 nm argon fluoride excimer laser to ablate the anterior corneal stroma to a new radius of curvature to decrease myopia, hyperopia & astigmatism. First LASIK on human eye was performed by Pallikaris in 1990.² Since then this procedure has undergone extensive investigation and is now considered by many ophthalmologists to be reasonably safe and effective. LASIK has become a common technique for treatment of low to moderate myopia worldwide often with more predictable and stable results than incisional keratotomy.^{3,4} Cornea Sparing LASIK (CSL) is an approach to ablative surgery that minimizes the risk for inadequate residual stromal thickness (RST). The 3 components of CSL are keratectomy targeting a thin flap (mean 120 micron), intraoperative pachymetry to determine true flap thickness and ablation on the under surface of flap when necessary to preserve RST. If part or all the ablation is placed on the undersurface of the flap, less posterior stroma is removed. The present study aimed to find out safety, efficacy, predictability and visual outcome of CSL.

MATERIALS AND METHODS: A prospective non comparative study was done on 17 eyes; 8 right eyes and 9 left eyes of 11 patients. 4 were males and 7 females. The study was conducted at Mahatme Eye Bank Eye Hospital, Nagpur, India between September 2004 and January 2006 after ethics committee approval. Cornea sparing Laser in situ keratomileusis (LASIK) with ablation on posterior stromal bed as well as on the undersurface of flap was performed in all cases. The procedure was performed as a primary procedure in all cases. This approach is used in those patients in whom total refractive correction on stromal bed was likely to risk for inadequate residual stromal thickness even <250 microns. In these situations, part of the ablation was placed on flap to optimize RST.

ORIGINAL ARTICLE

Part of spherical correction and whole of cylindrical correction was placed on posterior stroma as alignment of axis is more predictable and part of sphere was placed on the undersurface of flap. Single surgeon performed all the procedures.

Inclusion Criteria:

1. Age 18 to 45 years.
2. Normal anterior segment.
3. Stable refractive error for more than 6 months.
4. Normal videokeratography i.e. not showing evidence of ectatic disease.

Exclusion Criteria:

1. Unstable refraction.
2. Corneal thinning disease.
3. Presence of ectasia or any other corneal pathology.
4. Past history of corneal surgery likes refractive surgery or penetrating keratoplasty.
5. Central corneal vascularization.
6. Dry eye.
7. Glaucoma.
8. Small palpebral aperture.
9. Sunken eyes.
10. Mono ocular patients.
11. Patients with lid problems like blepharitis.
12. Deep amblyopia.
13. Retinal pathology markedly limiting visual performance.
14. Presence of bleb after glaucoma filtering surgery.
15. Systemic or ocular vascular disease.
16. Autoimmune diseases as they might affect wound healing.
17. Pregnancy and immunocompromised states.

Counseling of Patients: This has significance as unrealistic expectations are the most common causes of dissatisfaction after refractive surgery. Care was taken to make patient understand that no refractive surgery is perfect and it may not be possible to achieve same quality of vision as with spectacles or contact lenses in all the cases.

Preoperative evaluation consisted of uncorrected visual acuity for both – distance and near; best spectacle corrected visual acuity, manifest and cycloplegic refraction, ocular dominance, keratometry, applanation tonometry, scotopic pupillary size, tear film break up time, blinking rate, Schirmer test when necessary, pachymetry, slitlamp examination and computerized videokeratography. In all patients, fundus photography was done using indirect ophthalmoscopy for screening the peripheral retina in order to rule out associated retinal pathology that might predispose to retinal detachment. A suspicious lesion was treated with laser or cryotherapy and in those patients surgery was postponed for 8 to 12 weeks.

Specialized Instruments: These included Hansatome, Microkeratome, Laser delivery system, Barraquer tonometer, Videokeratography, Pachymeter.

Surgical Steps:

1. Corneal marking.
2. Tonometry.
3. Excimer Laser ablation: This requires a special mention for CSL – Cornea Sparing LASIK. Initial ablation is done on stromal bed. Usually part of sphere and total cylindrical refractive power is corrected on posterior stromal bed. After completion of ablation on posterior stroma, one or two drops of distilled water are placed on stroma.
4. Repositioning of the flap.
5. Ablation on flap: As shown in figure 1, a reference mark was placed over the corneal epithelium over the center of pupil. This mark was readily visible through the flap and was used to align the laser aiming beam during ablation. The flap was reflected back again. Patient was asked to look down towards the tip of his/her great toe. The flap was held with forceps onto the sclera and the predetermined spherical ablation was applied to flap. Then flap was reposed back again after putting 1 to 2 drops of distilled water on stromal bed. The stromal bed was irrigated under the flap to remove any debris from interface. Excess of fluid was removed by gently wiping the flap downward from the hinge using merocel sponge. Alignment of flap confirmed by using replaced reference mark. After 2 minutes the peripheral cornea was depressed. Transmission of resultant striae on the flap was taking as evidence of optimal adhesion.

Fig. 1: A mark representing the pupil center is placed on the epithelium before the flap is cut or lifted.

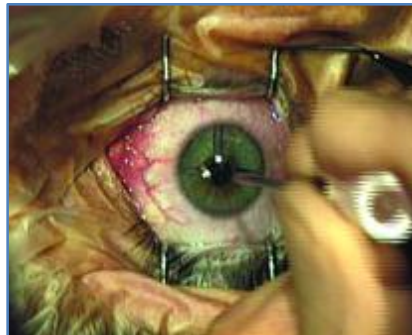

Fig. 1

Fig. 2: The flap treatment instrument is positioned before the flap is lifted.

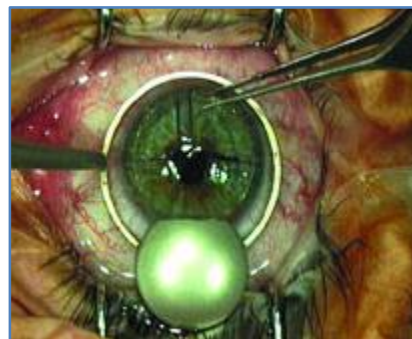


Fig. 2

Fig. 3: The wrinkle-free flap is draped smoothly over the dome of the flap treatment instrument.

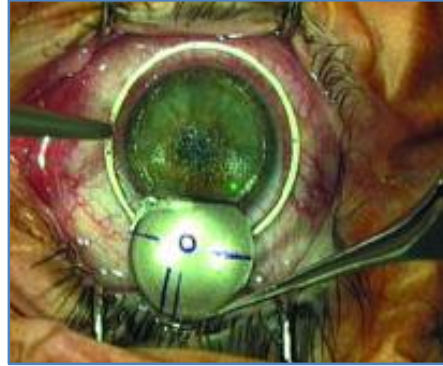

Fig. 3

Source: Patrick Versace, M.D.⁵.

6. Postoperative follow up: done on day 2, 1 wek, 1 month, 3 months and then 6 monthly.

OBSERVATIONS: The statistical analysis done by paired 't' test. The study included 17 eyes of 11 patients. The mean age in years was 23.76 +/- 4.146 (SD) (Range 19 to 35 yrs)

Parameter	Patients
Bilateral cases	6 (54.5%)
Unilateral cases	5 (45.5%)
Women	7 (63.6%)
Men	4 (36.4%)

Table 1: Demographics of 17 patients in study group

In all eyes emmetropia was the target. The mean preoperative SE (Spherical Equivalent) was -9.479 +/- 3.008 (SD); (range -5.75 to -16 D). Mean preoperative cylinder was -0.97 +/- 1.208 (SD) (range -0.5 to -4.5). the mean Preoperative UCVA (Uncorrected visual acuity) was 0.031 +/- 0.002 (range 0.02 to 0.02 to 0.05 i.e. 1/60 to 3/60) and the mean preoperative BCVA (Best corrected visual acuity) was 0.0831 +/- 0.222 (range 0.5 to 1.2 i.e. 6/12 to 6/5).

In all eyes the mean residual stromal thickness was 265 μ m (range 253 to 296 μ m). The mean ablation on flap was 38.6 μ m (range 20 to 56 μ m). Mean optical zone on flap was 5.95 mm (range 5.5 to 6.5mm). Mean sphere treated on flap was -2.54 (range -1 to -4 D). No cylinder was treated on flap.

The mean follow up period of patients was 8 months – range being 1 to 12 months.

UCVA: Mean Uncorrected Visual Acuity improved 3 months postoperatively from 0.031 +/- 0.009 to 0.812 +/- 0.217 (SD). The postoperative UCVA ranged from 0.50 to 1.2 i.e. 6/12 to 6/5. All the 17 eyes had UCVA of 6/12 or better and 7 eyes (41.17%) had UCVA of 6/6 or better.

BSCVA: Mean Best surgically corrected visual acuity improved from 0.831 +/- 0.222 (SD) to 0.9318 +/- 0.162. The postoperative BSCVA ranged from 0.33 to 1.2 (6/9 to 6/5). Postoperatively, 12

ORIGINAL ARTICLE

eyes (70.58%) maintained BSCVA while 5 eyes (29.41%) had improvement in BSCVA. No eye lost more than 2 lines of BCVA.

SER: Spherical equivalent refraction: The mean SE refraction at 3 months postoperatively was -0.042 ± 0.659 (SD): range +1.5 to -1.25. 15 eyes (88.23%) had SE within ± 1.0 D.

Astigmatism: The mean postoperative cylinder was -0.17 ± 0.372 (range +0.5 to -0.75).

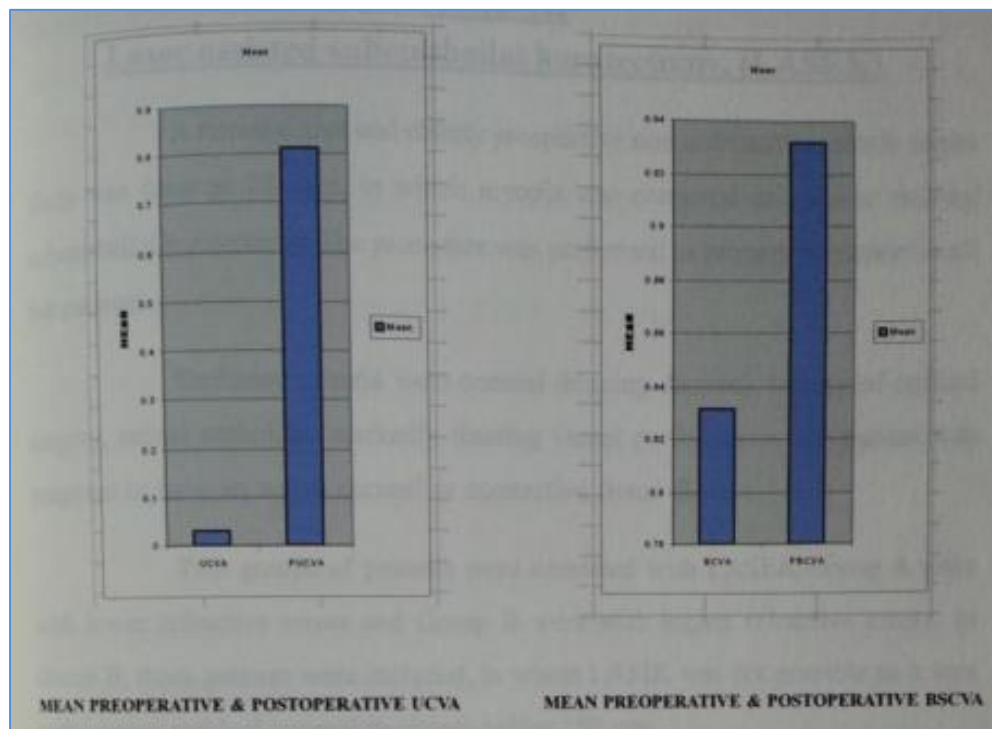
Safety Index: It is the ratio of mean postoperative BCVA to mean preoperative BCVA. This was 1.12 in our study.

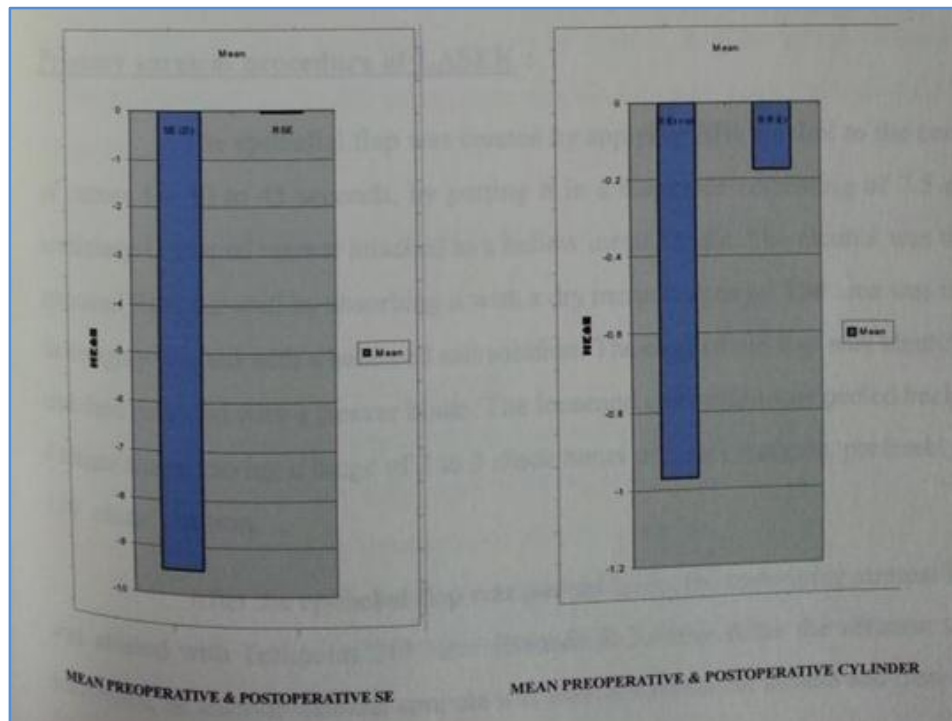
Efficacy Index: It is the ratio of mean postoperative UCVA to mean preoperative BCVA and was 0.977 in our study.

Criteria	Preoperative	Postoperative	P value
SE Refraction	-9.479 ± 3.008 (-5.75 to -16 D)	-0.04 ± 0.659 (-1.25 to +1.5)	$P < 0.001$
Cylinder	-0.97 ± 1.208 (-0.5 to -4.5)	-0.17 ± 0.372 (-0.75 to +0.5)	$P < 0.001$
UCVA	0.031 ± 0.009 (0.02 to 0.5)	0.812 ± 0.217 (0.5 to 1.2)	$P < 0.001$
BSCVA	0.831 ± 0.222 (0.33 to 1.0)	0.931 ± 0.162 (0.5 to 1.2)	$P < 0.05$

Table 2: Visual Acuity & Refractive data of patients undergoing CSL

The above data is presented in graphs in following figure.





Graph

Complications: No intra operative complication was noted in any eye. Sub conjunctival hemorrhage was noted intraoperatively. No postoperative complications were seen.

DISCUSSION: Performing laser ablation beneath the lamellar flap of corneal tissue preserves Bowman's layer and corneal epithelium. This approach to ablative surgery minimizes the risk of inadequate Residual Stromal Thickness (RST). The corneal flap is not thought to contribute to corneal strength. Therefore, adequate un-operated stroma must remain to maintain the corneal strength. It has also the advantages of LASIK i.e. very little pain, rapid visual recovery and early postoperative stability.

In our series of 17 eyes with mean SE of -9.479 ± 3.008 (SD); range -5.75 to -16.0D SE and mean astigmatism of -0.97 ± 1.208 (range -0.5 to -4.5) were treated with CSL – Cornea Sparing Lasik. In this, part of spherical correction and total cylindrical correction was done on posterior stroma so as not to cross 250 micron mark of RST while part of sphere was corrected on the undersurface of flap. 61.1% of eyes had postoperative UCVA 6/6 or better and all eyes (100%) had UCVA of 6/12 or better. This points out the efficacy with an index of 0.977. Five eyes (29.41%) had improvement in BCVA; one eye by 3 lines and 1 eye by 2 lines. While remaining 12 eyes maintained the preoperative BCVA, no eye had loss of 2 or more lines BCVA. Also the predictability was good as 88.23% eyes had SE with ± 1 D range of emmetropia. Stability was excellent as patients were followed up for mean 8 months. The safety index was found to be excellent i.e. 1.12.

In series by Versace P. et al⁵, cornea sparing lasik was done on 142 eyes with ablation of corneal flap and in some cases, also stromal bed for SE refraction errors ranging from -0.5 to -12.38 D. the procedure was performed as a primary treatment in 104 eyes, mean SE -6.75 D (range -3.25 to

ORIGINAL ARTICLE

-12.50 D), mean sphere -6.15D (range -1.75 to -12.0D) and mean astigmatism (+0.75 to -4.5D). In 32 eyes, initial enhancement was done, mean SE -1.22 D (range 0 to -4.38) mean sphere -1.03 D (range +0.25 to -4.0D) and mean astigmatism -0.38 D (range +1.50 to -1.25 D) while in 6 eyes, second enhancement was done. The mean SE was -0.2 +/- 0.47 D (SD) – range +0.87 to -2.35 D. Excluding eyes with mono vision, 97% eyes achieved UCVA of 6/12 or better and 64% had UCVA 6/6 or better. 96% eyes were within +/- 1.0 D of intended correction. The safety index was 1.02 and efficacy index of 0.8. The results of our study correlate well with this study though we studied small number of eyes.

In the study of Carlos A et al⁶ preoperatively, the spherical equivalent (SE) was -5.61 +/- 1.72 D, the cylinder was -1.78 +/- 1.24 D, and the best spectacle-corrected visual acuity (BSCVA) was 0.77 +/- 0.19. Difficulties and complications of the technique, efficacy and safety index, and aberrations were analyzed.

According to the surgical plan and our nomogram, diopters corrected on the flap were -1.73 +/- 1.08 and on the bed were -4.77 +/- 1.89. The mean follow-up was 8.28 +/- 2.19 months. At 6 months, the SE was -0.21 +/- 0.39, vectorial change was 1.69 +/- 0.74, and the BSCVA was 0.77 +/- 0.20. Postoperatively, no eye had an increase in refractive astigmatism. Uncorrected visual acuity was 20/40 or better in all cases (100%) and 20/25 or better in 13 cases (59.1%). Regarding gained and lost lines of BSCVA, 54.5% conserved the lines, 18.2% lost 1 line, 9.1% gained 1 line, and 18.2% gained 2 lines. Like in our study, simultaneous ablation on the flap and on the bed in cases of low pachymetry or topographical asymmetry was predictable, effective, and safe.

Miguel J et al⁷ studies forty-six eyes with a residual spherical equivalent refraction between -0.37 and -2.75 diopters (D) and astigmatism between 0.0 and -1.25 D. As per their study also, undersurface ablation of the flap retreatment appears to have less potential for changing the posterior corneal surface than conventional LASIK enhancement and can help reduce the likelihood of retreatment-induced keratectasia.⁹

Flap ablation offers a useful tool for refractive surgeon in patients with greater degrees of ametropia and /or thin corneas and in patients seeking enhancement who, after original procedure, have inadequate or unknown RST for a routine ablation. Flap ablation also allows treatment of patients having routine lasik in whom the flap measured before ablation with intraoperative pachymetry is thicker than predicted; leaving less posterior stroma for ablation than that calculated to preserve an adequate RST. In this situation part of ablation would be placed on the flap, optimizing RST.

Laser ablation on flap is not a difficult procedure. Use of flap support instrument facilitates flap positioning and control during ablation. Case must be taken to ensure adequate distance between flap hinge and ablation center. Slight decentration of the flap superiorly will increase this distance and assist in creating a smooth flap undersurface.

Registration of the ablation is potential source of error with ablation on the flap and it will be useful to document the higher order aberration on the flap and it will be useful to document the higher order aberration (Particularly vertical comma) resulting from this technique. The eye tracker is disabled and the ablation is aligned manually with center of pupil mark on the corneal epithelium. In practice this works and is not difficult. Limiting the treatment on flap to relatively small amount of sphere makes alignment less critical and use of flap treatment instrument acts an eye fixation ring; such as that used before eye tracking system came into common use.⁸

ORIGINAL ARTICLE

In primary treatment, typically 2 to 3 D of myopic sphere is ablated on flap, the remainder including cylinder on the posterior corneal stroma. The amount to be ablated on the flap is programmed before surgery. It is calculated with an assumed flap thickness data and leaving RST of at least 250 microns (ideally 275 microns). The final amount to be ablated on flap is modified if needed after keratectomy when actual flap thickness is known. Preferably all the cylindrical ablation is placed on the posterior stroma as alignment is more predictable.

Enhancement in cases in which the calculated RST is unknown and there is suspicion that it is less than 250 microns, is performed by planning the entire ablation on flap. The flap thickness is measured after the flap is lifted. If measured flap thickness minus the ablation will result in final thickness of < 80 microns, the treatment should be modified to place the ablation on posterior stroma or abandoned if there is significant risk of inadequate posterior stromal thickness.

The optical zone for the flap can be matched to posterior stromal ablation or standard 5.5 mm optical zone for flap ablation to reduce the depth of ablation and keep total treatment area of less than 9.0 mm. the Bausch and Lomb ablation nomogram creates the larger functional optical zone. With a programmed optical zone of 5.5 mm, the treatment will go beyond 8.5mm. a mismatch between the optical zone on the flap and posterior stroma seems to have no functional impact. This may be due to predominantly spherical ablation on the flap and the multi zone final profile for the total cornea.

Ablation on flap is ideal treatment for spherical myopia; but astigmatism can be corrected. The axis to be programmed for astigmatism has to be modified to allow reflection of the flap according to following formula:

Hinge Axis X 2 – 180 – photopter axis = axis for treatment.

A perfectly horizontal hinge is 180 degrees.

A potential complication of laser ablation of the flap is flap thinning. Thin flap have been associated with irregular astigmatism and flap wrinkling or folding. However other authors report that thin flap does not affect LASIK outcome.

LASIK is thought to weaken the mechanical strength of cornea by reducing the biomechanical effective thickness of cornea by the thickness of flap plus the keratectomy depth. This may arise from destruction of existing component and increased distensibility of corneal tissue with sliding of collagen fibres or collagen lamellae or combination of these mechanisms. Laser ablation on the flap aids in preservation of posterior stroma, minimizing disruption of corneal structure and thickness.

This may reduce the potential for keratectasia. Optimizing residual posterior stromal thickness may minimize biomechanical weakening.

CONCLUSION: This series suggest that the laser ablation on the corneal flap is safe and effective procedure. The refractive, efficacy and safety outcomes were similar to those in routine Lasik ablation on posterior stroma. Cornea sparing lasik is useful tool allowing surgeons to preserve the posterior stroma. The risk of keratectasia may be reducing through preservation of posterior corneal stroma. Consideration in the etiological factors in keratectasia may help us in further understanding the biomechanical properties of the cornea.

REFERENCES:

1. Trokel SL, Srinivasan R., Braren B: Excimer Laser surgery of cornea: Am. J. Ophthalmol 96:710-715.
2. Pallikaris IG, Katsanevalli VJ et al: LASIK intraoperative complications using one type of microkeratome: Ophthalmol: 2002: 109: 57-63 by American Academy of Ophthalmology.
3. Salz JJ: Radial Keratotomy versus photorefractive keratectomy: Color atlas text of Excimer Laser Surgery: The Cornea: Newyork, Igako-Shoin; 1993: 63-75.
4. Thompson KP, Waring GO: Photorefractive keratectomy: Contemporary refractive surgery, Ophthalmol Clin North Am: 1992: 5: 745-751.
5. Versace P1, Watson SL.: Cornea-sparing laser in situ keratomileusis: ablation on the flap:J Cataract Refract Surg. 2005 Jan;31(1):8-96.
6. Carlos Argento, María José Cosentino: Laser in situ keratomileusis: ablation on the flap and stromal bed in a primary treatment: Journal of Cataract and Refractive Surgery 05/2006; 32(4):590-4. 2.55.
7. Miguel J Maldonado, Juan C Nieto, Maite Díez-Cuenca, David P Piñero Posterior corneal curvature changes after under surface ablation of the flap and in-the-bed LASIK retreatment : Ophthalmology 07/2006; 113 (7): 1125-33.
8. S Taneri, D T Azar: Ablation on the undersurface of a LASIK flap. Instrument and method for continuous eye tracking: Der Ophthalmologe 03/2007; 104(2):132-6.
9. Jeroen J G Beerthuisen, Evelien Siebelt: Surface ablation after laser in situ keratomileusis: retreatment on the flap: Journal of Cataract and Refractive Surgery 09/2007; 33 (8): 1376-80.

AUTHORS:

1. Nikhilesh Wairagade
2. Vikas Mahatme
3. Atul Borkar
4. Sudha Sutaria
5. Chitra Pande

PARTICULARS OF CONTRIBUTORS:

1. Senior Consultant, Department of Ophthalmology, Mahatme Eye Bank Hospital, Nagpur, India.
2. Founder Medical Director, Department of Ophthalmology, Mahatme Eye Bank Hospital, Nagpur, India.
3. Consultant Ophthalmologist, Department of Ophthalmology, Mahatme Eye Bank Hospital, Nagpur, India.

FINANCIAL OR OTHER**COMPETING INTERESTS:** None

4. Professor and Senior Consultant, Department of Ophthalmology, Mahatme Eye Bank Hospital, Nagpur, India.
5. Senior Consultant, Department of Ophthalmology, Mahatme Eye Bank Hospital, Nagpur, India.

NAME ADDRESS EMAIL ID OF THE CORRESPONDING AUTHOR:

Dr. Vikas Mahatme,
C/o. Mahatme Eye Bank,
Eye Hospital, 16 Central Excise Colony,
Ring Road, Nagpur-440015, India.
E-mail: sm@mahatmehospital.com

Date of Submission: 09/02/2015.
Date of Peer Review: 10/02/2015.
Date of Acceptance: 23/02/2015.
Date of Publishing: 28/02/2015.