

# CASE REPORT

## PRIMARY OMENTAL HYDATID CYST – A RARE ENTITY

Prashant M. Anadinni<sup>1</sup>, Srinivas B. Kulkarni<sup>2</sup>, Sandeep Y. Chinnapur<sup>3</sup>

### HOW TO CITE THIS ARTICLE:

Prashant M. Anadinni, Srinivas B. Kulkarni, Sandeep Y. Chinnapur. "Primary omental hydatid cyst – A rare Entity". Journal of Evolution of Medical and Dental Sciences 2015; Vol. 4, Issue 70, August 31; Page: 12267-12269, DOI: 10.14260/jemds/2015/1770

**ABSTRACT:** Hydatid cyst is caused by the parasite *Echinococcus granulosus* (Larval form) in humans with lesions most frequently encountered in the liver and lungs. It can rarely involve extra-hepatic organs. Primary omental hydatid cyst is rare entity. This report presents the interesting case of a very large primary omental hydatid cyst.

**KEYWORDS:** Hydatid cyst, Primary omental Hydatid cyst.

**INTRODUCTION:** Hydatid disease is a parasitic infection caused by the larval form of *Echinococcus granulosus* in humans. It produces characteristic cystic lesions most frequently localized in the liver and lungs. Extra-hepatic involvement is rare. The disease is endemic in several regions of India. The omental hydatid cyst represents a very rare manifestation of the disease. It is usually secondary to the rupture of a liver or splenic cyst. Primary peritoneal cyst is extremely rare and should be differentiated from a mesenteric or duplication cyst.

**CASE REPORT:** A 38 years old male patient, agriculturist by occupation, presented with history of dull aching pain and mass per abdomen since 1 year. No other symptoms. No comorbid conditions. On examination vitals stable no pallor/icterus/lymphadenopathy. Per abdomen a 15x18cms, Intraperitoneal, Nontender, Mobile, Cystic mass with all margins noted in the center of the abdomen. USG abdomen and pelvis suggestive of 16x18cms solitary cystic lesion in the abdomen which had a well-defined wall with clear liquid (Figure 1). In view of this finding CECT abdomen and pelvis was done which revealed a well-defined cyst in the abdomen arising from omentum and measuring approximately 16x18cm with clear fluid inside and cholelithiasis. Liver, lungs, and other abdominal organs appeared to be normal. Patient's complete blood counts were normal except eosinophilia. Liver function and renal function tests were within normal limits.

After preoperative course of Albendazole therapy, patient was planned for exploratory laparotomy. On laparotomy a huge omental cyst with thick capsule noted which on opening had clear cyst fluid with multiple daughter cysts (Figure 2, 3). Carefully cyst fluid and daughter cysts extracted and capsule excised completely. Scolicidal betadine wash given, after careful examination of other abdominal viscera, laparotomy wound closed over a drain in situ. Post operatively patient recovery was uneventful with oral full diet and ambulation very next day and drain removal on 2<sup>nd</sup> day, discharged on 5<sup>th</sup> day, suture removal on 8<sup>th</sup> day from operation. Patient continued with albendazole treatment for 6 weeks to prevent recurrence as there was minimal spillage of cyst fluid intra operatively.

**DISCUSSION:** Hydatid cyst is caused by the parasite *Echinococcus granulosus*. The adult worm resides in Dog or Wolf's intestine (Definitive host). Definite host shed eggs in their stool which contaminate vegetables and fruits. These eggs are then ingested by the cattle or sheep (Intermediate host) during grazing in the fields. Humans are intermediate or accidental host. Humans are infected

## CASE REPORT

---

by eating contaminated vegetables or fruits. Hydatid cyst commonly affects liver and lungs. Primary omental hydatid cyst without liver and lung involvement is rare. Intraperitoneal hydatid disease is seen in about 3.9–12.5% of patients.<sup>(1,2)</sup> Differential diagnosis of the intra-abdominal cystic lesions arising from omentum includes mesenteric cyst, gastrointestinal duplication cyst, ovarian cysts, cystadenoma, and lymphangioma.

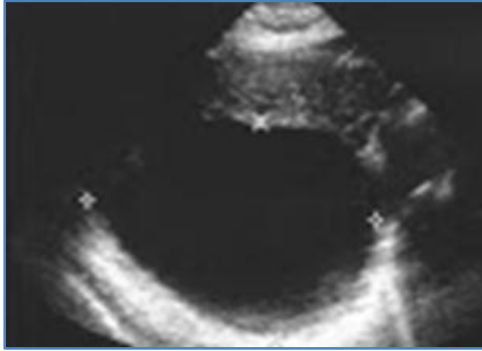
Ultrasonography of the abdomen is the initial imaging to identify the organ of origin and to characterize the cyst. However a contrast enhanced computed tomography is always required to confirm the diagnosis as well as to plan the therapy.<sup>(3)</sup> ELISA can be a good serological test for the confirmation of hydatid cyst with a sensitivity of 95–97%. Parasitic infestation may also present with asymptomatic rise in the eosinophil counts. Prompt treatment of these cysts is recommended as they are prone to complications like rupture, haemorrhage, infection, or torsion.<sup>(4)</sup> The ideal treatment for omental hydatid is controlled open surgical excision as there is a very high possibility of uncontrolled spillage and peritoneal dissemination of the disease leading to recurrence. <sup>(5,6)</sup> Laparoscopic cyst excision although technically difficult can be attempted with due risk of spillage if expertise for the same is available.<sup>(7)</sup> Albendazole therapy should be added to the treatment to prevent spillage and to avoid recurrence of the disease. Preoperative treatment with albendazole is effective in reducing the rate of recurrence.<sup>(8,9)</sup>

In conclusion, primary omental hydatid cyst can occur without affecting other viscera. Hydatid cyst should be kept as one of the differential diagnosis for any patient presenting with a cystic lump in the abdomen especially from endemic areas.

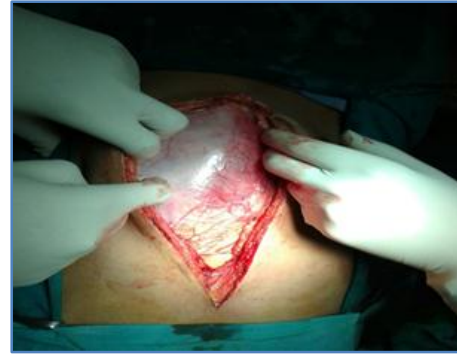### REFERENCES:

1. Sekmenli T, Koplay M, and Sezgin A. "Isolated omental hydatid cyst: clinical, radiologic, and pathologic findings," *Journal of Pediatric Surgery*, vol. 44, no. 5, pp. 1041–1043, 2009.
2. Sethi S. K, Patnaik S, Narayan, and Nayak S. N. "Isolated omental hydatid cyst- a case report," *Journal of the Indian Medical Association*, 2004;102(11);644–646.
3. A. T. Ilica, M. Kocaoglu, N. Zeybek et al., "Extrahepatic abdominal hydatid disease caused by *Echinococcus granulosus*: imaging findings," *American Journal of Roentgenology*, vol. 189, no. 2, pp. 337–343, 2007.
4. M. Uramatsu, Y. Saida, J. Nagao et al., "Omental cyst: report of a case," *Surgery Today*, vol. 31, no. 12, pp. 1104–1106, 2001.
5. K. J. Rathod, S. Lyndogh, R. P. Kanojia, and K. L. Rao, "Multiple primary omental hydatid: rare site for a common infestation," *Tropical Gastroenterology*, vol. 32, no. 2, pp. 134–136, 2011.
6. D. Filippou, D. Tselepis, G. Filippou, and V. Papadopoulos, "Advances in Liver Echinococcosis: diagnosis and Treatment," *Clinical Gastroenterology and Hepatology*, vol. 5, no. 2, pp. 152–159, 2007.
7. A. Bickel, N. Loberant, J. Singer-Jordan, M. Goldfeld, G. Daud, and A. Eitan, "The laparoscopic approach to abdominal hydatid cysts: a prospective nonselective study using the isolated hypobaric technique," *Archives of Surgery*, vol. 136, no. 7, pp. 789–795, 2001.
8. Daali M, Hssaida R, Zoubir M, Hada A, Hajji A. Peritoneal hydatidosis: a study of 25 cases in Morocco. *Snate*. 2000; 10(4):255–260.
9. De U. Rare primary extrahepatic intra-abdominal hydatid cysts. *Trop Doct*. 2009;39(3): 172–175.

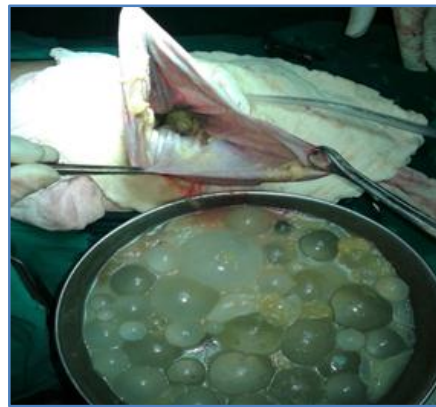
## CASE REPORT



**Fig. 1**



**Fig. 2**



**Fig. 3**

### **AUTHORS:**

1. Prashant M. Anadinni
2. Srinivas B. Kulkarni
3. Sandeep Y. Chinnapur

### **PARTICULARS OF CONTRIBUTORS:**

1. Assistant Professor, Department of General Surgery, Raja Rajeswari Medical College and Hospital Bengaluru.
2. Assistant Professor, Department of General Surgery, Raja Rajeswari Medical College and Hospital Bengaluru.

### **FINANCIAL OR OTHER**

**COMPETING INTERESTS:** None

3. Assistant Professor, Department of General Surgery, Raja Rajeswari Medical College and Hospital Bengaluru.

### **NAME ADDRESS EMAIL ID OF THE CORRESPONDING AUTHOR:**

Dr. Prashant M. Anadinni,  
#50, S1, 2<sup>nd</sup> Cross, 1<sup>st</sup> Main,  
Chamarajpet,  
Bengaluru-560018.  
E-mail: doc.prashant73@gmail.com

Date of Submission: 14/08/2015.  
Date of Peer Review: 17/08/2015.  
Date of Acceptance: 27/08/2015.  
Date of Publishing: 31/08/2015.