

**A STUDY OF FUNCTIONAL OUTCOME OF INTRA-ARTICULAR CALCANEAL FRACTURES TREATED SURGICALLY**

V. Prashanth<sup>1</sup>, Ananthula Krishna Reddy<sup>2</sup>, Ashok Ohatker<sup>3</sup>, M. C. Vinod Kumar Reddy<sup>4</sup>, Siddhartha<sup>5</sup>, B. Sudheer Kumar<sup>6</sup>, B. Sridhar<sup>7</sup>

**HOW TO CITE THIS ARTICLE:**

V. Prashanth, Ananthula Krishna Reddy, Ashok Ohatker, M. C. Vinod Kumar Reddy, Siddhartha, B. Sudheer Kumar, B. Sridhar. "A Study of Functional Out Come of Intra-Articular Calcaneal Fractures Treated Surgically". Journal of Evolution of Medical and Dental Sciences 2015; Vol. 4, Issue 82, October 12; Page: 14360-14365, DOI: 10.14260/jemds/2015/2042

**ABSTRACT:** The calcaneus (Oscalcis) is the largest and most often fractured tarsal bone. The treatment of calcaneal fractures continues to pose a challenge for the trauma surgeons despite advancement in surgical technique and implant devices. The prognosis for an extra-articular fracture is uniformly good, but that for an intra-articular fracture is varied. The management of every aspect of intra-articular calcaneal fractures is controversial. Although some studies have demonstrated good results after open reduction and internal fixation of intra-articular calcaneal fractures, a few other studies say otherwise. The method of internal fixation is also a point of debate, with various proponents advocating fixation with pins, screws or plate fixation with screws. Even there is no consensus regarding the surgical approach, with many having been described, including medial, lateral, combined medial and lateral, extended lateral and sinus tarsi approaches. So it is the need of the hour, to identify treatment techniques, which use lesser hardware, to provide better functional outcomes in terms of shorter duration of treatment, better stability and early weight bearing and so also the role of non-operative treatment in the calcaneal fracture management. In this study, we have attempted to evaluate the results of calcaneal fracture management by open reduction and internal fixation. Ours is a prospective study centered in the Gandhi hospital from Nov 2012 to April 2014 in which 30 patients with intra-articular calcaneal fractures were treated by open reduction and internal fixation and the results were evaluated with AOFAS scoring system. In our analysis, we observed that an anatomical reduction to restore Bohler's and Gissanes angles associated with rigid internal fixation is essential for better functional results.

**KEYWORDS:** Calcaneum, Intra-articular fracture; Surgical fixation.

**INTRODUCTION:** The calcaneum (Os calcis) is the largest and most often fractured tarsal bone. It is the major weight bearing osseous structure of the foot and is one of the components of the tri-tarsal articulation and has important functional tasks with regard to ambulation. With a bone so vital to the normal mechanics of locomotion, it is easy to see why a fracture of calcaneum is attended by considerable morbidity.

Calcaneum fractures account for approximately 2% of all fractures. These fractures can be classified broadly into intra-articular and extra-articular types, with the intra-articular variant being more common, representing 70-75% of all these fractures frequently resulting from axial loading with varying degrees of shear force.

The treatment of calcaneum fractures continues to pose a challenge for the trauma surgeons, despite advancement in surgical technique and implant devices. The primary source of disagreement has been whether better results are achieved with operative or non-operative treatment. Operative

## ORIGINAL ARTICLE

treatment methods include open reduction and internal fixation, percutaneous fixation and primary arthrodesis.

Because of its unique shape, difficulties arose in understanding the geometry of the calcaneal fractures. Over the last two decades, however, marked advances in imaging technology have allowed a better understanding of fracture geometry and provided the basis for newer classifications, which has revolutionized the treatment of calcaneal fractures.<sup>1</sup>

**MATERIALS AND METHODS:** The present study includes 30 patients of intra-articular calcaneal fractures treated with open reduction and internal fixation with various implants in Gandhi hospital, from Nov 2009 to April 2014. We excluded patients below 18 yrs. and above 70 yrs. of age, fractures presenting late (More than 3 weeks), medically unfit patients and patients with associated fractures from our study.

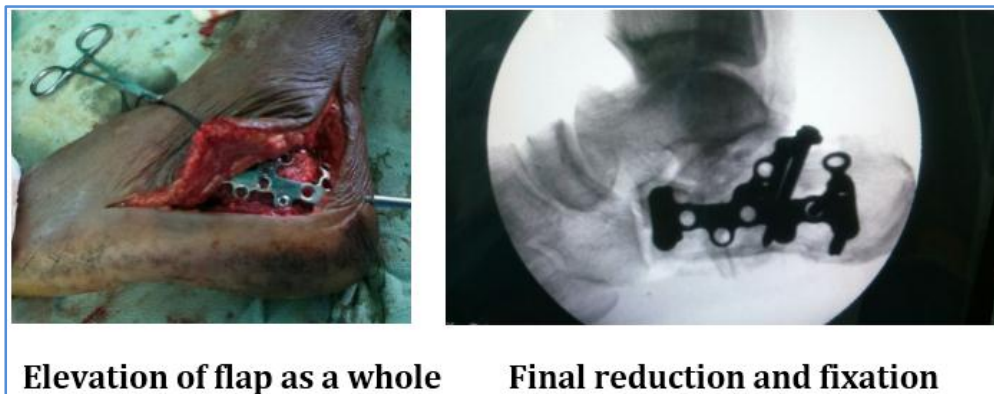
The mode of injury for 21 patients was fall from height and for 9 patients it was RTA. Out of 30 patients 18 had right calcaneal fractures and remaining had left side injuries.

All the fractures were joint depression type of Essex-Lopresti.<sup>2</sup> and 13 patients having type II and 17 patients having type III fractures according to Sanders' classification.

Patients were taken up for surgery only after the swelling subsided, which was indicated by the appearance of wrinkles, for appropriate wound closure and to avoid the complication of wound dehiscence. The number of days from the time of injury to surgery varied from 1- 20 days.

| Sl. No. | DURATION B/W FALL AND SURGERY | NO OF FRACTURES |
|---------|-------------------------------|-----------------|
| 1       | 0-5 days                      | 8               |
| 2       | 6-10 days                     | 8               |
| 3       | 11-15 days                    | 12              |
| 4       | 16- 20 day5                   | 2               |

All the patients were operated under spinal anesthesia with the patient in lateral position, through lateral extensile approach. Through a L-shaped incision, on the lateral surface of the heel, the calcaneal fracture should be exposed. Great care must be taken to raise the skin and underlying soft tissues as a single flap over the bone. Sural nerve must be protected. In the reduction of fractured fragments, the sustentacular fragment should be reduced first with the help of a schanz pin, by applying traction and translation medially. Then the subtalar joint should be visualized by elevating the lateral fragment. A definitive fixation can be taken up with contoured plates easily, once the reduced fragments are held with k-wires.



## ORIGINAL ARTICLE

---

**FOLLOW UP:** The patients were followed up clinically and radiologically at 6 weeks, 12 weeks, 6 months, and 1 year intervals, with respect to the height and width of the calcaneum, range of movements at subtalar joint and tubero-talar angles.

**RESULTS:** In our study, 63% patients were in the age group of 18-40 years with mean age of 38.06 years. 21 patients were male and 9 were female patients. Out of 30 patients, 28(93%) cases were operated within 2 weeks of injury and 2 (7%) in the 3<sup>rd</sup> week.

Post-operatively, the patients had a satisfactory increase in the Bohler's angle and decrease in the gissane's angle. The mean pre op Bohler's angle was 11.76 and gissane's angle was 126.9. The mean Post op Bohler's angle was 26.30 and Gissane's angle was 119.76.

Post operatively all patients had an increase in heel height and decrease in heel width. The mean pre op heel height was 5.93 and heel width was 6.83. The mean Post op heel height was 6.38 and heel width was 6.27.

At 12 weeks of follow up, X-rays of 26 out of 30 fractures showed radiological signs of union. We had 4 cases of delayed union (More than 16 weeks). Mean duration of radiological union was 13.38 weeks.

One patient developed deep infection which was managed by implant removal and in 3 cases superficial infection was noted.

The functional outcome was measured by the "American Orthopaedic Foot and Ankle Society (AOFAS) Ankle Hindfoot scoring system" at twelve months.

Out of the 30, 10 had excellent results, 16 had good results, 3 had fair results and 1 had poor result.

**DISCUSSION:** The calcaneum is the most commonly fractured tarsal bone. The prognosis for an extra-articular fracture is uniformly good, but that for an intra-articular fracture is varied. The management of every aspect of intra-articular calcaneal fractures is controversial. Although some studies have demonstrated good results after open reduction and internal fixation of intra-articular calcaneal fractures.<sup>3-5</sup> the best choice of treatment remains controversial because a few other studies say otherwise.<sup>6-7</sup> Further, the method of internal fixation remains a point of debate, with various proponents advocating fixation with pins, screws or plate fixation with screws. There are many methods of stabilization of calcaneum fractures, each having their own merits and demerits. Even there is no consensus regarding the surgical approach, with many having been described, including medial, lateral, combined medial and lateral, extended lateral and sinus tarsi approaches.

A lateral extensile exposure popularized by Benirschke and Sangeorzan was used in all our cases. We used various fixation devices like reconstruction plates,<sup>8</sup> calcaneal plates,<sup>9</sup> K-wires and screws.<sup>10</sup> for fixing these fractures.

Surgical treatment is associated with complications like wound dehiscence and sepsis.<sup>11</sup> However, conservative treatment is not without its complications like subtalar joint pain heel varus, peroneal tendon impingment etc.<sup>12</sup>

In Sanders study, excellent or good results were obtained in 73% of type-II, 70%of type-III, and only 27% of type IV fractures.<sup>13</sup> In our study, 87% of patients had excellent to good and 13%had fair to poor results.

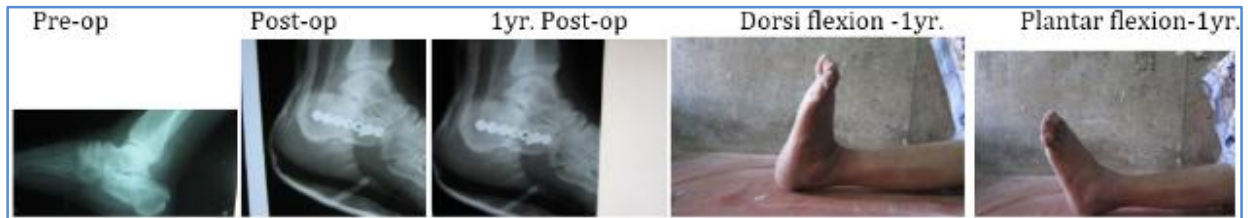In our analysis, we confirmed correlation between the Bohler's and Gissanes angles.<sup>14</sup> and the functional outcome, as proved and verified by a lot of other studies.

## ORIGINAL ARTICLE

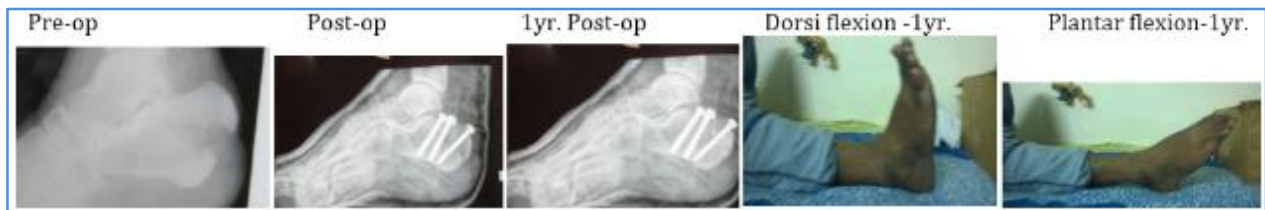Hence an anatomical reduction to restore these angles and rigid internal fixation with an appropriate implant is the key to get good functional results.

There were certain limitations to our study. A study involving more patients followed up for a longer period of time can more accurately define the functional outcome of calcaneal fractures treated surgically.

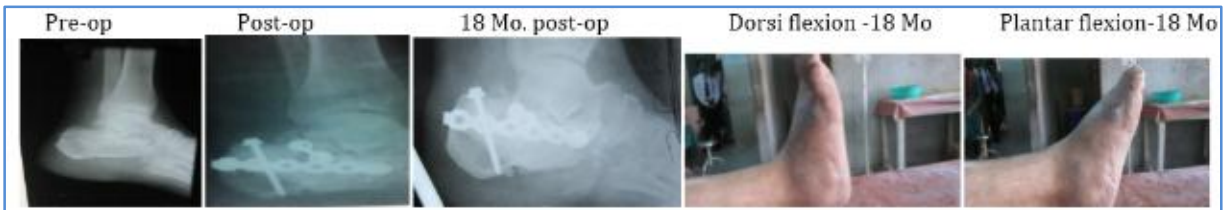### Case 1:



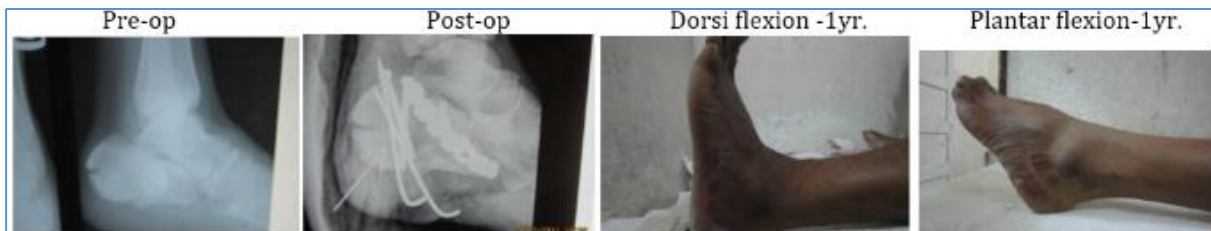### Case 2:



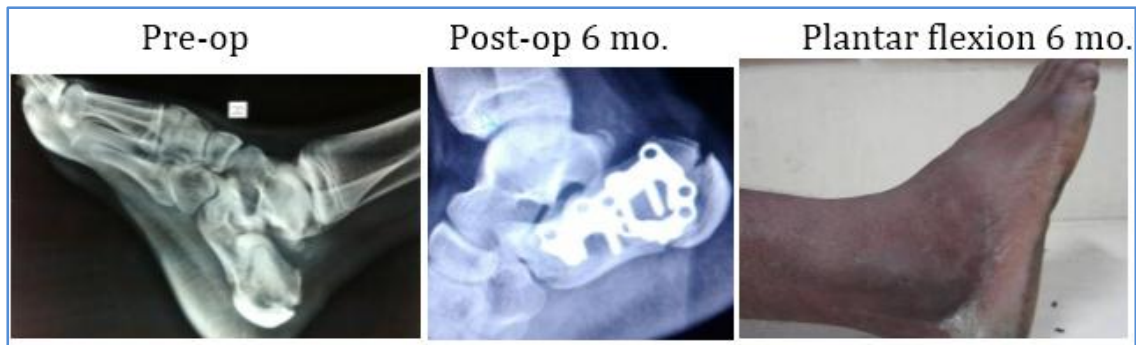### Case 3:



### Case 4:



## Case 5:

**BIBLIOGRAPHY:**

1. Koval K, Sanders R. the radiologic evaluation of calcaneal fractures. *Clin Orthop* 1993; 290:41-58.
2. Essex Lopresti P. The mechanism, reduction technique and results in fractures of the os calcis. *Br J Surg* 1952; 39:395-419.
3. Sanders R, Fortin P, DiPasquale T, Walling A. Operative treatment in 120 displaced intraarticular calcaneal fractures. Results using a prognostic computed tomography scan classification. *Clin Orthop Relat Res.* 1993 May; (290):87-95.
4. Zwipp, Hans, Tscherne, Harald, Thermann, Hajo, Weber, Theresa. Osteosynthesis of Displaced Intraarticular Fractures of the Calcaneus Results in 123 Cases. *Clin Orthop* 1993; 290:76-86.
5. Jean-Luc Besse, J.P. Avaro, F. Chotel, J.L. Lerat, B. Moyen. Calcaneal intraarticular fracture osteosynthesis: Clinical and radiological prospective study of 31 cases. *Foot and Ankle Surgery* Dec 2006; 19-27.
6. Thordarson DB, Krieger LE. Operative vs. non-operative treatment of intraarticular fractures of the calcaneus: a prospective randomized trial. *Foot Ankle Int.* 1996; 17:2-9.
7. Parmar HV, Triffitt PD, Gregg P J. Intra-articular fractures of the calcaneum treated operatively or conservatively. A prospective study. *J Bone Joint Surg Br.*
8. Barei DP, Bellabarba C, Sangeorzan BJ, Benirschke SK. Fracture of the Calcaneus. *OCNA.* 2002; 33 (I): 263-85.
9. Muller ME, Allgower M, Schneider R. *Manual of Internal Fixation. Techniques recommended by AO Group.* 2nd edition. New York: Springer; 979. P. 71-87.
10. Palmer 1. The mechanism and treatment of fractures of the calcaneus. Open reduction with the use of cancellous grafts. *JBJS (A).* 1948; 30:2-8.
11. Lindsay R, Dewar F, Fracture of the os Calcis. *Am J Surg* 1958; 95:555-76.
12. Myerson M, Quill GE. Late complications of fractures of the calcaneus. *IBJS (A).* 1993; 75(3):z31-41.
13. V Jain, R Kumar, DK Mandal. Osteosynthesis for intra-articular calcaneal fractures. *Journal of Orthopaedic Surgery* 2007; 15(2):144-8.
14. HARDING, David M.D, Waddell, James P. M.D., F.R.C.S open reduction in diplaced fractures of os calcis;; clinical orthopaedics and related reaserch October 1985.

## ORIGINAL ARTICLE

---

### **AUTHORS:**

1. V. Prashanth
2. Ananthula Krishna Reddy
3. Ashok Ohatker
4. M. C. Vinod Kumar Reddy
5. Siddhartha
6. B. Sudheer Kumar
7. B. Sridhar

### **PARTICULARS OF CONTRIBUTORS:**

1. Associate Professor, Department of Orthopedics, GMC, Hyderabad.
2. Assistant Professor, Department of Orthopedics, GMC, Hyderabad.
3. Professor, Department of Orthopedics, GMC, Hyderabad.
4. Senior Resident, Gandhi Hospital, Secunderabad.

### **FINANCIAL OR OTHER**

**COMPETING INTERESTS:** None

5. Senior Resident, Gandhi Hospital, Secunderabad.
6. Assistant Professor, Department of Orthopedics, GMC, Hyderabad.
7. Senior Resident, Gandhi Hospital, Secunderabad.

### **NAME ADDRESS EMAIL ID OF THE CORRESPONDING AUTHOR:**

Dr. V. Prashanth,  
H. No. 1-1-148, Flat-102,  
BR Residency, SP Road,  
Secunderabad-500003.  
E-mail: drvprashanth@gmail.com

Date of Submission: 21/09/2015.  
Date of Peer Review: 22/09/2015.  
Date of Acceptance: 05/10/2015.  
Date of Publishing: 10/10/2015.