

**HEARING OUTCOME IN CANAL WALL DOWN MASTOIDECTOMY WITH TYMPANOPLASTY**B. Y. Praveen Kumar<sup>1</sup>, K. M. Govinde Gowda<sup>2</sup>, M. K. Veena Pani<sup>3</sup>, Thanzeemunisa<sup>4</sup>**HOW TO CITE THIS ARTICLE:**

B. Y. Praveen Kumar, K. M. Govinde Gowda, M. K. Veena Pani, Thanzeemunisa. "Hearing Outcome in Canal Wall Down Mastoidectomy with Tympanoplasty". Journal of Evolution of Medical and Dental Sciences 2015; Vol. 4, Issue 32, April 20; Page: 5512-5517, DOI: 10.14260/jemds/2015/806

**ABSTRACT: CONTEXT:** Tympanomastoid cholesteatoma destroys the tympanic membrane and ossicles resulting in a conductive hearing loss. A canal wall down mastoidectomy with tympanoplasty is performed for disease removal and correction of deafness. This surgery is technically challenging and results depend upon a number of factors like eustachian tube function, severity of middle ear pathology, status of remnant ossicular chain, reconstruction technique employed and post-operative healing. **AIM:** To compare the pre-operative versus post-operative hearing in patients undergoing canal wall down mastoidectomy with tympanoplasty. **SETTING AND DESIGN:** Prospective study conducted at a tertiary referral institution. **MATERIALS AND METHODS:** Sixty six patients with chronic suppurative otitis media with cholesteatoma underwent a canal wall down mastoidectomy with tympanoplasty. Preoperative and postoperative airborne gaps were compared. **RESULTS:** The preoperative mean air bone gap was 38.10 dB and the post-operative mean air bone gap was 29.30 dB with a gain of 8.8 dB. **CONCLUSION:** Canal wall down mastoidectomy with tympanoplasty is a good surgical procedure to augment the patients hearing to acceptable social levels.

**KEYWORDS:** Canal wall down mastoidectomy, Tympanoplasty, Pure tone audiometry, Air bone gap.

**INTRODUCTION:** Chronic otitis media with cholesteatoma is a common disease of the middle ear cleft characterized by chronic otorrhoea and hearing loss. The drum head and ossicles of these patients are destroyed by the disease process resulting in conductive hearing loss, which is a disability causing communication problem. This condition is surgically treated by a canal wall down mastoidectomy with tympanoplasty wherein disease is eradicated from the middle ear and mastoid with reconstruction of the hearing mechanism. Tympanoplasty is a difficult operation with variable results. Patients who have undergone a tympanoplasty must be diligently followed up to validate hearing improvement. Patients with tympanoplasty failure should be carefully examined for causes which should be addressed during a revision procedure.

**MATERIALS AND METHODS:** This study is a prospective study conducted on 66 patients at the department of ENT, Mysore medical college and research institute, Mysore, between 1/3/2008 and 30/6/2014 (6 years and 4 months).

**AIM OF THE STUDY:** To compare the pre-operative versus post-operative hearing status in patients undergoing canal wall down mastoidectomy with tympanoplasty.

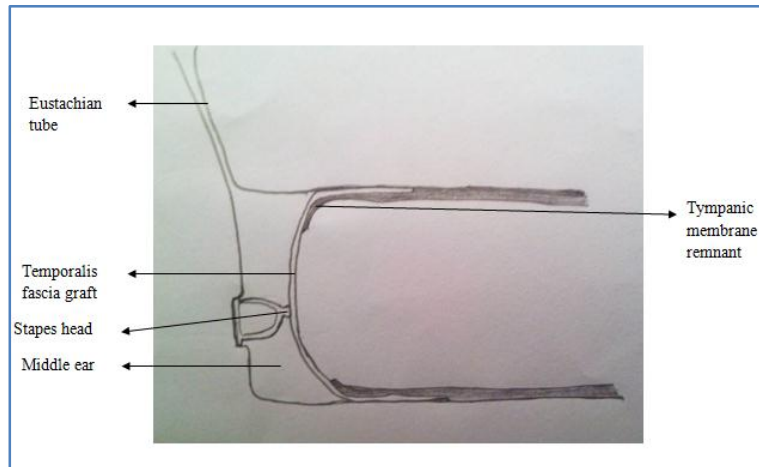
**Inclusion Criteria:** Patients with chronic otitis media with cholesteatoma involving the middle ear and mastoid who will require a canal wall down mastoidectomy with tympanoplasty.

## Exclusion Criteria:

1. Patients with residual or recurrent cholesteatoma.
2. Patients with a history of trauma to the ear or temporal bone.
3. Patients with complications of otitis media.

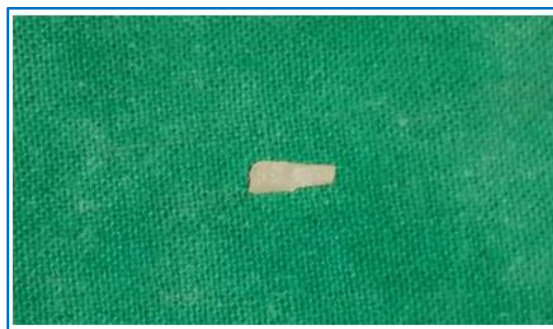Patients who were enrolled into the study were thoroughly examined. A complete ENT examination was performed. The involved ear was examined using an ear endoscope and microscope and the findings were recorded. A pure tone audiometry was performed, pure tone thresholds and air bone gap (ABG) in the speech frequencies was determined.

'A canal wall down mastoidectomy with tympanoplasty was performed,<sup>(1)</sup> cholesteatoma in the middle ear and mastoid was excised. The ossicular chain was inspected and reconstruction was performed depending on the status of the ossicular chain. If the stapes suprastructure was intact, a type 3 tympanoplasty<sup>(2,3)</sup> was performed. The temporalis fascia graft was placed on the stapes head (Fig. 1) and the tympanomeatal flap was replaced over the temporalis fascia graft.



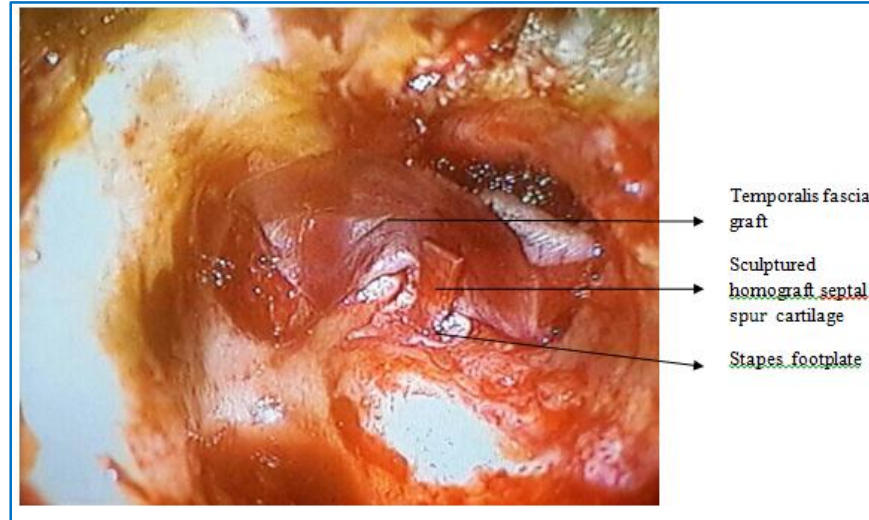
**Fig. 1: A Type 3 tympanoplasty**

When the stapes arch was destroyed by disease, a long columella ossiculoplasty was done. Homograft septal spur cartilage was sculptured as a long columella (Fig. 2) placed on the stapes footplate and stabilized by gelfoam.<sup>(4)</sup> The temporalis fascia graft was then placed on the lateral end of the columella (Fig. 3).



**Fig. 2: Homograft septal spur cartilage sculptured as a long columella**

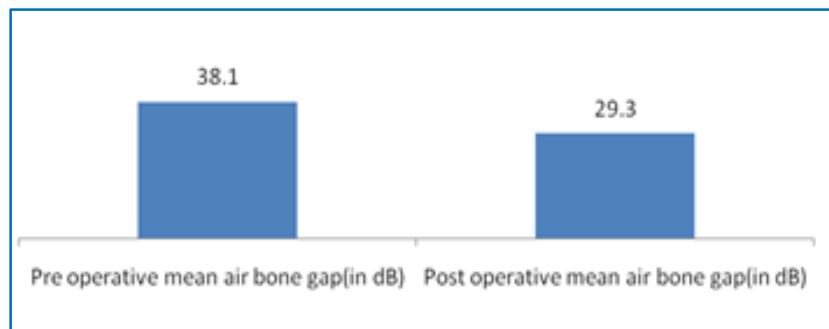
## ORIGINAL ARTICLE



**Fig. 3: Intra operative photograph of long columella ossiculoplasty**

Gelfoam impregnated with antibiotic ear drops were placed over the fascia graft and the mastoid cavity was packed with ribbon gauze smeared in antibiotic ointment. Post operatively the pack in the ear was removed after two weeks and standard dry ear precautions were advised. Antibiotic ear drops were instilled for three weeks after pack removal. A pure tone audiometry was done six months after surgery in all patients when the ear had completely healed. Post-operative air bone gap in the speech frequencies were recorded. All the above data was recorded in a predesigned proforma and analysed.

**RESULTS:** Sixty six patients were enrolled into the study. There were 38 males and 28 females with a male to female ratio of 1.35:1. The age ranged from 7 years to 48 years with a mean age of 23, 25 years. Thirty patients underwent canal wall down mastoidectomy with type 3 tympanoplasty. Canal wall down mastoidectomy with tympanoplasty using homograft septal spur cartilage as long columella was done in 36 patients. The hearing results were as follows. The preoperative mean air bone gap was 38.10 dB and the post-operative mean air bone gap was 29.30 dB with a gain of 8.8 dB (Fig. 4).



**Fig. 4: Preoperative and postoperative mean air bone gap**

## ORIGINAL ARTICLE

---

**DISCUSSION:** Otologists in the early part of the twentieth century were pre occupied in treating aural suppuration and complications caused by it. Surgical correction of deafness was not a priority in those days. The scenario slowly changed when Nysten in 1921 discovered the monocular operative microscope.<sup>(5)</sup> A year later in 1922, Holmgren invented the binocular operating microscope. This major technological advancement led to good visualization of the middle ear and mastoid structures enabling surgeons to define the anatomy better.

The discovery of Penicillin by Alexander Fleming in 1928 and Sulfonamides by Domagk in 1932 and their use in the treatment of middle ear infections and its complications led to a drastic fall in the incidence of complications. Surgeons could now direct their attention towards the treatment of hearing loss due to chronic ear disease. Wullstein<sup>(6)</sup> and Zollner<sup>(7)</sup> of Germany in 1953 described the tympanoplasty operation for the treatment of chronic otitis media. Tympanoplasty can be defined as a procedure to eradicate disease in the middle ear and to reconstruct the hearing mechanism with or without tympanic membrane grafting.<sup>(8)</sup>

Tympanoplasty hence involves repair of the tympanic membrane defect and reconstruction of the damaged ossicular chain. Connective tissue like vein,<sup>(9)</sup> temporalis fascia,<sup>(10)</sup> tragal perichondrium and sliced tragal cartilage have been used for closing tympanic membrane perforations. Temporalis fascia is the most popular graft material used by otologists. The fascia is placed medial to the tympanic membrane remnant which is called the underlay technique. Cholesteatoma of the middle ear will destroy the ossicular chain in most patients. Material like Autologous ossicles/cartilage,<sup>(11,12)</sup> Homograft ossicles/cartilage,<sup>(13,14)</sup> biomaterials like High density polyethylene sponge,<sup>(15)</sup> hydroxylapatite,<sup>(16)</sup> glass ionomer cement,<sup>(17)</sup> and titanium<sup>(18)</sup> have been used to reconstruct the damaged ossicular chain.

Austin<sup>(19)</sup> in a landmark paper classified ossicular defects depending upon the presence /absence of the malleus handle and stapes superstructure into four types.

Type A (M+ S+), Type B (M+, S-), Type C (M -, S+) and Type D (M -, S-). In types A and C when the stapes superstructure is present the partial ossicular replacement prosthesis (PORP) is placed between the stapes head and tympanic membrane. In a type B and D situation when only the stapes foot plate is present, a total ossicular replacement prosthesis (TORP) is placed between the foot plate and tympanic membrane. After a tympanoplasty is preformed and the ear is healed, patients must be evaluated clinically to determine graft take. Pure tone audiometry must be done and air bone gap closure after surgery must be estimated.

In our study the pre-operative mean air bone gap was 38. 10 dB, post-operative mean air bone gap was 29.30 dB with a gain of 8.8 dB. Shrestha<sup>(20)</sup> in 2008 performed a similar study. The pre-operative mean air bone gap was 37.8 dB and post-operative mean air bone gap was 29.8 dB with a gain of 8 dB. The results of our study are similar to the study conducted by Shrestha. Kabdwals<sup>(21)</sup> study performed recently in 2014 showed near similar results. The preoperative mean air bone gap was 35.63 dB, post-operative mean air bone gap was 29. 54 dB with an air bone gap closure of 6.09 dB (Table 1).

## ORIGINAL ARTICLE

	<b>Pre-operative mean air bone gap</b>	<b>Post-operative mean air bone gap</b>	<b>Gain</b>
Shrestha (2008)	37.8 dB	29.8dB	8dB
Kabdwal (2014)	35.63dB	29.54dB	6.09dB
Present study	38.10dB	29.30dB	8.8dB

**Table 1: Comparison of air bone gaps**

**CONCLUSION:** Canal wall down mastoidectomy with tympanoplasty is a good surgical procedure for chronic otitis media with cholesteatoma. A modest closure of the air bone gap can be expected helping the patient to achieve acceptable social hearing levels.

### REFERENCES:

1. Kveton JF. Open cavity mastoid operations. In: Gulya AJ, Minor LB, Poe DS, editors. *Surgery of the Ear*. PMPH-USA; 2010. P. 515.
2. Zollner F. Radikal – Operation mit besonderem Bezug auf die Horfunktion. *Ztschr Laryngol Rhinol Otol*. 1951; 30: 104.
3. Wullstein H. Funktionelle Operationen in Mittelohr mit Hilfe des freien Spaltlappen – Transplantates. *Arch Ohren – Nasen Kehlkopfh*. 1952; 161: 422.
4. Jansen C. Cartilage tympanoplasty. *Laryngoscope*. 1963; 73: 1288 – 1302.
5. Nylen CO. The microscope in aural surgery, its first use and later development. *Acta Otolaryngol Suppl (Stockh)*. 1954; 116: 226-40.
6. Wullstein H. Technic and early results of tympanoplasty. *Monatsschr Ohrenheilkd Laryngorhinol*. 1953; 87 (4): 308-11.
7. Zollner F. Surgical technics for the improvement of sound conduction after radical operation. *Arch Ital Otol Rinol Laringol*. 1953; 64 (4): 455-68.
8. Committee on Conservation of Hearing, American Academy of Ophthalmology and Otolaryngology. Standard classification for surgery of chronic ear disease. *Arch Otol*. 1965; 81: 204.
9. Shea JJ Jr. Vein graft closure of eardrum perforations. *J Laryngol Otol*. 1960; 74: 358-62.
10. Heermann H. Tympanoplasty with fascial tissue taken from the temporal muscle after straightening the anterior wall of the auditory meatus. *HNO*. 1961; 9: 136-7.
11. Hall A, Rytzner C. Auto transplantation of ossicles: Stapedectomy and biological reconstruction of the ossicular chain mechanism. *Archives of Otolaryngology*. 1961; 74: 42-46.
12. Utech H. Better final hearing after tympanoplasty. Modification of the method. *Zeitschrift fur Laryngologie, Rhinologie, Otologie*. 1960; 39: 367-371.
13. House WF, Patterson ME, Linthicum FH. Incus homografts in chronic ear surgery. *Archives of otolaryngology*. 1966; 84: 148-153.
14. Jansen C. Cartilage tympanoplasty. *Laryngoscope*. 1963; 73: 1288-1302.
15. Shea J. J. Plastipore total ossicular replacement prosthesis. *Laryngoscope*. 1976; 86: 239-240.
16. Grote. JJ. Biomaterials in otology. *Proceedings of the first International symposium*. 1983. Leiden. The Netherlands: Martinus Nijhoff Publishers.

## ORIGINAL ARTICLE

17. Zollner F. Radical operations with special reference to auditory function. *Z Laryngol Rhinol Otol.* 1951; 30 (3): 104-111.
18. Storrs LA. Temporalis muscle fascia and denatured fat grafts in middle ear surgery. *Laryngoscope.* 1963; 73: 699-701.
19. Chole R, Sudhoff H. Chronic otitis media, mastoiditis and petrositis. In: Cummings CW, Flint PW, Harker LA, et al., editors. *Cummings otolaryngology – head and neck surgery Philadelphia, PA: Elsevier Mosby; 2005. P. 2988-3012.*
20. Shrestha BL, Bhusal CL, Bhattarai H. Comparison of pre and post-operative hearing results in canal wall down mastoidectomy with type III tympanoplasty. *JNMA.* 2008; 47: 224-7.
21. Kabdwal N, Varshney S, Bist SS et al. Pre and postoperative evaluation of hearing in chronic suppurative otitis media. *Indian journal of otology.* 2014; 19: 164-168.

### AUTHORS:

1. B. Y. Praveen Kumar
2. K. M. Govinde Gowda
3. M. K. Veena Pani
4. Thanzeemunisa

### PARTICULARS OF CONTRIBUTORS:

1. Assistant Professor, Department of ENT, Mysore Medical College & Research Institute, Mysore.
2. Professor & HOD, Department of ENT, Mysore Medical College & Research Institute, Mysore.
3. Professor, Department of ENT, Mysore Medical College & Research Institute, Mysore.

### FINANCIAL OR OTHER

**COMPETING INTERESTS:** None

4. Junior Resident, Department of ENT, Mysore Medical College & Research Institute, Mysore.

### NAME ADDRESS EMAIL ID OF THE CORRESPONDING AUTHOR:

Dr. B. Y. Praveen Kumar,  
# 11829, 4<sup>th</sup> Stage,  
2<sup>nd</sup> Phase Vijayanagar,  
Mysore-570017.  
E-mail: entpraveen@yahoo.co.in

Date of Submission: 23/03/2015.  
Date of Peer Review: 24/03/2015.  
Date of Acceptance: 08/04/2015.  
Date of Publishing: 20/04/2015.