

ACCURACY OF MRI IN DIAGNOSING THE INTERNAL DERANGEMENT OF KNEE JOINT WITH ARTHROSCOPY AS REFERENCE STANDARDRajesh Kumar V¹, Vasu C. K², Pavithran V. K³, Navas K. M⁴, Fathima J⁵**HOW TO CITE THIS ARTICLE:**

Rajesh Kumar V, Vasu C. K, Pavithran V. K, Navas K. M, Fathima J. "Accuracy of MRI in Diagnosing the Internal Derangement of Knee Joint with Arthroscopy as Reference Standard". Journal of Evolution of Medical and Dental Sciences 2015; Vol. 4, Issue 47, June 11; Page: 8200-8208, DOI: 10.14260/jemds/2015/1187

ABSTRACT: The aim of this study is to assess the accuracy of MRI knee joint in diagnosing the internal derangement of knee with arthroscopy as reference standard. Internal derangement of knee refers to a group of disorder involving disruption of the normal functioning of the ligaments or menisci of knee joint. It can be traumatic or degenerative. MRI is most commonly indicated in patients with suspected injuries of the menisci and ligaments. This prospective study was done in the department of radiodiagnosis, KMCT medical college. In this study 150 patients suspected to have internal derangement of knee were included. MRI knee and arthroscopy were done in all cases. MRI had a diagnostic accuracy of 88% in ACL injuries, 93% in PCL injuries, 88% in medial meniscal injuries and 91% in lateral meniscal injuries. MRI is highly accurate in diagnosis of ligament and meniscal injuries and it can replace diagnostic arthroscopy in patients with internal derangement of knee.

KEYWORDS: MRI knee joint, internal derangement of knee, arthroscopy, ligaments, meniscus.

INTRODUCTION: Knee joint is the largest and complex joint of the body and also most commonly injured joint due to the lack of proper bony support. The stability of the knee joint is highly dependent on its supporting ligamentous structures, therefore injuries of ligaments and menisci are extremely common.⁽¹⁾ Internal derangement of knee refers to a group of disorder involving disruption of the normal functioning of the ligaments or menisci of knee joint.⁽²⁾ It can be traumatic or degenerative. MRI is most commonly indicated in patients with suspected injuries of the menisci and ligaments. The use of arthrography and arthroscopy improves the accuracy of the diagnosis, but both are invasive and can cause complications. MRI has revolutionized our ability to understand the soft tissue anatomy and pathology of musculoskeletal system. The role of MRI in imaging of knee has steadily increased over years. Magnetic resonance imaging with its excellent soft tissue contrast and multiplanar imaging capabilities has overcome the limitation of other imaging modalities. Hence it has become the investigation of choice for patients with suspected internal derangement of knee.

METHODS AND MATERIALS: Approval for this study was obtained from scientific and ethical committee in our medical college and written informed consent was obtained from all the patients. A total of one hundred and fifty patients with an age range of 21 to 66 years (Mean age of 31 years) with suspected internal derangement of the knee were subjected to MR examination and followed by arthroscopy. All patients underwent MRI knee joint with GE HDxt series 1.5 tesla system with a phased array knee coil. Imaging sequences included PD sagittal, PD coronal, PD axial (2460/32[TR/TE], 4mm thick, 256x256 matrix), T2 sagittal (4900/87[TR/TE], 3mm thick, 256x256

ORIGINAL ARTICLE

matrix), T1 coronal, T1 sagittal (800/8[TR/TE], 4mm thickness, 384x224 matrix), STIR coronal (5460/48[TR/TE], 4mm thickness, 256x160).

The criterion that was used for diagnosing the presence of a meniscal tear was the presence of a hyperintensity that extended to articular surface. The cruciate ligament was described as either normal, partial tear and complete tear. MR examination of knee was performed before arthroscopy was done. Records of MRI and arthroscopic findings were kept and compared. Arthroscopic findings were regarded as the reference standard.

RESULTS: Of the total 150 patients, 92 were male (61%) and 58(49%) were female. The mode of injury was trauma in 95(63%) patients, whereas degenerative in 55(37%) patients. The age ranged from 21 to 66 years. Right knee was affected in 89(59%) and left knee in 61(41%) patients. True positive, true negative, false positive and false negative cases are shown in Table 1.

Ligament/ Meniscus	True Positive	True Negative	False Positive	False Negative
ACL	63	69	13	5
PCL	46	94	6	4
MM	65	67	13	5
LM	46	76	18	10

TABLE 1

Sensitivity, specificity, positive predictive value, negative predictive value and accuracy of MRI for diagnosing ACL, PCL, medial meniscus and lateral meniscus injuries are shown in Table 2.

Test	ACL	PCL	MM	LM
Sensitivity	92.65	92	92.86	82.14
Specificity	84.15	94	83.75	80.85
PPV	82.89	88.46	83.33	71.88
NPV	93.24	95.92	93.06	88.37
Accuracy	88	93.33	88	81.33

TABLE 2

DISCUSSION: The purpose of this study was to compare the accuracy of MRI in diagnosing the Internal Derangement of the Knee with arthroscopy as reference standard. MRI is a noninvasive modality and is routinely used to diagnose wide spectrum of internal derangement of knee. It has replaced conventional arthrography in the evaluation of internal derangement of knee and plays an important role in reducing the morbidity and costs associated with negative arthroscopic examinations.

There are various studies that support the view that the accuracy of MRI could modify the treatment plan of knee injuries. In a study conducted by McKenzie et al⁽³⁾ 332 patients with suspected internal derangement of knee were included. The diagnosis was initially decided upon the clinical examination and the treatment plan was decided before MRI. Out of 113 patients with clinical diagnosis of meniscal tears 57 patients were not confirmed with MRI. This result led to change in

ORIGINAL ARTICLE

the treatment plan in 62% of the patients. From those patients initially planned for surgery only 38% finally underwent arthroscopy. In another study conducted by Weinstabl et al⁽⁴⁾ patients were randomly distributed in two groups. All the patients of the first group had MRI examination before arthroscopy. In this group only 2% of patients didn't have positive findings during arthroscopy. Second group patients underwent arthroscopy without MRI examination. In this group, only in 30% of patients arthroscopy confirmed the findings of clinical examination.

If MRI is used as the pre-operative screening tool for internal derangement of knee, then there may be significant reduction in unnecessary diagnostic arthroscopies. In a study done by Imhoff et al,⁽⁵⁾ the negative predictive value for meniscal tears was 94% and the positive predictive value was 54%. They concluded that due to the high negative predictive value, a normal MRI scan allows to eliminate a meniscal pathology and so there is no need for a diagnostic arthroscopy. In a study conducted by Asif et al. obtained negative predictive value of 81% for medial meniscal tears and 95% for lateral meniscal tears. They concluded that due to a high negative predictive value, a normal MRI scan allows eliminating a meniscal lesion and so there is no need for diagnostic arthroscopy in diagnosing internal derangement of knee.⁽⁶⁾ This shows the effective role of MRI in selecting patients for therapeutic arthroscopy. These studies matched with our study which showed that MRI scans had a high negative predictive value and hence can be used to exclude pathology in doubtful or uncertain cases.

Our study showed false positive rate of 13% for medial meniscal tears and 18% for lateral meniscal tears. It can be explained by the fact that meniscal tears and meniscus degenerative changes have the similar appearance in MRI, by giving high signal within the meniscus⁽⁷⁾ Diagnosis then depends on the expansion of the high signal line towards articular surface.⁽⁸⁾ One of the most frequent causes for false positive MRI regarding the lateral meniscus is the misinterpretation of the signal coming from the inferior knee artery.⁽⁹⁾ The popliteal bursa or Humphrys' ligament may mimic posterior lateral meniscus tears.

According to McKenzie et al⁽³⁾ the common causes for false positive diagnosis includes misinterpretation due to variable anatomic structures, overestimation of pathology countered as meniscus tear, false negative arthroscopic findings and tears within the meniscus without extending to the articular surface. False negative results seem to occur exclusively from misinterpretation of MRI.

Our study showed MRI sensitivity of 92% in diagnosing ACL injuries. Our study matched with the study done by Rubin et.al. Who reported 93% sensitivity for diagnosing ACL injuries.⁽¹⁰⁾ Similarly several studies have shown a sensitivity of 92-100% for the MR diagnosis of ACL tears. Accuracy of MRI in diagnosing ACL tears was 88% in our study. The study done by V kumar and A C hui showed accuracy of 93% for ACL tears.⁽¹¹⁾ In a multicentric analysis, published by Fisher et al, the accuracy ranged from 78-97% for the anterior cruciate ligament.⁽¹²⁾ Study by F. Rayan & Sachin Bhonsle showed positive predictive value of 81% and negative predictive value of 95%, sensitivity of 81%, specificity of 96% and accuracy of 93%.⁽¹³⁾

False positive results in case of ACL is due to intraligamentous degeneration. The difficulty in diagnosing partial ACL tears is related to the nonspecificity of intrasubstance signal abnormality.⁽¹⁴⁾

False negative results mostly arises due to disruption of collagen fibres which are arthroscopically occult.

In case of PCL the sensitivity, specificity, accuracy, positive predictive value and negative predictive value of MRI were 92, 94%, 93%, 88%, 95% respectively in our study. In Study by Ali

ORIGINAL ARTICLE

Akbar esmaili jah sensitivity, specificity, accuracy, positive predictive value and negative predictive value of MRI in case of PCL injuries were 81%, 100%, 94%, 100% and 96%.⁽¹⁵⁾ MRI has a high negative predictive value in our study. This indicates that with negative result for PCL, diagnostic arthroscopy can be avoided.

In a multi-center analysis of one thousand and fourteen patients, Fischer et al.⁽¹²⁾ Reported accuracy of 93%, 99%, 89% and 88% for diagnosing ACL, PCL, medial meniscus and lateral meniscus injuries respectively with MRI. Our study had accuracy of 88%, 93%, 88% and 81% for diagnosing ACL, PCL, medial meniscus and lateral meniscus injuries respectively with MRI. Various other studies also had similar results with our study.

In summary, from our results, the accuracy of MRI in medial and lateral meniscus tear was 88% and 81 % respectively, while for ACL and PCL rupture was 88% and 93% respectively. In the existing bibliography the accuracy of MRI reaches 90% in medial meniscus and ACL injuries, is lesser in lateral meniscus injury and slightly higher in PCL injuries.^(16,17,18)

CONCLUSION: MRI is highly accurate in diagnosis of ligament and meniscal injuries and it can replace diagnostic arthroscopy in patients with internal derangement of knee. In particular, MRI has a high specificity and negative predictive value, suggesting that screening MRI studies can effectively rule out the presence of meniscal lesions and ligament injuries and reduce the number of unnecessary diagnostic arthroscopies performed. MRI is useful in situations where the results of a clinical examination are uncertain, and it is the most appropriate diagnostic screening tool to use before therapeutic arthroscopy.

REFERENCES:

1. Kaplan P.A, Walker C.W, Kilcoyne R.F, Brown D.E, Tusek D, Dussault R.G. Occult fractures patterns of the knee associated with ACL tears. Assessment with MR imaging. Radiology. 1992; 183: 835-838.
2. Hughston JC: Acute injuries in athletes, Clin Ortho 23: 114, 2962.
3. Mackenzie R, Dixon A.K, Keene G.S, Hollingworth W, Lomas D.J, Villar R.N: Magnetic resonance imaging of the knee: assessment of effectiveness. Clin Radiol 1996, 51(4): 245-250.
4. Weinstabl R, Muellner T, Vecsei V, Kainberger F, Kramer M: Economic considerations for the diagnosis and therapy of meniscal lesions: can magnetic resonance imaging help reduce the expense? World J Surg 1997, 21(4): 363-368.
5. Imhoff A, Buess E, Holder J et.al. Comparison between magnetic resonance imaging and arthroscopy for the diagnosis of knee meniscal lesion. Rev Chir Orthop 1997; 83(3): 229-36.
6. Rahman A, Nafees M, Akram M, Hussain A et al. Diagnostic Accuracy of Magnetic Resonance Imaging in Meniscal Injuries of Knee Joint and Its Role in Selection Of Patients For Arthroscopy. J Ayub Med Coll Abbottabad 2010; 22(4).
7. Spiers A.S, Meagher T, Ostlere S.J, Wilson D.J, Dodd C.A: Can MRI of the knee affect arthroscopic practice? A prospective study of 58 patients. J Bone Joint Surg Br 1993, 75(1): 49-52.
8. Herman LJ, Beltran J: Pitfalls in MR imaging of the knee. Radiology 1988, 167(3): 775-781.
9. Watanabe A.T, Carter B.C, Teitelbaum G.P, Bradley W.G Jr.: Common pitfalls in magnetic resonance imaging of the knee. J Bone Joint Surg Am 1989, 71(6): 857-862.
10. Rubin DA, Kettering JM, Towers JD, Britton CA, MR Imaging of knee having isolated and combined ligament injuries. AJR 1998; 170: 1207 - 1213.

ORIGINAL ARTICLE

11. Kumar V, Hui A.C, A Comparative Study of MRI and Clinical Findings in Diagnosis of Internal Derangements of the Knee. J. Orthopaedics 2005; 2(4) e5.
12. Fischer S.P, Fox J.M, Del Pizzo W, Friedman M.J, Snyder S.J, Ferkel R.D: Accuracy of diagnoses from magnetic resonance imaging of the knee. A multi-center analysis of one thousand and fourteen patients.
13. Rayan F, Bhonsle S, Divyang D et al. Clinical, MRI, and arthroscopic correlation in meniscal and anterior cruciate ligament injuries. Int Orthop. 2009 Feb; 33(1): 129–132.
14. Heron CW, Calvert PT: Three-dimensional gradient-echo MR imaging of the knee: comparison with arthroscopy in 100 patients. Radiology 1992, 183(3): 839-844.
15. Jah A.A.E, Keyhani S, Zarei R et al. Accuracy of MRI in comparison with clinical and arthroscopic findings in ligamentous and meniscal injuries of the knee. Acta Orthop. Belg., 2005, 71, 189-196.
16. Quinn S.F, Brown T.F: Meniscal tears diagnosed with MR imaging versus arthroscopy: how reliable a standard is arthroscopy. Radiology 1991, 181(3): 843-847.
17. Crues J.V 3rd, Mink J, Levy T.L, Lotysch M, Stoller DW: Meniscal tears of the knee: accuracy of MR imaging. Radiology 1987, 164(2): 445-448.
18. Simonsen O, Jensen J, Mouritsen P, Lauritzen J: The accuracy of clinical examination of injury of the knee joint. Injury 1984, 16(2): 96-101.

FIGURE 1: MRI PD axial and sagittal images showing bucket handle tear of medial meniscus with flipped meniscus sign (Arrow).

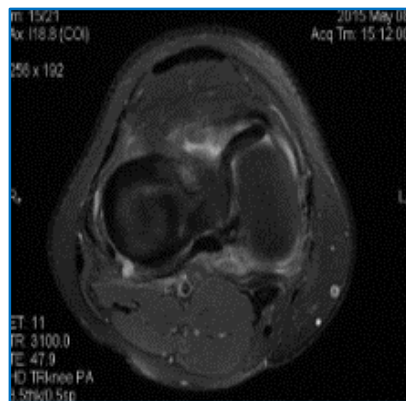


Fig. 1

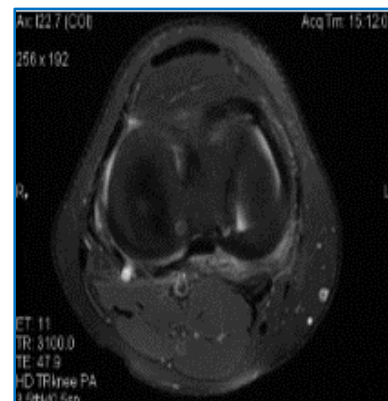


Fig. 1A

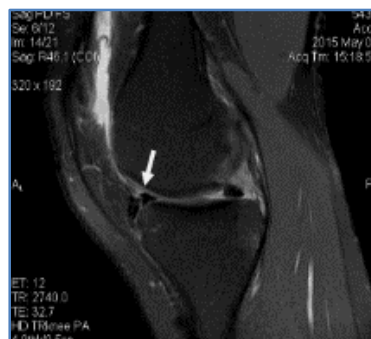

Fig. 1B

ORIGINAL ARTICLE

FIGURE 2: MRI PD sagittal and axial images showing bucket handle tear of medial meniscus with flipped meniscus sign (Arrow) and double PCL sign (Arrow).

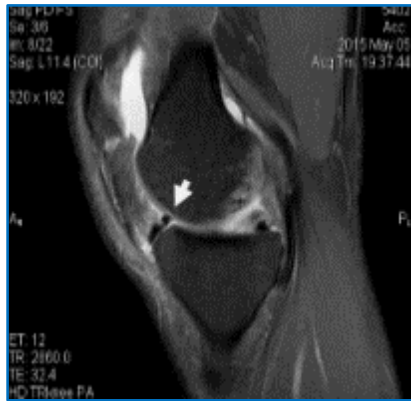

Fig. 2

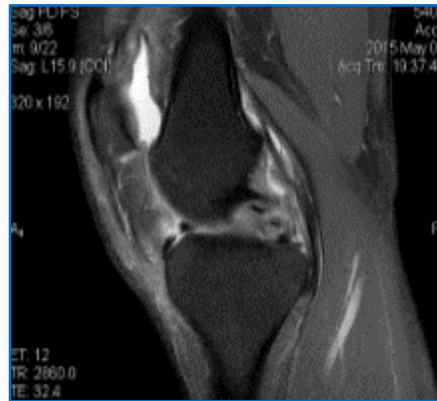

Fig. 2A

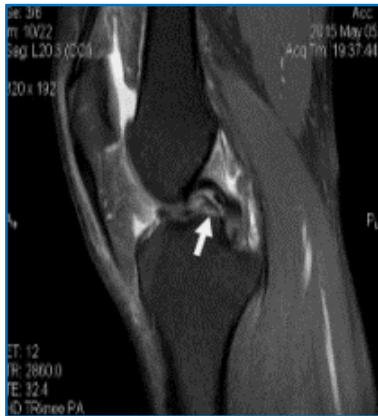

Fig. 2B

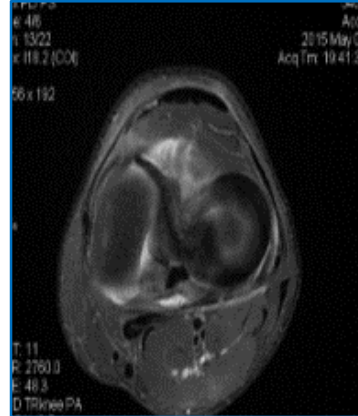


Fig. 2C

FIGURE 3: MRI PD sagittal image shows horizontal tear of medial meniscus.

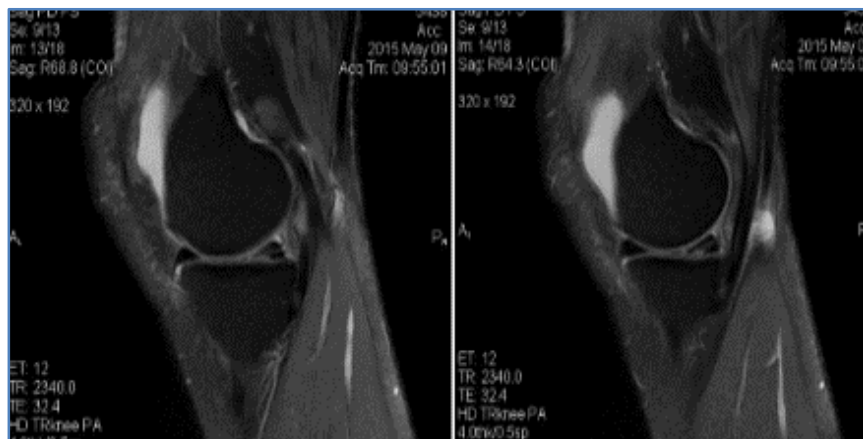

Fig. 3

ORIGINAL ARTICLE

FIGURE 4: MRI PD sagittal image shows vertical tear of medial meniscus.

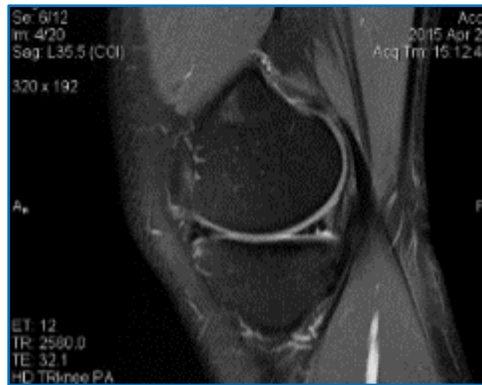


Fig. 4

FIGURE 5: MRI PD sagittal image shows vertical tear of lateral meniscus.

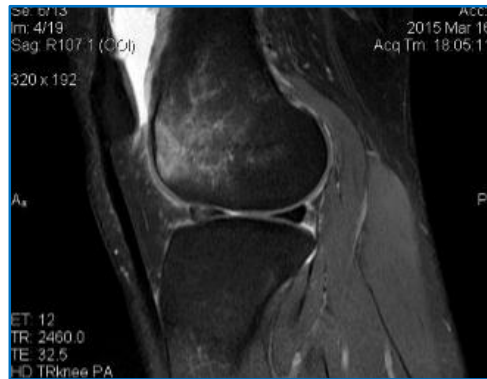

Fig. 5

FIGURE 6: MRI PD axial and sagittal images showing radial tear of medial meniscus with ghost meniscus sign (Arrow).

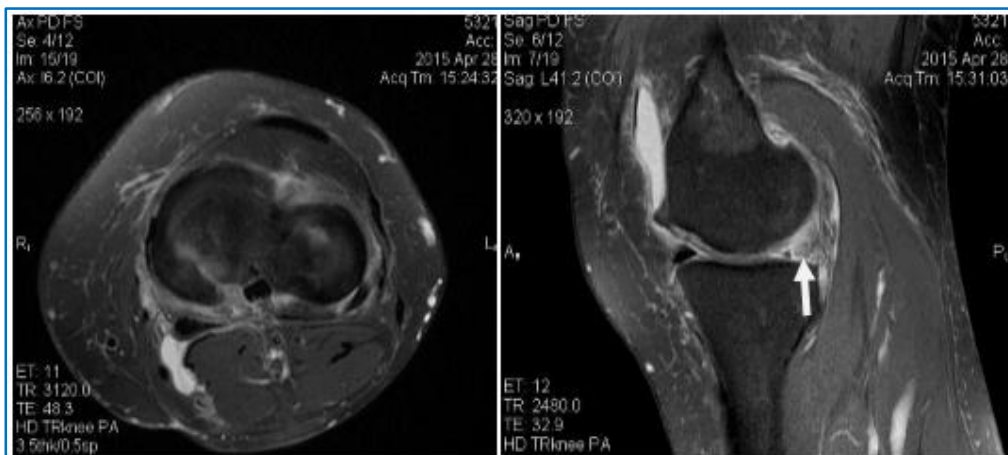


Fig. 6

ORIGINAL ARTICLE

FIGURE 7: MRI PD sagittal, T2 sagittal and T1 sagittal images showing complete tear of Anterior cruciate ligament.

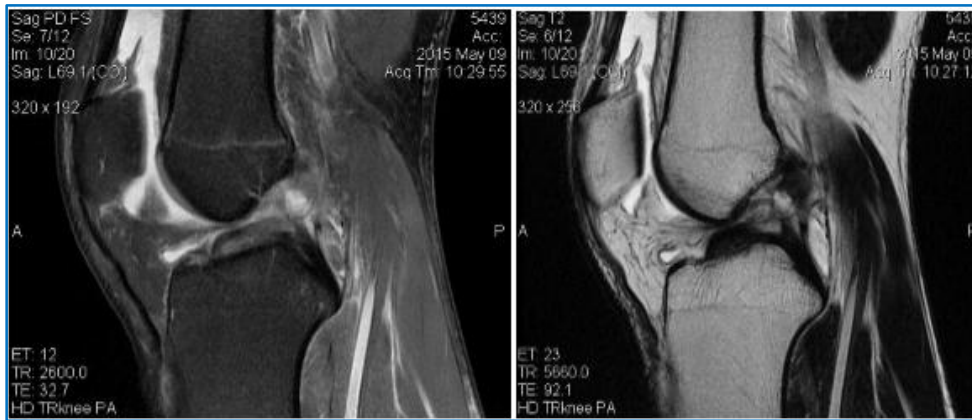

Fig. 7

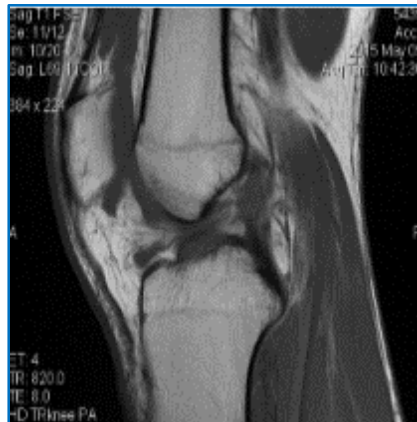

Fig. 7A

Figure 8: MRI PD sagittal, T2 sagittal and T1 sagittal images showing avulsion fracture of tibial attachment site of Posterior cruciate ligament.

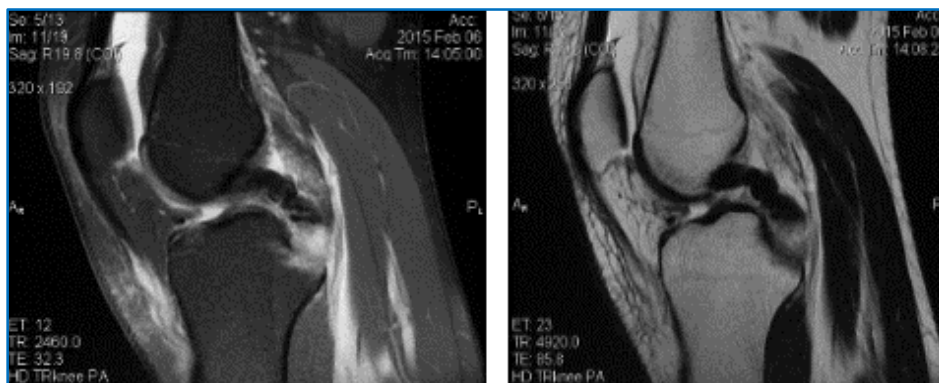


Fig. 8

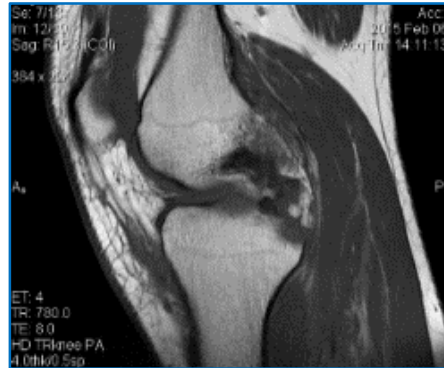

Fig. 8A

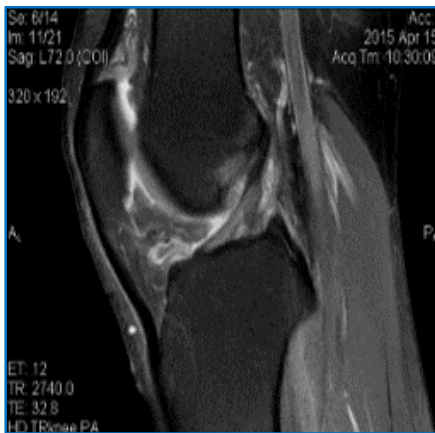

FIGURE 9: MRI PD sagittal image shows mucoid degeneration of anterior cruciate ligament.

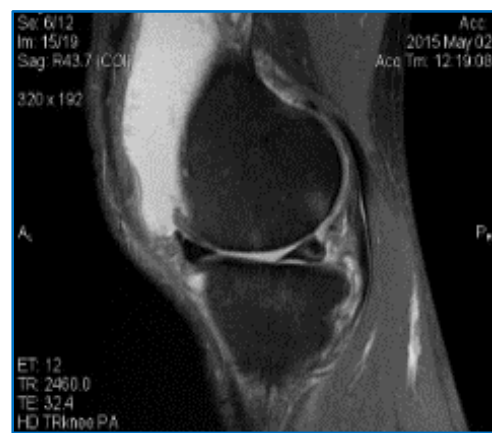

FIGURE 10: MRI PD sagittal image shows Grade 2 signal changes in posterior horn of medial meniscus.

AUTHORS:

1. Rajesh Kumar V.
2. Vasu C. K.
3. Pavithran V. K.
4. Navas K. M.
5. Fathima J.

PARTICULARS OF CONTRIBUTORS:

1. Assistant professor, Department of Radiology, KMCT Medical College.
2. Professor, Department of Radiology, KMCT Medical College.
3. Professor, Department of Radiology, KMCT Medical College.

FINANCIAL OR OTHER

COMPETING INTERESTS: None

4. Associate Professor, Department of Radiology, KMCT Medical College.
5. Senior Resident, Department of Radiology, KMCT Medical College.

NAME ADDRESS EMAIL ID OF THE CORRESPONDING AUTHOR:

Dr. Rajesh Kumar V,
 Department of Radiology,
 KMTC Medical College,
 Manasarry, Mukkom,
 Calicut, Kerala.
 E-mail: kumar2476rd@gmail.com

Date of Submission: 15/05/2015.
 Date of Peer Review: 16/05/2015.
 Date of Acceptance: 04/06/2015.
 Date of Publishing: 10/06/2015.