

## CASE REPORT

### STUDY OF FUNCTIONAL OUTCOME OF SURGICAL MANAGEMENT OF UNSTABLE MALLEOLAR FRACTURES IN ADULTS: A CASE REPORT

S. Sankara Rao<sup>1</sup>, M. Chandra Sekaram Naidu<sup>2</sup>, V. Dharma Rao<sup>3</sup>, V. Arun Kumar<sup>4</sup>, P. Sravya Teja<sup>5</sup>

#### HOW TO CITE THIS ARTICLE:

S. Sankara Rao, M. Chandra Sekaram Naidu, V. Dharma Rao, V. Arun Kumar, P. Sravya Teja. "Study of Functional Outcome of Surgical Management of Unstable Malleolar Fractures in Adults: A Case Report", Journal of Evolution of Medical and Dental Sciences 2015; Vol. 4, Issue 77, September 24; Page: 13526-13530, DOI: 10.14260/jemds/2015/1934

**INTRODUCTION:** Malleolar fractures are one of the most common lower extremity fractures in orthopaedic traumatology. Ankle injuries gain importance because body weight is transmitted through it and locomotion depends upon the stability of this joint. Malleolar fractures have varied presentations which have given rise to a wide variety of classification systems, of which two are in vogue Lauge- Hansens and Danis- Weber classification. As with all intra articular fractures, malleolar fractures necessitate accurate reduction and stable internal fixation. When malleolar fractures are not reduced accurately they may lead to post traumatic painful restriction of motion or osteoarthritis or both.<sup>1</sup>

Many of the fractures which are stable are treated by conservative treatment and have given good result. The other unstable, displaced and open fractures require open reduction internal fixation. The superiority of ORIF over closed treatment have been thoroughly demonstrated in literature.<sup>2</sup>

The purpose of this study is to assess the functional outcome and results of surgical treatment of malleolar fractures. The treatment options with ORIF technique available for malleolar fractures, to attain a proper anatomical alignment and stability of the ankle joint, can lead to rewarding outcome for the patient and surgeon.

**MATERIALS AND METHODS:** Twenty patients with fresh unimalleolar, Bimalleolar and trimalleolar fractures who attended the Andhra medical college, attached to King George hospital between august 2012 to September 2014 were studied.

All the twenty patients who were brought to the emergency ward were evaluated. Then the patients radiographs were taken, anteroposterior, lateral and mortise views of the ankle joints. CT scan is taken in indicated cases. On admission to the ward detailed history was taken relating to the age, sex, occupation, address, mode of injury, past and associated medical illness. Patient's general condition was assessed and then they were put through a thorough clinical examination. Dorsalis pedis and posterior tibial artery pulsations were checked and noted. Active and passive movements of ankle joint are noted.

Analgesics were given and patients were put on a below knee posterior POP slab to alleviate pain. Also antibiotics and tetanus toxoid and tetanus immunoglobulins were given as needed.

After the patient was clinically and radiologically diagnosed to have an unstable ankle fracture and after meeting the inclusion criteria patients were taken up for open reduction and internal fixation. Timing of surgery lasted around 1 to 1 ½ hours, open reduction and internal fixation of the malleolar fractures were performed by tension band wiring, malleolar screw, K- wire fixation or semitubular plating with screws.

## CASE REPORT

### FIXATION OF LATERAL MALLEOLUS WITH SEMI TUBULAR PLATE:

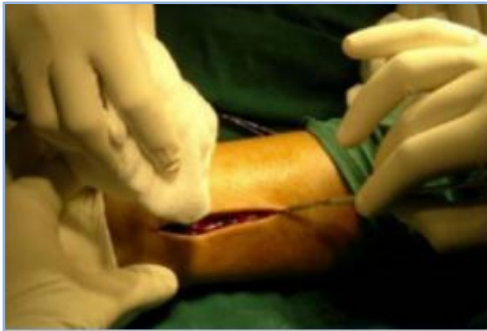

Fig. 1: Incision for lateral malleolus

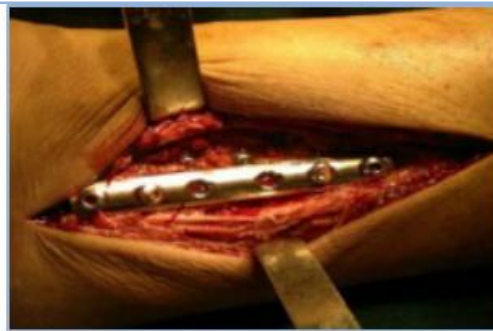

Fig. 2: ORIF with semi-tubular plate

### FIXATION OF MEDIAL MALLEOLUS WITH TENSION BAND WIRING:

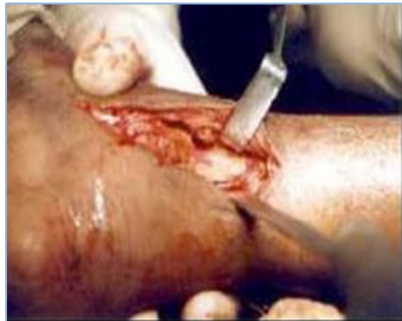

Fig 3. Exposure of the fracture site

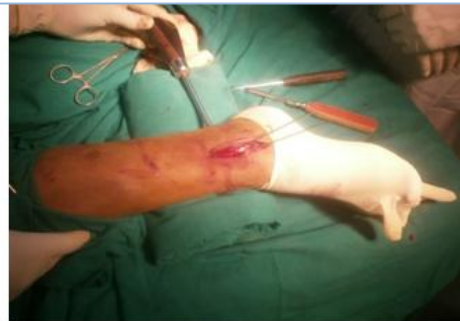

Fig 4. Fixed with 2 k-wires

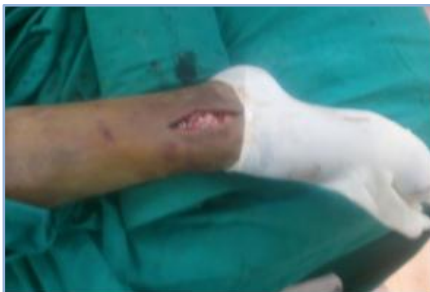

Fig 5. Tension band wiring

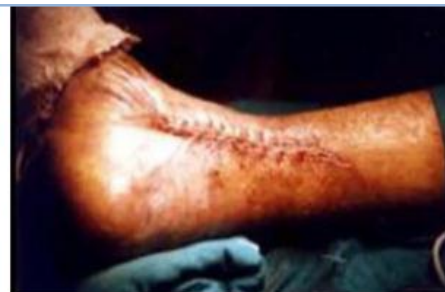

Fig 6. Skin closure

### FIXATION OF MEDIAL MALLEOLUS WITH CC SCREWS:

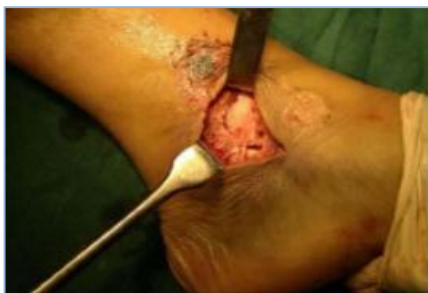

Fig 7. Exposure of fracture site

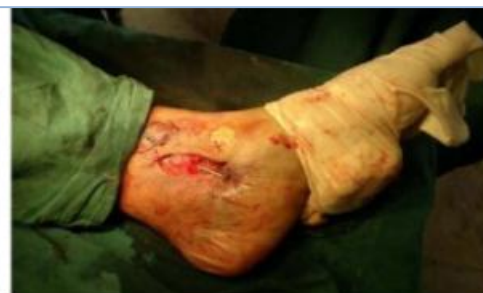

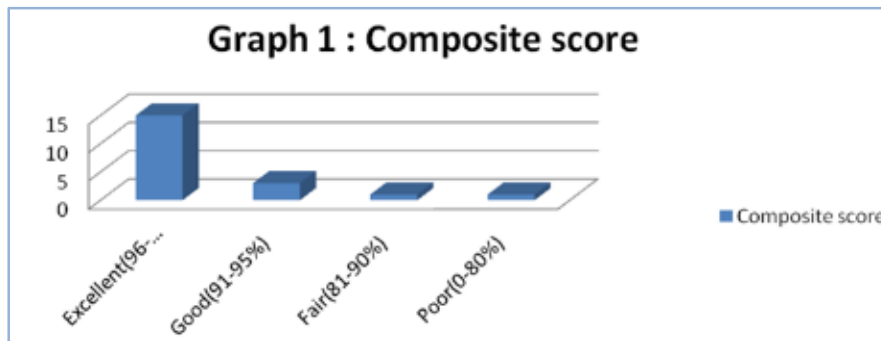
Fig 8. Fixation with CC screws

## CASE REPORT

**RESULTS AND ANALYSIS:** All the fractures were followed until fracture union occurred. Results were analysed both clinically and radio graphically. All most all fractures united at the end of 10 weeks. Functional and radiological results were analyzed using the ankle scoring system of Baird and Jackson.<sup>3</sup>

Composite score	No. of patients	Percentage
Excellent(96-100)	15	75%
Good (91-95%)	3	15%
Fair (81-90%)	1	5%
Poor (0-80%)	1	5%

Table 1: Composite score



**DISCUSSION:** Prompt operative treatment of displaced ankle fractures decreases morbidity and improves functional outcome.<sup>4,5,6</sup> The treatment of malleolar fractures with accurate open reduction and stable internal fixation using AO method and principles was found to give a high percentage of excellent and good results.<sup>1</sup>

The mean age of this study was 44.8 years. This finding was similar to observation of Baird and Jackson,<sup>3</sup> Roberts RS,<sup>7</sup> Beris et al, Lee et al.<sup>8</sup>

The major cause of fracture in our study was road traffic accidents in 12(60%) and in 7(35%) patients fracture was due to slipping and stumbling. The rest 1(5%) patients had fractures due to other causes like fall from height. In the series of Baird and Jackson.<sup>3</sup> 24 patients had fractures due to fall from height and in that of Lee et al.<sup>8</sup> 168 cases were reported due to fall from height.

In the present study Lauge Hansens classification system was used for operative evaluation. The most common type of injury was supination external rotation (35%) and pronation external rotation (30%) and least common was pronation dorsiflexion. This finding is similar to the observation of Roberts RS.<sup>7</sup> (34%), Baird and Jackson.<sup>3</sup> (44%), Beris et al.<sup>1</sup> (33%).

Authors and years	Good- Excellent	Fair	Poor
Burnwell & Charnley. <sup>6</sup>	102(77.3%)	22(16.7%)	8(6%)
Colton. <sup>9</sup>	18(70%)	4(15%)	4(15%)
Beris et al., <sup>1</sup>	105(74.3%)	21(14.6%)	16(11.1%)
Desouza. <sup>10</sup>	135(90%)	9(6%)	6(4%)
Our Study	18(90%)	1(5%)	1(5%)

Table 2: Final Results of this Study Compared with Other Studies

## CASE REPORT

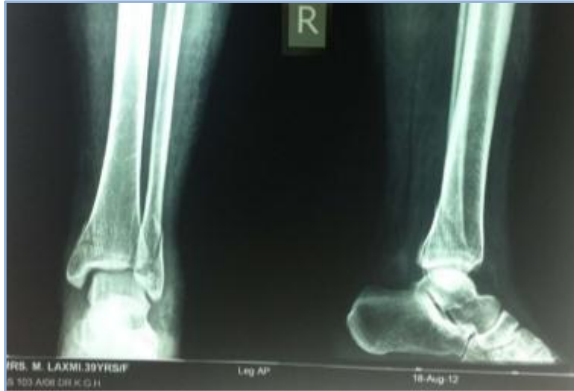

Fig 9. Preoperative xray

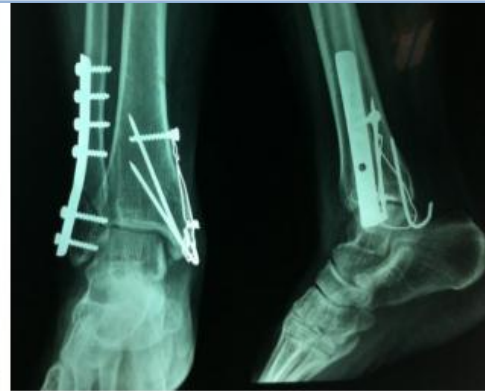

Fig 10. 4 weeks postoperative xray

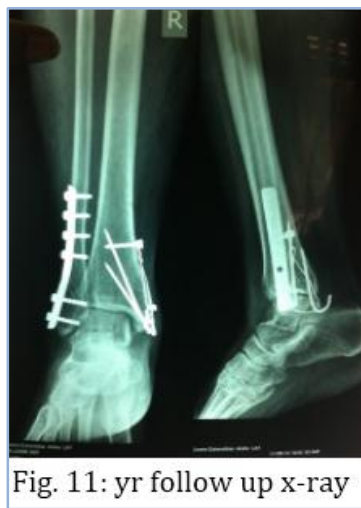

Fig. 11: yr follow up x-ray

**CONCLUSION:** In or present study of 20 patients with ankle fractures that were unstable, displaced or both treated surgically by Open reduction and internal fixation in accordance with AO principles. Understanding the mechanism of injury is essential for good reduction and internal fixation. The bend of the lateral malleolus should be reproduced when the plate is being used and also the fibular length has to be maintained for lateral stability of the ankle. Anatomical reduction is essential in all intra articular fractures more so for a weight bearing joint like ankle. Open reduction and internal fixation will ensure high standard of reduction besides eliminating the chances of loss of reduction since the operative results were satisfactory in 90% of patients.

The results in our series confirm as have those of other series that Open reduction and Internal fixation is the treatment of choice for unstable and displaced malleolar fractures.

### REFERENCES:

1. Beris AE, Kabbani KT, Xenakis TA, Mitsionis G, Soucacos PK, Soucacos PN. Surgical treatment of malleolar fractures – a review of 144 patients. Clin Orthop, Related Research, 1997 Aug; 341: 90- 98.
2. Weber MJ. Ankle fractures and dislocations. In: Operative orthopaedics, Chapter-50, 2nd edn, Vol.3, Ed. Chapman MW, Madison M. Philadelphia: J. B., Lippincott Company, 1993; 731- 748pp.

## CASE REPORT

3. Baird RA and Jackson ST. Fracture of the distal part of fibula with associated disruption of the deltoid ligament. *J Bone Joint Surg*, 1987; 69A: 1346- 52.
4. Lindsojo U. Operative treatment of ankle fracture – dislocations. *Clin Orthop*, 1985; 199: 28- 38.
5. Muller ME, Allgower M, Scheider R, Willenegger H. *Manual of internal fixation: techniques recommended by the AO-group*, 3rd edn, New York: Springer-Verlag, 1991.
6. Burwell HN and Charnley AD. The treatment of displaced fractures at the ankle by rigid internal fixation and early joint movement. *J Bone Joint Surg*, 1965; 47B:634- 660.
7. Roberts RS. Surgical treatment of displaced ankle fractures. *Clin Orthop*, 1983; 172: 164- 170.
8. Lee Yih- Shiunn, Huang, Chun-Chen NSP, Chen, Cheng- Nan, Lin Chien-Chung. Operative treatment of displaced lateral malleolar fractures: The Knowles pin technique. *J Orthop Trauma*, 2005 Mar; 19(3): 192-197.
9. Colton CL. The treatment of Dupuytren's fracture dislocation of the ankle. *J Bone Joint Surg*, 1971; 53B: 63-71.
10. DeSouza LJ, Gustilo RB, Meyer TJ. Results of operative treatment of displaced external rotation – abduction fractures of the ankle. *J Bone Joint Surg*, 1985; 67A:1066- 1074.

### AUTHORS:

1. S. Sankara Rao
2. M. Chandra Sekaram Naidu
3. V. Dharma Rao
4. V. Arun Kumar
5. P. Sravya Teja

### PARTICULARS OF CONTRIBUTORS:

1. Assistant Professor, Department of Orthopaedics, King George Hospital, Andhra Medical College, Visakhapatnam.
2. Assistant Professor, Department of Orthopaedics, King George Hospital, Andhra Medical College, Visakhapatnam.
3. Professor, Department of Orthopaedics, King George Hospital, Andhra Medical College, Visakhapatnam.

### FINANCIAL OR OTHER

**COMPETING INTERESTS:** None

4. Senior resident, Department of Orthopaedics, King George Hospital, Andhra Medical College, Visakhapatnam.
5. Senior resident, Department of Orthopaedics, King George Hospital, Andhra Medical College, Visakhapatnam.

### NAME ADDRESS EMAIL ID OF THE

#### CORRESPONDING AUTHOR:

Dr. S. Sankara Rao,  
#15-15-116, B. R. Complex,  
Maharanipeta,  
Visakhapatnam-530002,  
Andhra Pradesh.  
E-mail: surapthi\_ortho@yahoo.com

Date of Submission: 31/08/2015.  
Date of Peer Review: 01/09/2015.  
Date of Acceptance: 19/09/2015.  
Date of Publishing: 24/09/2015.