

OUTCOMES OF MANAGEMENT IN TALAR FRACTURES IN BHUBANESWAR, ODISHA: A RANDOMIZED PROSPECTIVE THERAPEUTIC STUDY

Sunil K. Dash¹, Geetanjali Arora², Nishit Palo³, Sidharth S. Chandel⁴, Mohammed Shafique⁵, Manas R. Biswal⁶

HOW TO CITE THIS ARTICLE:

Sunil K. Dash, Geetanjali Arora, Nishit Palo, Sidharth S. Chandel, Mohammed Shafique, Manas R. Biswal. "Outcomes of Management in Talar Fractures in Bhubaneswar, Odisha: A Randomized Prospective Therapeutic Study". *Journal of Evolution of Medical and Dental Sciences* 2015; Vol. 4, Issue 05, January 15; Page: 780-789, DOI: 10.14260/jemds/2015/113

ABSTRACT: INTRODUCTION: Talar fractures are difficult and rare injuries with incidence of less than 2%¹, are one of the most challenging and devastating injuries with varied prognosis, posing a real time challenge to orthopedic surgeons. **METHODS:** The study is a prospective multicenter randomized therapeutic study initiated in December '2006 on 40 patients with talus fracture to highlight and compare the different modalities of management of talar fractures in terms of functional and clinical results and complications. **RESULTS:** Out of 40 patients, 32 were male and 8 were female with a male/female ratio of 4:1. Most fractures were due to RTA in 22 cases. Most fractures were in neck of talus in 20 (50%). Out of 40 talar fractures, 10 were managed conservatively, 18 operated with screw fixation, 4 were fixed with cross K-wires and 8 old cases were managed with Blair's fusion. We experienced complications in 12 cases. **DISCUSSION:** A high degree of suspicion is required for the diagnosis of talus/ talar processes fractures, talus being the second most common tarsal bone to fracture. The preferred surgical timing for talar neck fractures is controversial. But the scenario in the sub-continent is quite different wherein the patients report late to the hospital often due to ignorance, quack therapy and illiteracy, often presenting with complicated and neglected injuries. Also, published literature and long term prospective studies on talar fractures, its treatment and complications based on our population is lacking.

KEYWORDS: Talus, Osteonecrosis, Fracture, Ankle, Precarious, Blair's Fusion.

INTRODUCTION: Fractures of talus are difficult injuries¹. Talus bone with 60% of its surface covered with articular cartilage is an integral component of the ankle joint and has been well known for its precarious blood supply. Among the injuries around the ankle joint, fractures involving the talus are rare with an incidence of less than 2%¹, are one of the most challenging and devastating injuries with varied prognosis, posing a real time challenge to the orthopaedic surgeons.

Fabricius of Hilden in 1608 described the mechanism of injury of talus with its complications and treatment. Anderson² described the "Aviators astralagus" which were talar neck fractures commonly seen in pilots during the World War 1 as a result of hyper dorsiflexion injury at the time of landing. Penny and Davis(1980)³ described the mechanism by which the hyper dorsiflexion force causes a talus fracture. Mechanism of injury is a hyper dorsiflexion injury or axial loading injury⁴, wherein a fixed talus acts as a cantilever, injuring the distal tibial plafond as well. The fractures of Lateral and Posteromedial processes with subtalar dislocations can occur with relatively low energy inversion-eversion injuries as seen in sports injuries.

The frequent incidence of serious complications such as osteonecrosis, skin dehiscence, non-union, neurovascular injuries, pain, stiffness and post traumatic arthritis of the subtalar and the ankle

ORIGINAL ARTICLE

joint and neuropathic joints ⁵ leads to high risk of unsatisfactory results. Nonetheless, the talus fracture remain among the most interesting and difficult injuries in orthopaedic trauma.¹

This study was initiated to highlight and compare the different modalities of management of talar fractures in terms of functional and clinical results and complications. The study was setup in Hi-Tech Medical College and Kalinga hospital in 2006 and 40 patients with talus fracture were included in the study. Patients were randomly assigned the treatment option by a person who was blinded for the study. Patient followed up for a minimum of 1 year, results were tabulated and compared with the established literature.

VASCULAR ANATOMY: "Sinus tarsi" is a conical hollow bounded by the talus medially, superiorly and laterally with the superior surface of calcaneus below. Its medial narrow and tunnel shaped part is often referred to as "Tarsal Canal". The tarsal canal runs from posteromedial to anterolateral, where it opens into the sinus tarsi.

The vascular anatomy of the talus has been extensively studied by McKeever (1943), Wildenauer (1950), Haliburton et al. (1958), Mulfinger and Trueta (1970), and Gelberman and Mortensen (1983). Talus has a rich extraosseous network of arteries formed mainly by 3 major vessels of leg i.e. Posterior Tibial Artery, Dorsalis Paedis Artery (Anterior Tibial Artery) and Perforating Peroneal Artery supplying blood to the head, neck, and body of the talus.(see Diagram.1)

The head and neck regions are richly supplied by the superior neck vessels and the artery of the sinus tarsi and osteonecrosis of these areas is extremely rare whereas lateral 1/2 of the talar body is vulnerable because of its precarious blood supply and degree of displacement of the body, osteonecrosis rates can be 100%.

The artery of the tarsal canal is a branch of posterior tibial artery and is the most consistent major supplier of blood to the body of the talus. In the tarsal canal, it gives off four to six direct vessels into the body of the talus. One of these braches is called the "Deltoid artery" which supplies medial ¼ to ½ of the talar body; the deltoid artery may sometimes arise from medial plantar artery. In major fractures of talus, deltoid artery may be the only surviving vessel to maintain the viability of the talar body.

The artery of the sinus tarsi, formed by the branches of perforating peroneal artery, the dorsalis paedis (or anterior tibial) artery, or anastomoses between the two and supplies the lateral 1/8 to ¼ of talar body. The artery of tarsal canal enters the lateral part of sinus tarsi to form anastomosis, forming a vascular sling underneath the talar neck.

The posterior tubercle of the talus is supplied by direct branches from the posterior tibial artery or the peroneal artery.

MATERIAL AND METHODS: This is a prospective multicenter randomized therapeutic study initiated in December '2006 at Hi-Tech Medical College and Hospital. Patients with talus fracture of any etiology who gave consent for the study were included in the study. Patients were managed surgically or conservatively depending on a computer generated random number to facilitate randomization process and prevent bias. While the Conservative management included plaster cast application, surgical management varied from K-wire fixation to screw fixation and Blayer's Fusion was reserved for the old and neglected cases.

ORIGINAL ARTICLE

INCLUSION CRITERIA: Talus fracture, any etiology, patient presenting within 48 hours of injury, consent obtained.

CLASSIFICATION: Hawkins's classification is mostly used to classify talar fractures, it is simple and provides guidelines for the treatment and predicts the prognosis. Hawkins's classified talar fractures into: Type I, II, III and IV.

OTHER CLASSIFICATION SYSTEMS: Canale and Kelly modification of the Hawkins's Classification (1978), Martin-weber and Orthopedic Trauma Association's classification.

RADIOLOGICAL DIAGNOSIS:

X-RAYS: Anteroposterior,⁶ Oblique⁷ and Lateral views were employed for all the talar fracture diagnosis; Canale and Kelly's View^{8,9} (For Talar neck fracture) and Mortise views were used to evaluate the ligaments of the ankle joint and fractures of lateral process of talus in difficult cases only. CT Scan¹⁰ and MRI Scan^{11,12} were performed in all the cases.

SURGICAL APPROACH: For undisplaced fractures, a percutaneous cancellous 4mm/6mm screw fixation under C-arm was preferred in the postero-anterior direction; head were counter-sunked into the bone. Whenever anatomical reduction was not achieved with closed means or in displaced fractures, under aseptic precautions and spinal anesthesia, standard medial approach to the ankle joint and talus (Koenig and Schaefer) was employed with a medial malleolus osteotomy taking care not to injure tibial vessels and nerve. In comminuted fracture of talus, where fixation was not possible; Talectomy or Blair's Fusion (Talectomy with Calcaneotibial fusion) was done.

CONSERVATIVE MANAGEMENT: A pop below knee slab in plantigrade position of the foot followed elevation and rest with a pop below knee cast for 6-8 weeks with strict non-weight bearing followed by walking cast for 6 weeks.

METHODOLOGY: Patient reporting with a talus fracture of any etiology within 48 hours was subjected to X-Rays, CT scan and MRI prior to the management. The patients having a neglected fracture or presenting late were treated by Blair's Fusion. History was noted and a random computer generated number ascertained the treatment modality which was not influenced by the treating surgeon. The patients managed surgically underwent routine pre anesthetic checkup and preparation.

FOLLOW UP: Patients were followed at 2, 4, 6 and 8 weeks post injury to ascertain union, infection, avascular necrosis or arthritis on routine clinical examination and X-Rays. All the patients were followed up for a minimum of 1 year.

OBSERVATIONS: In our study, out of 40 patients, 32 were male and 8 were female with a male/female ratio of 4:1. Majority of patients (14) belonged to the age group of 31-40 years with a range of 20-60 years, followed by 12 patients in the 41-50 age group.(Fig. 1).

ORIGINAL ARTICLE

Most fractures were due to road traffic accidents as seen in 22 (55%) cases, followed by fall from height in 8 (20%) cases and sports injury in 6 (15%) patients and domestic fall in 4 (10%) cases.(Fig. 2).

Most common site of fracture in talus was the neck in 20 (50%) cases followed by the body in 14 (35%) cases and lateral process in 6 (15%) cases (Fig. 3). Out of the 40 fractures, 28 presented within 48 hours and 12 presented after 48 hours to the hospital with 29 fractures being simple and 11 comminuted fractures.(Fig. 4).

Out of the 40 talar fractures, 10 were managed conservatively, 18 were operated with screw fixation, 4 were fixed with cross K-wires and 8 old cases were managed with Blair's fusion (Fig. 5). We experienced complications in 12 cases (30%), 6 cases developed secondary osteoarthritis around 6-8 months post fracture, more in cases which were managed operatively. Avascular necrosis was seen in 4 cases of fracture in the neck region, 3 fixed with screw fixation and 1 case was managed conservatively. Out of the 3 cases operated, 1 reported within 48 hours and 2 patients reported 6 days post initial trauma. Nonunion was seen in 2 cases, 10 months post fracture and were seen in cases where conservative measures were employed.(Fig. 6).

We had a 1 year follow up in 70% patients, at the end of 1 year, 60% patients had a good and 30% patients had a fair prognosis. (Fig. 7, 8).

DISCUSSION: In Greek mythology, Talos was a giant, grotesque bronze god with a singular large vein coursing through his body, because of which he was quiet vulnerable to injury, his crucial weakness was the relative ease with which exsanguination might occur¹. The talus fractures often occur in young and mobile population, accounts for 2% of all lower extremities of fractures and 5-7% of foot and ankle injuries.¹

A high degree of suspicion is required for the diagnosis of talus/ talar processes fractures, talus being the second most common tarsal bone to fracture. Colart¹³ reviewed 228 talus fractures and concluded that chip and avulsion fractures were the most common followed by the fractures of the talar neck. The presentation of talar fractures may vary from vague pain by which they may be missed on initial presentation to compound fractures such as Hawkin's Type III where the talus may be excruded from the joint posteromedially and wrapped around the deltoid ligament.^{14,15}

Standard AP and Oblique X-rays supplemented by the Mortise View and CT, MRI facilitates fracture pattern understanding and diagnosis. CT scan gives excellent visualization of congruity of the subtalar joint reduction, has greater accuracy in detection and characterization of displacement following fixation or displacement associated with malunion.¹ The routine use of CT scans includes assessment of congruency of reduction with intraoperative imaging with mobile CT scans. MRI has a important role in assessment of osteonecrosis following talar fractures.¹

The preferred surgical timing for talar neck fractures is controversial. Clinical studies have, to date, not demonstrated a significant effect of surgical timing on rates of osteonecrosis.¹ A recent survey of orthopaedic trauma experts regarding the timing of surgical treatment for displaced neck fractures revealed that 40% respondents felt treatment should occur within 8 hours and 76% felt treatment should occur within 24 hours; the remaining 24% felt treatment after 24 hours was acceptable.¹⁶

ORIGINAL ARTICLE

The principles of surgery are to obtain an anatomic reduction of the talar fractures especially the neck and associated joints and to achieve sufficient stabilization to facilitate early motion.¹

Emergent reduction of dislocated joints, precise fracture reduction and stabilization, protection of remaining vascular supply and soft tissue envelope provide the best probability of regaining an excellent functional result.

The most commonly used classification is by Hawkins¹⁷ with modifications suggested by Canale and Kelly.¹⁸ The incidence of osteonecrosis ranging from rare in Type I fractures to 100% in Type III fractures. Hawkins's Type-II and Martin Weber Type I and II are amenable to conservative management with a 40-50% risk of developing avascular necrosis and post traumatic arthritis. We treated 2 cases of Hawkins's Type I fracture neck and 2 cases of talar process conservatively with a plaster cast and found union in both the cases. The most comprehensive classification of talar fractures is described in the Orthopaedic Trauma Association's Fracture and Dislocation compendium.¹⁹

But the scenario in the sub-continent is quite different wherein the patients report late to the hospital often due to ignorance, quack therapy and illiteracy, often presenting with complicated and neglected injuries. Also, published literature and long term prospective studies on talar fractures, its treatment and complications based on our population is lacking.

Bohler, Mindellbetal and Pennel stated that there is a high risk of Avascular Necrosis (20-30%) and subtalar post traumatic arthritis (70-100%) with open reduction and internal fixation in Type 3 and 4 fractures.

In our series we found AVN in 4 cases (10%) and Arthritis in 6 cases (15 %). In instances of osteonecrosis, weight bearing was delayed for 6-8 weeks and for secondary osteoarthritis, physiotherapy was initiated for all the patients.

Weber advised in cases of Type 3 and 4 fractures of talus, excision of the talar body, tibiotalar fusion to be done primarily. Coltart¹³ advocated talectomy and Reckling (1972) advised talectomy and tibio calcaneal fusion. For all the talar fractures that were displaced and operated, we performed early decompression, open reduction and internal fixation under C-arm guidance using K wires and 2 lag screws within 48 hours to prevent avascular necrosis.

James D, Hackman-MB (1985) advocated Open reduction and Internal Fixation for large lateral process fractures of talus with K wires/ Lag screws in all cases and excision of the small fragments. But in our series all cases were managed conservatively and we found union in all cases. In our series, old untreated talar fractures and talar fractures associated with complications were treated by Blair's Fusion. We preferred Blair's Fusion over Reckling's fusion because of more anatomical Position achieved.

CONCLUSION: Talus is a weight bearing bone in a weight bearing joint. The fractures of neck and body of talus must be treated operatively and fixed, percutaneous or open depending on the reduction with a aim of early fixation to reduce AVN incidences. For neglected or old cases with complications, Blair's Fusion is a very good alternative surgical procedure in which the anatomical position of the foot remains unchanged and the foot remains pain free.

REFERENCES:

1. Sanders WD. "Talus Fractures". Rockwood and Green's Fracture in Adults. 7th Edition; Vol, Pg 2023-2063.
2. Anderson HG. The medical and surgical aspects of aviation. London: Oxford University Press, 1919.
3. Penny JN, Davis LA. Fractures and fracture-dislocations of the neck of the talus. *J Trauma* 1980; 20: 1029-1037.
4. Peterson L, Goldie IF, Irstam L. Fracture of the neck of the talus: a clinical study. *Acta Orthop Scand* 1977; 48: 696-706.
5. Charcot JM. Sur Quelques Arthropathies qui paraissent pendre d'une lesion cerveau ou de la moelle epiniere. *Arch Physiol Normale Pathol* 1868; 1: 161-178.
6. Ebraheim NA, Karkare N, Gehling D, et al Use of a 30-degree external rotation view for posteromedial tubercle fractures of the talus. *J Orthop Trauma* 2007; 21: 579-582.
7. Ebraheim NA, Patil V, Frisch NC, et al. Diagnosis of medial tubercle fractures of the talar posterior process using oblique views. *Injury* 2007; 38: 1313-1317.
8. Canale ST. Fractures of the neck of the talus. *Orthopedics* 1990; 13: 1105-1115.
9. Canale ST, Kelly FB Jr. Fractures of the neck of the talus: long-term evaluation of 71 cases. *J Bone Joint Surg* 1978; 60A: 143-156.
10. Wirth S, Euler E, Linsenmaier U, et al. C-arm-based mobile computed tomography: a comparison with established imaging on the basis of simulated treatments of talus neck fractures in a cadaveric study. *Comput Aided Surg* 2004; 9: 27-38.
11. Kerr R, Forrester DM, Kingston S. Magnetic resonance imaging of foot and ankle trauma. *Orthop Clin North Am* 1990; 21: 591-601.
12. Munk PL, Vellet AD, Levin MF, et al. Current status of magnetic resonance imaging of the ankle and the hindfoot. *Can Assoc Radiol J* 1992; 43: 19-30.
13. Coltart WD. Aviator's astragalus. *J Bone Joint Surg* 1952; 34B: 545-566.
14. Hawkins LG. Fracture of the lateral process of the talus. *J Bone Joint Surg* 1965; 47A: 1170-1175.
15. Sneed WL. The astragalus: a case of dislocation, excision and replacement: an attempt to demonstrate the circulation in this bone. *J Bone Joint Surg* 1925; 7: 384-399.
16. Patel R, Van Bergeyck A, Pinney S. Are displaced talar neck fractures surgical emergencies? A survey of orthopaedic trauma experts. *Foot Ank Int* 2005; 26: 378-381.
17. Hawkins LG. Fractures of the neck of the talus. *J Bone Joint Surg* 1970; 52A: 991-1002.
18. Canale ST, Kelly FB Jr. Fractures of the neck of the talus: long-term evaluation of 71 cases. *J Bone Joint Surg* 1978; 60A: 143-156.
19. Orthopaedic Trauma Association Committee for Coding and Classification. Fracture and Dislocation Compendium—2007. *J Orthop Trauma* 2007; 21 Suppl: S90-S91.

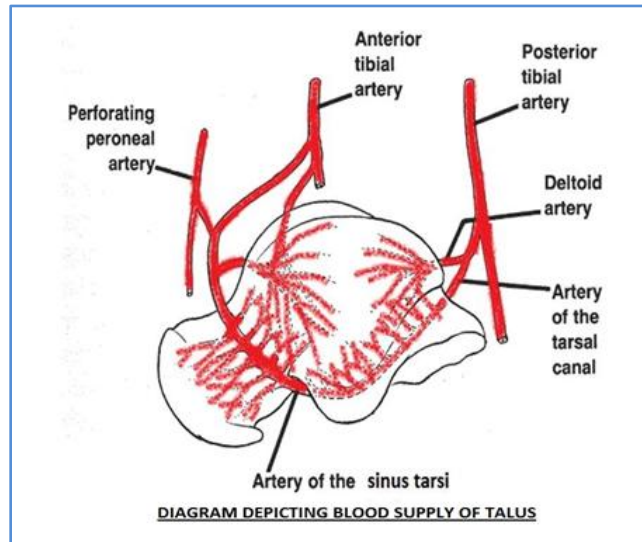


Figure.1 : Patient Characteristics
(Age Grouping)

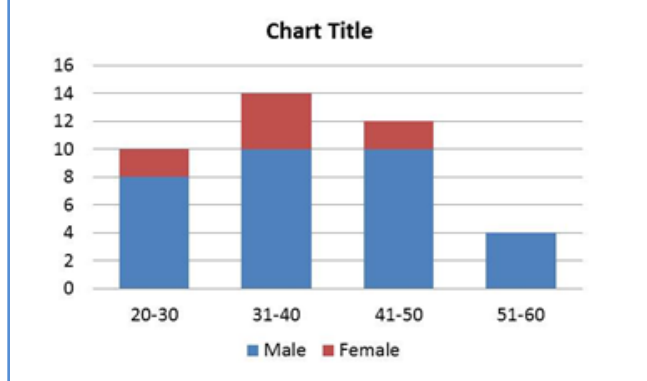
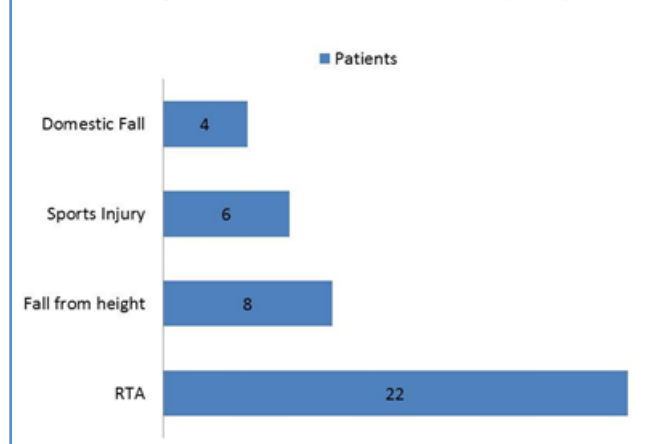
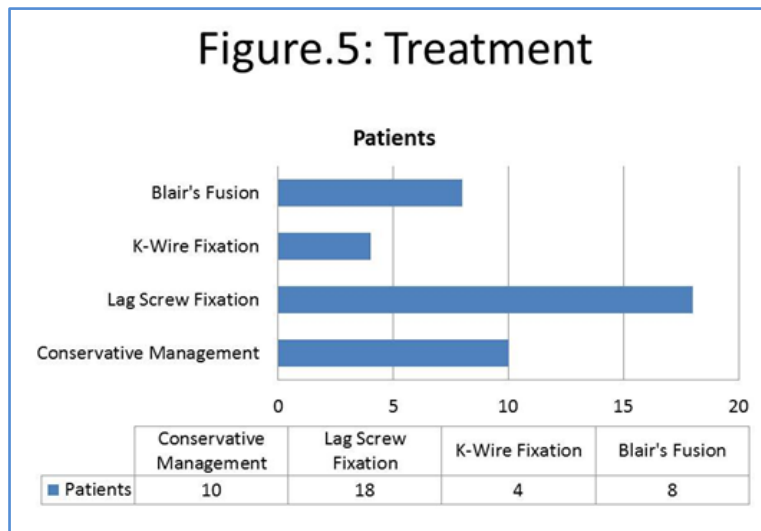
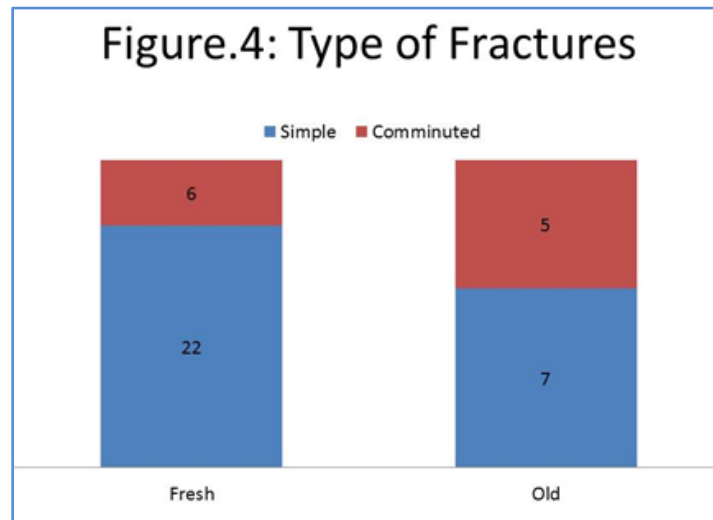
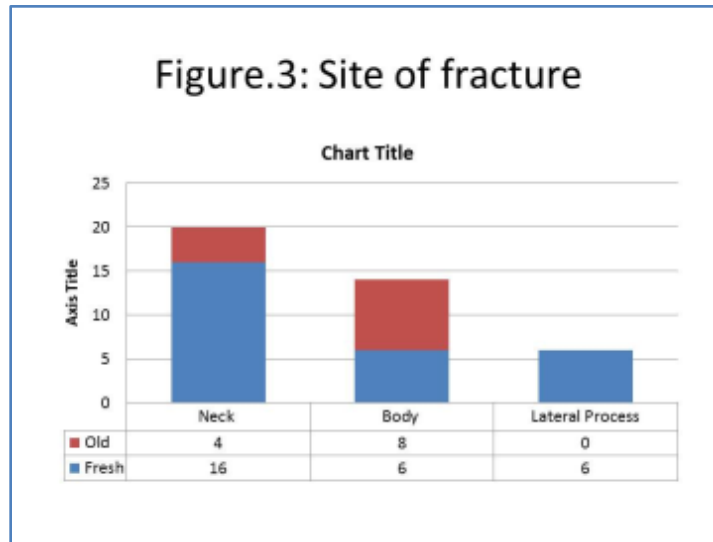
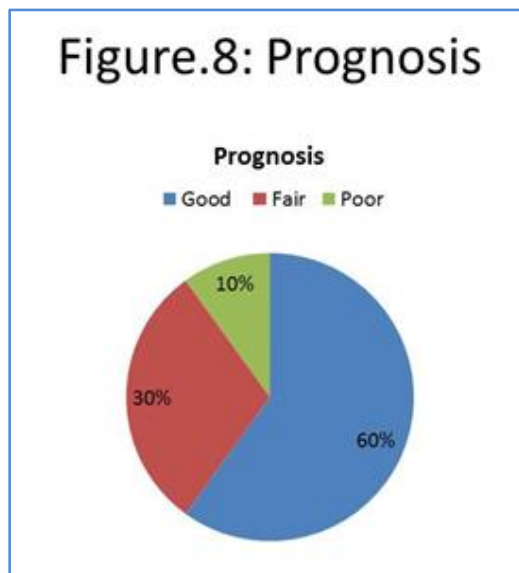
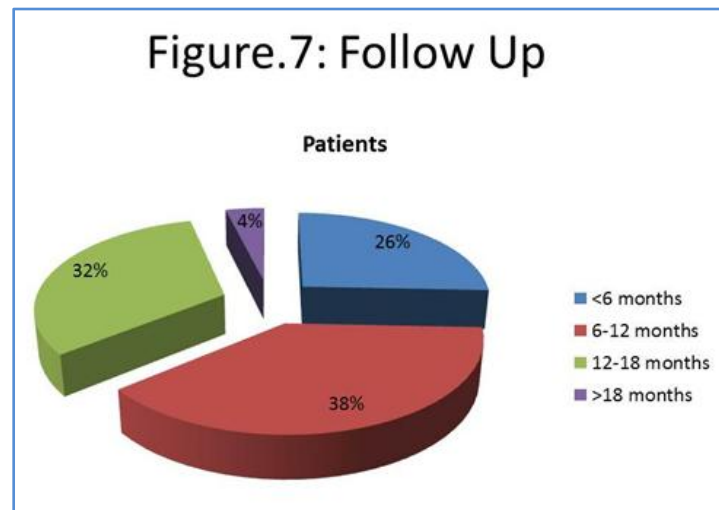
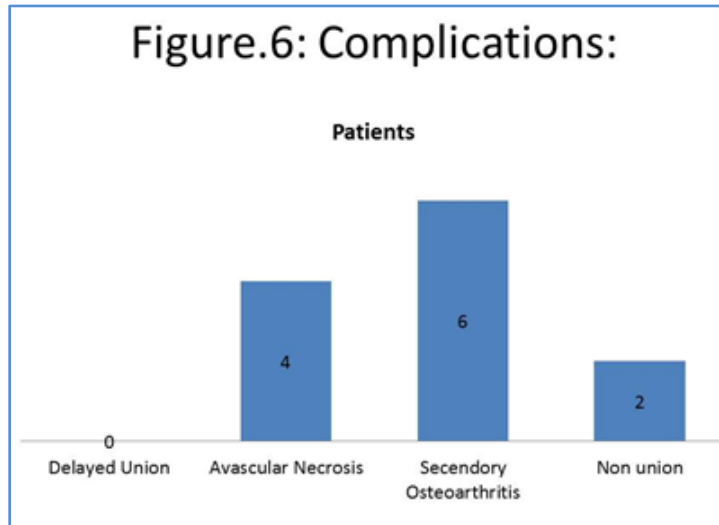


Figure.2: Mode of Injury



ORIGINAL ARTICLE





AUTHORS:

1. Sunil K. Dash
2. Geetanjali Arora
3. Nishit Palo
4. Sidharth S. Chandel
5. Mohammed Shafique
6. Manas R. Biswal

PARTICULARS OF CONTRIBUTORS:

1. Associate Professor, Department of Orthopaedics, Hi-tech Medical College & Hospital.
2. Professor, Department of Anatomy, Hi-tech Medical College & Hospital.
3. Post Graduate Student, Department of Orthopaedics, Hi-tech Medical College & Hospital
4. Post Graduate Student, Department of Orthopaedics, J. L. N. Hospital.

5. Junior Tutor, Department of Anatomy, Hi-tech Medical College & Hospital.
6. Professor & HOD, Department of Orthopaedics, Hi-tech Medical College & Hospital.

NAME ADDRESS EMAIL ID OF THE CORRESPONDING AUTHOR:

Dr. Sunil K. Dash,
Associate Professor,
Department of Orthopaedics,
Hi-tech Medical College & Odisha.
Flat No. 5, Block-II, Hi-tech Medical College Campus,
Helath Park, Pandara, Bhubaneswar-751025, India.
E-mail: drsunil_dash@yahoo.com

Date of Submission: 25/12/2014.
Date of Peer Review: 26/12/2014.
Date of Acceptance: 06/01/2015.
Date of Publishing: 13/01/2015.