

## REVIEW ARTICLE

### RESULT OF PRE-CONTOURED DISTAL RADIUS INDIAN LOCKING PLATES IN DISTAL RADIUS FRACTURE

Shaleen Sareen<sup>1</sup>, Baljit Singh<sup>2</sup>, Aditya Bhardwaj<sup>3</sup>, Parminder Virdi<sup>4</sup>, Simarpreet S. Bhattal<sup>5</sup>

#### HOW TO CITE THIS ARTICLE:

Shaleen Sareen, Baljit Singh, Aditya Bhardwaj, Parminder Virdi, Simarpreet S. Bhattal. "Result of Pre-Contoured Distal Radius Indian Locking Plates in Distal Radius Fracture". *Journal of Evolution of Medical and Dental Sciences* 2014; Vol. 3, Issue 62, November 17; Page: 13736-13743, DOI: 10.14260/jemds/2014/3836

**ABSTRACT: BACKGROUND:** Fractures of the distal radius are common, open reduction and internal fixation using an interlocking plate system has gained popularity for the treatment of dorsally displaced distal radius fractures. The aim of the study was to assess how adequately distal radial fracture reduction was reproduced and maintained with the pre-contoured distal radius Indian locking plates and to evaluate the functional and radiological results of treating unstable distal radius fractures with the volar locking plate. **PATIENTS AND METHODS:** It was conducted on 20 patients with distal radius fractures who underwent open reduction, internal fixation using the pre-contoured distal radius Indian locking plates between May 2012 and September 2013 at the our Hospital. The preoperative, intra-operative, and postoperative films were reviewed. The AO classification was recorded. The volar angulation, radial tilt, radial height and step-off in joint incongruity were measured on intra-operative X-rays and compared with final follow-up X-rays. The last recorded range of motion at follow-up and a functional assessment using Gartland and Werley criteria. **RESULTS:** Radiological review showed bone healing in 20 patients and good articular congruity for all intrarticular fractures with less than 1 mm step-off. Complications were few with two wound infection and one neuropraxia of the superficial radial nerve. Wrist function was excellent in seven (35%) patients, good in 10 (50%) and fair in three (15%). **CONCLUSION:** The pre-contoured distal radius Indian locking plates with its distal buttressing ability are an effective treatment method in patients with distal radius fractures.

**KEYWORDS:** Distal Radius Fracture, Indian Locking Plates, Pre contoured.

**INTRODUCTION:** Distal radial fractures are the most common upper extremity fracture and account for 15% of all fractures.<sup>1,2</sup> Since Abraham Colles' first description in 1814, their treatment has continually evolved, with open reduction and internal fixation (ORIF) using volar locking plate technology becoming increasingly employed with the aim to restore function through anatomical reconstruction of the fracture.<sup>3,4,5</sup>

Fractures of the distal radius are the most commonly treated fracture by the orthopaedic surgeon and are increasing in incidence primarily due to osteoporosis in an ageing population.<sup>6</sup> Achieving anatomical fracture reduction, maintaining this reduction with minimal complications, and expeditious return to pre-morbid function, are the aims of surgical management of these fractures.<sup>7</sup> It is well recognized that in order to achieve good functional results following ORIF, an accurate reconstruction of distal radial anatomy is necessary.<sup>8</sup>

Distal radius fractures associated with small intra- or peri-articular fragments have always been a challenge to management with no consensus as to the best treatment for a given patient or fracture type and often leads to mal-union with loss of function. Traditional stabilization with external splintage (cast) used to be an accepted form of treatment, but the volar lip fragment often slips and fracture reduction is not maintained.

## REVIEW ARTICLE

Bridging external fixation is effective in maintaining reduction after closed manipulation but has associated complications of stiffness, reflex sympathetic dystrophy and metacarpal fractures.<sup>9</sup> The theoretical advantage of locking plates is that they are able to obtain a good hold in osteoporotic bone and allow early postoperative rehabilitation.<sup>10,11</sup>

This is achieved by the creation of a biomechanically stable construct able to withstand significant forces prior to failure.<sup>12</sup> The biomechanical strength of the pre-contoured locking plates lies in its ability to create a three-dimensional scaffold to provide subchondral support for the distal radius articular surface.<sup>13</sup> The use of the pre-contoured distal radius Indian locking plates in the management of these patients has been effective in achieving union and good hand function. We present our experience in the use of this buttress plate in this study.

**PATIENTS AND METHODS:** We evaluated a consecutive series of 20 adult patients treated with the pre-contoured distal radius Indian locking plates at our institution from 2012 to 2013. All patients that required surgery for a distal radius fracture were included, even those with other wrist, hand, or forearm injuries. The preoperative films, intra-operative films, and postoperative films, were reviewed.

Patients were counseled and treatment options explained. The decision for surgical reduction was based on informed consent. They were operated on and managed by the senior author of the paper. We classified the fractures according to the AO system<sup>14</sup> (Table 1). There were 11 females and 9 males in our study with age ranging from 27 to 79 (mean 47.1) years old. There were 11 right and 9 left wrist fractures with 55% occurring on the dominant limb (Table 2).

We measured four radiological parameters as predictors of outcome. These were the volar angulation, radial tilt, radial height and step-off in joint incongruity.<sup>15</sup> Finally, an assessment of function using the Gartland and Werley evaluation score was performed for all patients.<sup>16</sup>

**OPERATIVE TECHNIQUE:** The fractures were exposed using Henry's approach as described for volar plating of the distal radius.<sup>17</sup> Check radiographs intra-operatively to confirm lunate fossa reduction with anatomical tilt lateral views at 20-30 degrees were used to ensure there was no intra-articular screw penetration. The patients were immobilized in plaster for two weeks postoperatively until sutures were removed, and then a further two weeks based upon the decision of the operating surgeon of the stability of fixation intra-operatively. Drains were not routinely used unless intra-operative bleeding was significant. All patients were referred to the occupational therapist for finger and wrist mobilization postoperatively.

AO CLASSIFICATION (23-)	NO. OF PATIENTS	
A 2.1	1	TYPE A (EXTRA ARTICULAR) 5(25%)
A 2.3	2	
A 3.1	1	
A 3.2	1	
B 1.1	1	TYPE B (PARTIALLY ARTICULAR) 4(20%)
B 3.2	1	
B 3.3	2	
C 1.1	1	TYPE C (COMPLETE ARTICULAR)
C 1.2	1	

## REVIEW ARTICLE

C 2.1	4	11(55%)
C 2.2	2	
C 3.1	1	
C 3.3	2	

**Table 1 Fracture Type as per AO Classification**

**RESULTS:** The average operating time was 70 minutes (40 –120) and the average post-operative stay was 3 days (1–7 days). Only two patient with fracture configuration of AO C2.2 required iliac crest bone graft. The preoperative radiological index was measured. The follow-up period was 12 months.

All fractures united clinically and on radiographs. The range of movement and radiological index are reported in Table 3. All patients had a volar angulation of between 0–20° (Mean 8.2), a radial tilt of between 11–25° (mean 17.9) and a height of between 5 to 15 mm (mean 9.65).

Five patients had step off of 1 mm; none of the patients had a step-off greater than 1 mm. Post-operative complications were few. Two patient developed superficial wound infection, which required only saline dressings.

The infection resolved with 6 days. One patient complained of numbness over the distribution of the superficial radial nerve, probably due to traction on the nerve. They recovered after conservative treatment. Functional assessment was performed using the Gartland and Werley's functional evaluation in all patients. 7 patients (35%) scored excellent, 10 (50%) scored good and 3 (15%) scored fair (Table 3).

**DISCUSSION:** Volar rim fractures are infrequent, constituting between 1.5 and 10.5% of distal radius fractures.<sup>18</sup> They are intrinsically unstable due to the obliquity of the fracture line and loss of carpal support. Closed reduction may sometimes lead to further displacement due in part to the strong proximal pull of extrinsic flexor mass. Furthermore, reduction manoeuvres pull the fracture fragment apart from the metaphyseal flare and fail to restore articular congruity.<sup>19</sup>

The use of the pre-contoured distal radius Indian locking plates gives a highly satisfactory reduction of the fracture at the time of surgery and a good maintenance of that reduction to final follow-up. Our study has equivalent range of movement, and better maintenance of fracture reduction than a similar study using another type of volar locking plate for distal radius fractures.<sup>20</sup> The radiographic findings are comparable to the series where the mean volar tilt were 6 degrees and radial inclination 20 degrees.

Radial shortening averaged less than 1 mm in that series. The postoperative range of movement achieved in our study is also equivalent to the reported original series, by Orbayet al and a study by Frattini et al., which also showed similar radiological parameters to our study.<sup>13,21</sup> Knirk and Jupiter had reported that articular incongruity was the most critical factor in subsequent development of arthritis. A step-off of  $\geq 2$  mm is prone to arthritis.<sup>22</sup> In our patients, articular congruity was restored and maintained in all intra-articular fractures with eventual step-off  $\leq 1$  mm.

No.	Sex /Age	Fracture Configuration	Injury Mechanism	Follow-up Period (mth)	Gartland and Werley's Assessment	Complications
1	M/61	A 3.2	RTA	12	Good	-
2	F/35	B 1.1	Fall	12	Excellent	-
3	F/52	C 2.1	Fall	12	Excellent	-

## REVIEW ARTICLE

4	M/31	C 1.2	RTA	12	Good	-
5	F/47	B 3.2	RTA	12	Excellent	Infection
6	M/40	C 2.2	RTA	12	Fair	Numbness
7	M/41	C 3.3	Fall	12	Good	-
8	F/42	A 2.1	RTA	12	Good	-
9	F/62	C 1.1	Fall	12	Good	-
10	M/47	B 3.3	RTA	12	Excellent	-
11	F/52	A 2.3	Fall	12	Fair	-
12	F/79	C 2.2	Fall	12	Fair	Infection
13	M/33	A 2.3	Fall	12	Good	-
14	F/47	C 3.1	Fall	12	Good	-
15	M/54	A 3.1	RTA	12	Excellent	-
16	M/27	C 2.1	Fall	12	Good	-
17	F/44	C 2.1	Fall	12	Good	-
18	M/51	B 3.3	RTA	12	Excellent	-
19	F/38	C 3.3	Fall	12	Good	-
20	F/59	C 2.1	Fall	12	Excellent	-

**Table 2: Bio Data, Fracture Configuration with Injury Mechanism, Follow-up and Clinical Assessment**

We did not have any development of arthritis in our early follow-up. The range of volar tilt between 0 –14° was within acceptable range as proposed by McQueen.<sup>23,24</sup> The plate was used in a variety of ages including osteoporotic fractures with good success.

Patient reported outcome measures following distal radius fractures have been shown to approach normal at six months, with small improvements continued to one year.<sup>25</sup> In a comparison study between old and young patients a good maintenance of radiographic reduction was noted in both populations at 12 months. The younger patients mean recovery was six months and the older patient was 12 months.<sup>26</sup>

Knox et al. compared the biomechanics of the crossed k-wire technique of Clancey and the pre-contoured distal radius locking plates for fixation in unstable distal radial fractures, with the locking plate being significantly more stable with physiological loading.<sup>27,28</sup> No displacement or slipping occurred with the plates compared with the pinning. This suggests early aggressive rehabilitation is not going to displace the fracture.

In our study patients spent a maximum of four weeks in cast immobilization, with early rehabilitation initiated promptly. As use of the plate increased this was reduced to only two weeks cast immobilization to allow wound healing only. Early mobilization had no deleterious effect on outcome.

A concern with the use of these plates is a high complication rate, with studies in the literature reported to be 8% to 27%.<sup>29</sup> Our study had a complication rate of 15%. We had one patient with numbness of superficial radial nerve distribution and two patients developed superficial wound infection. The patient reported recovery of the superficial radial nerve in the post-operative period and the neuropraxia is likely due to excessive stretch in trying to visualize and apply the implant along the articular surface of the radius. This complication may be decreased by an extended incision to further mobilize the soft tissue and nerve distally.

## REVIEW ARTICLE

However, we had no flexor tendon injuries in our study which is in marked contrast to the 57% of complications reported by Arora et al.<sup>20</sup>

No.	Sex/ Age	Fracture Configuration	Volar Angulation	Radial Tilt	Radial Height	Step- off	Dorsiflex- plantar flexion	Radial to Ulna Deviation	Pronation to Supination	Gartland and Werley's Assessment
1	M/61	A 3.2	14	23	10	0	50-0-50	35-0-40	80-0-90	Good
2	F/35	B 1.1	3	15	9	0	60-0-80	20-0-25	90-0-90	Excellent
3	F/52	C 2.1	6	16	6	1	80-0-65	15-0-15	90-0-90	Excellent
4	M/31	C 1.2	12	18	10	0	80-0-60	15-0-20	90-0-80	Good
5	F/47	B 3.2	10	21	7	0	70-0-85	30-0-25	80-0-80	Excellent
6	M/40	C 2.2	20	23	15	1	60-0-50	10-0-15	60-0-70	Fair
7	M/41	C 3.3	14	20	11	0	60-0-80	25-0-15	80-0-70	Good
8	F/42	A 2.1	6	23	10	0	50-0-60	20-0-15	80-0-80	Good
9	F/62	C 1.1	16	15	9	1	60-0-80	20-0-20	90-0-90	Good
10	M/47	B 3.3	2	13	7	0	55-0-75	20-0-20	90-0-90	Excellent
11	F/52	A 2.3	17	22	14	0	50-0-60	10-0-15	60-0-80	Fair
12	F/79	C 2.2	13	25	15	0	60-0-40	15-0-15	70-0-70	Fair
13	M/33	A 2.3	5	20	10	0	45-0-45	20-0-15	70-0-80	Good
14	F/47	C 3.1	9	18	11	0	40-0-40	15-0-15	60-0-60	Good
15	M/54	A 3.1	0	13	5	1	90-0-60	20-0-15	90-0-90	Excellent
16	M/27	C 2.1	0	15	8	0	60-0-50	10-0-10	80-0-70	Good
17	F/44	C 2.1	0	14	9	1	55-0-50	20-0-25	80-0-80	Good
18	M/51	B 3.3	7	11	7	0	80-0-70	20-0-20	90-0-90	Excellent
19	F/38	C 3.3	10	21	12	0	70-0-55	15-0-15	80-0-90	Good
20	F/59	C 2.1	0	12	8	0	90-0-70	30-0-30	90-0-90	Excellent

**Table 3: Final Radiological Measurements and Final Clinical Measurements of Patients' Wrist Movements**

This is most likely due to the design of the pre-contoured distal radius Indian locking plate. This plate is T-shaped and has been pre-contoured to fit the volar surface of the distal radius with separate left- and right sided implants available. It is a fixed angle device, with the location of screws in the plate designed to minimize tendon irritation with correct placement in the distal radius. Technically, the implant is not difficult to use. Surgical approach was similar to the standard volar buttress plate. The accurate placement of distal screws is greatly aided by the image intensifier, which we believe should be a routine in placement of screws. It also negates the need for bone grafting in the majority of patients since it supports the subcondral articular surface and maintain

## REVIEW ARTICLE

---

radial height until bone gap has remodeled. This is very cost effective and suits the Indian scenario with poor patients.

Whilst the study showed that satisfactory fracture reduction can be achieved and maintained using the pre-contoured distal radius locking plate, there was no assessment of associated soft tissue injury in these patients. Varitimidis et al. has shown a high incidence of triangular fibrocartilage complex tears, complete or incomplete scapholunate ligament tears, and lunotriquetral ligament tears.<sup>30</sup> This is an area for further study as the potential effect of additional injuries was not explored in our series.

A study by Arora et al. has shown that in elderly patients over the age of 65 years, the functional outcome and range of motion following a distal radius fracture is not dependent on anatomical reduction at 12 months following injury.<sup>31</sup> Our study has shown that in younger patients, and in those with intra-articular fractures, the locking plate was able to maintain anatomical reduction and lead to highly satisfactory functional outcomes. The best functional outcomes were seen in patients where the fracture reduction was highly maintained by the plate.

**CONCLUSION:** We believe that this implant, with its very distal buttressing effect, provides a stable fixation and gives good functional outcome when used in the treatment fractures in the distal radius. The functional assessment using Gartland and Werley's evaluation score revealed good or excellent outcome in 17/20 (85%). Our results have been encouraging. With its low cost but similar results it's a cost effective alternative in developing countries. The technique has a relatively short learning curve with few complications.

### REFERENCES:

1. Barrie KA, Wolfe SW. Internal fixation for intra-articular distal radius fractures. *Tech Hand up Extrem Surg* 2002; 6 (1): 10–20.
2. Nana AD, Joshi A, Litchman DM. plating of the distal radius. *J Am Acad Orthop Surg* 2005; 13 (3): 159–71.
3. Colles A. On the fracture of the carpal extremity of the radius. *Edinb Med Surg J* 1814; 10: 182–6.
4. Shin EK, Jupiter JP. Current concepts in the management of distal radius fractures. *Acta Chir Orthop Traumatol Cech* 2007; 74 (4): 223–46.
5. Orbay JL, Touhami A. Current concepts in volar fixed-angle fixation of unstable distal radius fractures. *Clin Orthop Relat Res* 2006; 445: 58–67.
6. Ng CY, McQueen MM, What are the radiological predictors of functional outcome following fractures of the distal radius, *J Bone Joint Surg Br* 93: 145–150, 2011.
7. Loveridge J, Ahearn N, Gee C, Pearson D, Sivaloganathan S, Bhatia R. Treatment of distal radial fractures with the DVR-A plate-the early Bristol experience. *Hand Surg.* 2013; 18 (2): 159-67.
8. Graham TJ. Surgical correction of malunited fractures of the distal radius. *J Am Acad Orthop Surg* 1997; 5 (5): 270–81.
9. Lee HC1, Wong YS, Chan BK, Low CO. Fixation of distal radius fractures using AO titanium volar distal radius plate. *Hand Surg.* 2003 Jul; 8 (1): 7-15.
10. Levin SM, Nelson CO, Botts JD, Teplitz GA, Kwon Y, Serra-Hsu F, Biomechanical evaluation of volar locking plates for distal radius fractures, *Hand* 3: 5560, 2008.
11. Musgrave DS, Idler RS, Volar fixation of dorsally displaced distal radius fractures using the 2.4-mm locking compression plates, *J Hand Surg* 30: 743749, 2005.

## REVIEW ARTICLE

---

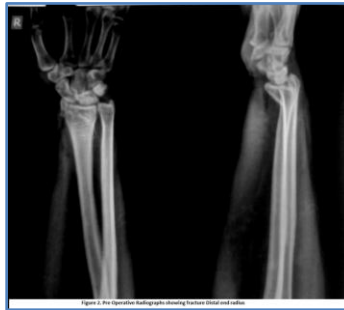12. Sobky K, Baldini T, Thomas K, Bach J, Williams A, Wolf JM, Biomechanical comparison of different volar fracture fixation plates for distal radius fractures, *Hand* 2008;3: 96-101.
13. Frattini M, Soncini G, Corradi M, Panno B, Tocco S, Pogliacomini F, Complex fractures of the distal radius treated with angular stability plates, *Chir Organi Mov* 2009;93:155-162.
14. Muller ME, Nazarian S, Koch P, Schatzker J. *The Comprehensive Classification of Fractures of Long Bones*. Springer-Verlag, 1990: 106 –115.
15. Van Der Linden W, Ericson R. Colles' fracture: How should its displacement be measured and how should it be immobilised? *J Bone Joint Surg* 1981; 63A: 1285–1288.
16. Gartland JJ, Werley CC. Evaluation of healed Colles' fractures. *J Bone Joint Surg* 1951; 33A: 900.
17. Heim ME, Pfeiffer KM. *Internal Fixation of Small Fractures*, 3rd ed. Springer Verlag, 1988:145–178.
18. Mehara AK, Rastogi S, Bhan S, Dave PK. Classification and treatment of volar Barton fractures. *Injury* 1993; 24: 55.
19. Bartosh RA, Saldana MJ. Intraarticular fractures of the distal radius: A cadaveric study to determine if ligamentotaxis restores radiopalmar tilt. *J Hand Surg [Am]* 1990; 15: 18.
20. Arora R, Lutz M, Hennerbichler A, Krappinger D, Gabl M, Complications following internal fixation of unstable distal radius fracture with a palmar locking-plate, *J Orthop Trauma* 2007;21: 316.
21. Orbay JL, Badia A, Indriago I Ret al., The extended flexor carpi radialis approach: a new perspective for the distal radius fracture, *Tech Hand Up Extrem Surg* 5: 2001;204-211.
22. Knirk JL, Jupiter JB. Intra-articular fractures of the distal radius in young adults. *J Bone Joint Surg* 1986; 68A: 647–659.
23. McQueen M, Caspers J. Colles fracture: Does the anatomical result affect the final function? *J Bone Joint Surg* 1988; 70B: 649–681.
24. McQueen M, Hajducka C, Court-Brown CM. Redisplaced unstable fractures of the distal radius. *J Bone Joint Surg* 1996; 78B: 404– 409.
25. Chung KC, Watt AJ, Kotsis SV, Margaliot Z, Haase SC, Kim HM, Treatment of unstable distal radial fractures with the volar locking plating system, *J Bone Joint Surg Am* 2006;88: 2687-2694.
26. Chung KC, Squitieri L, Kim HM, Comparative outcomes study using the volar locking plating system for distal radius fractures in both young adults and adults older than 60 years, *J Hand Surg Am* 2008;33: 809-819.
27. Knox J, Ambrose H, McCallister W, Trumble T, Percutaneous pins versus volar plates for unstable distal radius fractures: a biomechanic study using a cadaver model, *J Hand Surg Am* 2007; 32: 813-817.
28. Clancey GJ, Percutaneous Kirschner-wirefixation of Colles fractures. A prospective study of thirty cases, *J Bone Joint Surg Am* 66: 10081014, 1984.
29. Downing ND, Karantana A, A revolution in the management of fractures of the distal radius?, *J Bone Joint Surg Br* 2008;90:1271-1275,.
30. Varitimidis SE, Basdekis GK, Dailiana ZH, Hantes ME, Bargiotas K, Malizos K, Treatment of intra-articular fractures of the distal radius: fluoroscopic or arthroscopic reduction?, *J Bone Joint Surg Br* 2008;90: 778 -785.
31. Arora R, Lutz M, Deml C, Krappinger D, Haug L, Gabl M, A prospective randomized trial comparing nonoperative treatment with volar locking plate fixation for displaced and unstable

## REVIEW ARTICLE

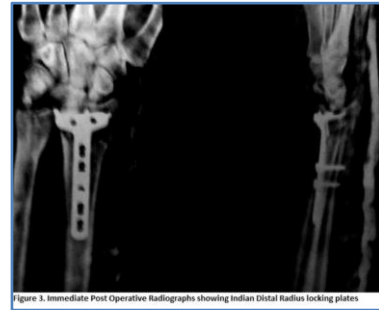
distal radial fractures in patients sixty-five years of age and older, J Bone Joint Surg Am 2011;93 (23): 2146-2153.



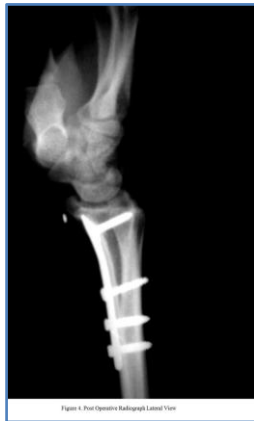**Fig. 1: Distal radius locking Plates used in our study**



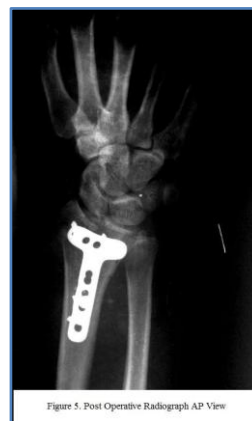**Fig. 2: Pre operative Radiograph showing fracture distal radius**



**Fig. 3: Pre operative Radiographs showing Indian Distal Radius locking plates**



**Fig. 4: Post operative Radiograph Lateral View**



**Fig. 5: Post operative Radiograph AP View**

### AUTHORS:

1. Shaleen Sareen
2. Baljit Singh
3. Aditya Bhardwaj
4. Parminder Viridi
5. Simarpreet S. Bhattal

### PARTICULARS OF CONTRIBUTORS:

1. Assistant Professor, Department of Orthopaedics, SGRDIMSR, Amritsar.
2. Associate Professor, Department of Orthopaedics, SGRDIMSR, Amritsar.
3. Junior Resident, Department of Orthopaedics, SGRDIMSR, Amritsar.
4. Senior Resident, Department of Orthopaedics, SGRDIMSR, Amritsar.

5. Junior Resident, Department of Orthopaedics, SGRDIMSR, Amritsar.

### NAME ADDRESS EMAIL ID OF THE CORRESPONDING AUTHOR:

Dr. Aditya Bhardwaj,  
# 27-C, Sant Avenue,  
The Mall, Amritsar,  
Punjab, India-143001.  
Email: dradityabhardwaj@gmail.com

Date of Submission: 04/11/2014.  
Date of Peer Review: 05/11/2014.  
Date of Acceptance: 12/11/2014.  
Date of Publishing: 17/11/2014.