

TREATMENT OF CLOSED TIBIAL PILON FRACTURES WITH OPEN REDUCTION, INTERNAL FIXATION AND BONE GRAFTING. A STUDY OF 22 CASES COMPARING THE OBJECTIVE AND SUBJECTIVE EVALUATION

Athmaram M¹, B. Jayachandra Reddy²

HOW TO CITE THIS ARTICLE:

Athmaram. M, B. Jayachandra Reddy. "Treatment of Closed Tibial Pilon Fractures with Open Reduction, Internal Fixation and Bone Grafting. A Study of 22 Cases Comparing the Objective and Subjective Evaluation." *Journal of Evolution of Medical and Dental Sciences* 2015; Vol. 4, Issue 12, February 09; Page: 2058-2066
DOI: 10.14260/jemds/2015/295

ABSTRACT: The cases of twenty two fractures of the ankle joint that involved the tibial plafond were reviewed. The fractures were classified in to five types according to the severity of the injury. Open reduction and internal fixation was performed using one third tubular plate for fibula and recon plate for the tibia. Bone grafting was done to augment the fixation and maintain the reduction. For each fracture treated Objective and Subjective evaluation is done. The objective and subjective scores are compared. With this method we noticed that the Type III & IV fractures also had a good or excellent result.

KEYWORDS: Closed Tibial Plafond Fractures, early fixation, bone grafting, early mobilization, prolonged non-weight-bearing.

INTRODUCTION: Fractures of the distal tibia that involve a significant portion of the weight bearing articular surface and overlying metaphysis are notoriously difficult to treat. They occur when the talus is driven up into the tibial articular surface. In 1905, Lambotte⁽¹⁾ documented open reduction and internal fixation of a fracture involving the supramalleolar tibia. The term tibial pilon was later introduced by the French radiologist Destot⁽²⁾ in 1911, to describe the distal tibial metaphysis, which is shaped like a pharmacist's pestle ("pilon").⁽³⁾ Another French term was contributed to the fracture lexicon for this region by Bonin,⁽⁴⁾ who used the word plafond ("ceiling") to refer to the horizontal distal tibial articular surface.

The defining character of a pilon fracture is involvement of the supraarticular metaphysis, which typically exhibits varying degrees of impaction.⁽⁵⁾ This impaction, combined with comminution, instability, primary articular cartilage damage, and persistent joint surface incongruity, contributes to the uncertain outcome of fractures of the tibial pilon.

Several authors have emphasized the importance of foot position at the time of injury as it relates to the ensuing fracture pattern. If the foot is plantar flexed, compressive forces are directed posteriorly, resulting in separation of a large posterior tibial fragment. With a neutral foot, purely vertical forces lead to involvement of the entire articular surface, or creation of a Y-shaped fracture with large anterior and posterior fragments. Should the foot be forced into dorsiflexion, the broader anterior portion of the talus becomes engaged snugly in the ankle mortise. This may result in compression and fracture of the anterior tibial margin, which often produces a large anterior fragment. (Fig. 1)

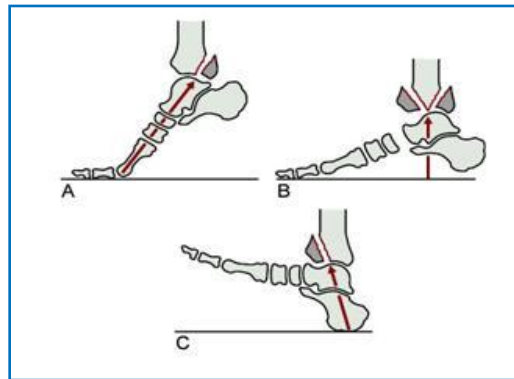


Figure 1

The fracture pattern is influenced by two main forces acting either separately or together. Axial compression occurs as the talus is driven into the tibial plafond. In addition, a rotational component creates shear forces, producing variable degrees of fracture fragment separation. The more impacted or complex the fracture of the tibial metaphysis, the more likely the presence of axial malalignment.⁽⁶⁾ An associated fibula fracture occurs in approximately 75 to 85% of cases.^{89, 122, 147} Its presence implicates valgus shear forces, which usually result in damage to the lateral articular surface and valgus deformity.^(7,8,9)

The system proposed by Ruedi and Allgöwer is descriptive.^(8,9,10) Maale and Seligson modified Ruedi's scheme by identifying a spiral fracture of the distal tibial diaphysis with intra-articular extension as a separate injury.⁽¹²⁾

Type I: Non-displaced articular fracture.

Type II: Minimally displaced articular fracture.

Type III: Displaced articular fracture with large fragments.

Type IV: type III + Large metaphyseal defect.

Type V: Displaced articular fracture with gross comminution.

Before 1963, the reported outcomes of surgical treatment for severely comminuted and impacted fractures of the distal tibial articular surface were of dismal. Good results were achieved in only 43 to 50% of cases. Frustrated with the typical surgical results, Jergesen⁽¹³⁾ described these fractures as “not being amenable to internal fixation.” Therefore, a preference for non-operative treatment was established. In 1963, the AO/ASIF group introduced its principles of open reduction and internal fixation (ORIF).^(14,15) From these initial guidelines for operative fixation have evolved the present-day “biologic principles,” which emphasize meticulous soft tissue dissection, limited stripping of fracture fragments, indirect reduction techniques, and stable fixation^(16,17) followed by early motion with delayed weight bearing.

MATERIAL AND METHODS: This is a prospective study of 22 cases of closed fractures of the tibial pilon from Jan 2000, at the Medical College Hospital – Anantapur.

INCLUSION CRITERIA:

- Closed fractures of tibial plafond.
- Patients of all ages.
- Fresh fractures only.
- Patients with blisters with clear fluid.
- Patient with associated injuries elsewhere in the skeletal system.

EXCLUSION CRITERIA:

- All open fractures.
- Patients with associated injuries in the foot (calcaneal or with talar fractures).
- Patients who had a trail of conservative treatment in our hospital or outside.
- Patients with blisters having bloody fluid (indicates complete separation of epidermis from dermis).
- Patients with poor quality bone stock.

A detailed history regarding the mode of injury and the time since injury is taken. History includes searching for medical problems like diabetes mellitus, peripheral vascular disease, neuropathy and alcoholism. These were given importance as they influence the healing of the wound.

The amount of swelling, presence of distal pulses and the neurological status are carefully assessed. Severe pain, first web space sensory changes, and weakness of toe dorsiflexion suggest a developing anterior compartment syndrome. Sub-clinical signs are more likely in the slowly progressing deep posterior compartment syndrome, which can be confirmed by pain on passive toe dorsiflexion, weakness of toe flexion, and plantar hypoesthesia. All these are carefully looked for.

A slab is applied and the limb is elevated on a Bholer-Braun splint. In co-operative patients calcaneal traction is applied. If the initial swelling is more the slab is avoided.

During the first 12 hours, the initial swelling is caused by fracture hematoma and the effect of shortening on the extremity. After 8 to 12 hours, swelling is primarily caused by intra-dermal edema, which increases the likelihood of postoperative wound problems.^{89, 126} This edema is perhaps the single most important factor to control for successful wound healing.

Blood investigations are carried out and adequate blood is kept ready for the surgery. X-rays are taken and the fractures are classified according to the system advocated by Ruedi and Allgöwer.

Tourniquet is used in all cases. The standard surgical approach for the pilon, the two incision technique is used. Fibula is approached thru the postero-lateral approach. Tibia is approached thru the antero-medial approach. A minimum of 7-8 cm of skin bridge is left in between the two incisions. Full thickness flaps are raised, maintained and retracted with minimal trauma.

The following principles are adhered to, strictly in every case.

- (1) Restoration of fibular length with a one third tubular plate,
- (2) Anterior ankle arthrotomy for restoration of articular surface,
- (3) Restoration of lateral articular and metaphyseal fragment,
- (4) Restoration of central fragment,
- (5) Supporting bone graft,
- (6) Restoration of medial pillar(column),

ORIGINAL ARTICLE

- (7) Medial plating with a recon plate,
- (8) Early motion, and
- (9) Delay in weight bearing.

The wounds are closed primarily. The limb is elevated on the Bholer-Braun splint till the sutures are removed.

POST-OPERATIVE MANAGEMENT: Appropriate antibiotics and adequate analgesics are administered. Early passive mobilization of the ankle is started. Check x-rays are taken after the procedure. Alternate sutures were removed on the 10th day and on the 14th day all the sutures are removed.

Patients were discharged with advice on non-weight bearing walking and active ankle and foot exercises. They were reviewed once in 6 weeks and check x-rays taken in each review. Weight bearing was allowed after an average of 14 weeks (three and half months). All the patients were reviewed in may 2003.

The objective and subjective evaluation was done using the criteria laid down by D. N. Ovadia and R. K. Beals ⁽¹⁸⁾

OBJECTIVE EVALUATION:

RESULT	CRITERIA	SCORE
Excellent	ROM of ankle and subtalar joints is >75% of the normal side, no tibial shortening, no equinus or calcaneus deformity.	4
Good	ROM of ankle and subtalar joints is between 50-75% of the normal side, no tibial shortening, no equinus or calcaneal deformity.	3
Fair	ROM of ankle and subtalar joints in between 25-50% of the normal side, < 1 cm tibial shortening, no equines or calcaneal deformity.	2
Poor	ROM of ankle and subtalar joint is between 0-25% of the normal side, > 5° of varus or valgus or recurvatum deformity, >1 cm tibial shortening, equines or calcaneal deformity.	1

SUBJECTIVE EVALUATION: This depends on the patient's subjective report of pain and performance.

RESULT	CRITERIA	SCORE
Excellent	No pain, returned to previous level of activity, no limp.	4
Good	Mild pain only after strenuous activity, returned to previous level of activity, required occasional analgesics.	3
Fair	Moderate pain, patient could not go to previous level of activity, had to take analgesics daily, limp present.	2
Poor	Pain with each step, unable to work, severe limitation of walking, limp present.	1

ORIGINAL ARTICLE

OBSERVATION: This study is concerned with the management of closed fractures of the lower end of tibia and fibula which also involved the ankle joint. This study has a particular interest in the measurement of the subjective and objective results. This is a prospective study from April 2000 with an average period of follow up is 20 months.

Twenty two patients were studied in this prospective study. Fifteen (68%) were male and rest seven (32%) were female. The average age was 38.7 years with the youngest being 21 years and the oldest was 74 years.

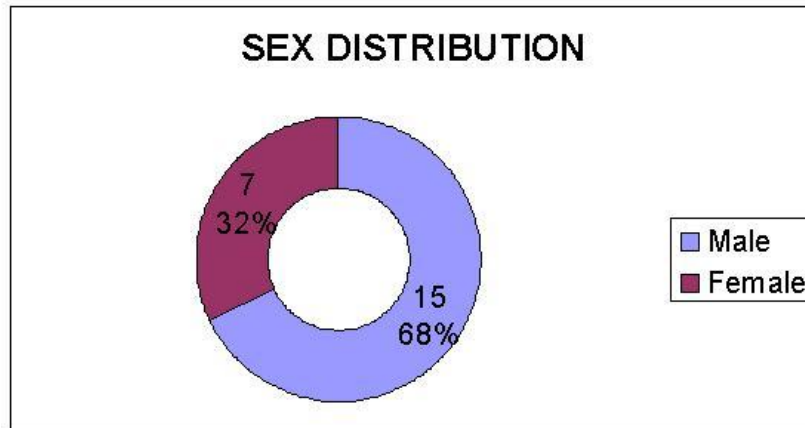


Figure 2

The fractures were caused either by RTA (8), fall at home (10) or by the ankle getting in the cattle trap (4). Ten of them were put on calcaneal traction and the rest 12 were given only limb elevation on a Bholer Braun split pre-operatively.

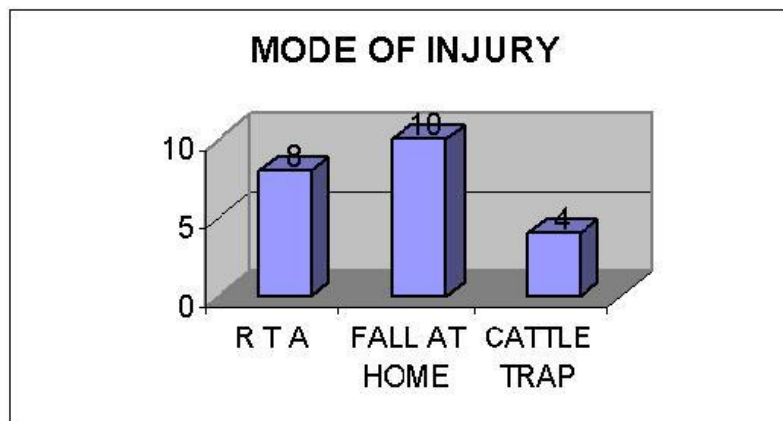


Figure 3

Majority of the fractures were of Type II and III with both being equal in number. Six were of Type IV and two were of Type V.

ORIGINAL ARTICLE




Figure 4

The patients were operated only after the swelling had subsided. Blebs with clear fluid were punctured with a needle and let to dry before operating. Blebs with bloody fluid were treated with pre-operative antibiotics, dressings and waited till new epithelium formed. After the whole thing became dry, the patient was operated upon.

Spinal anesthesia was administered in all patients. Tourniquet was used in all the patients. Post-operative limb elevation was compulsory for all.

RESULTS: In July 2003 all the patients were summoned and reviewed. The subjective and objective results were assessed. Twelve out of twenty two patients had a good objective result. Although only three of them had an excellent objective result, seven of them did excellent subjectively.

All the fractures took an average of five months to unite. It was seen that only two patients had a poor result. They were of the type IV and V, aged more than 70 years and had osteoporosis.

OBJECTIVE RESULTS:

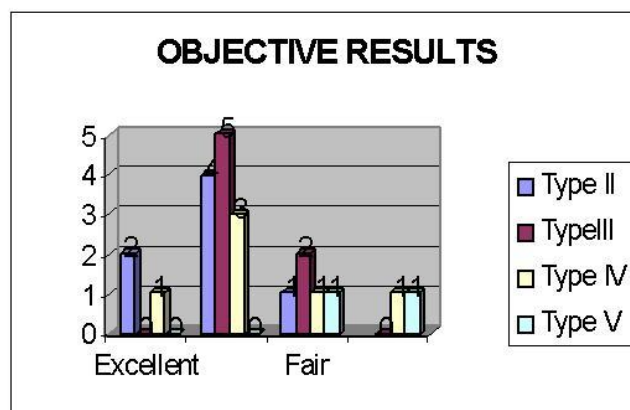


Figure 5

It is noticed that it is difficult to achieve and maintain a good reduction in Type IV & V fractures. They invariably have shortening of around 1cm. type IV fractures tend to go into mild

ORIGINAL ARTICLE

angulations as the metaphyseal defect is large. This is especially so if the patient is aged and osteoporotic. Type II & III fractures perform well in terms of achieving and maintaining the reduction. The poor results were found in patients who were old and alcoholics.

The most important factors that seemed to influence the final result were type of fracture, amount of comminution, quality of the bone and associated medical problems like diabetes and alcoholism

SUBJECTIVE RESULTS:

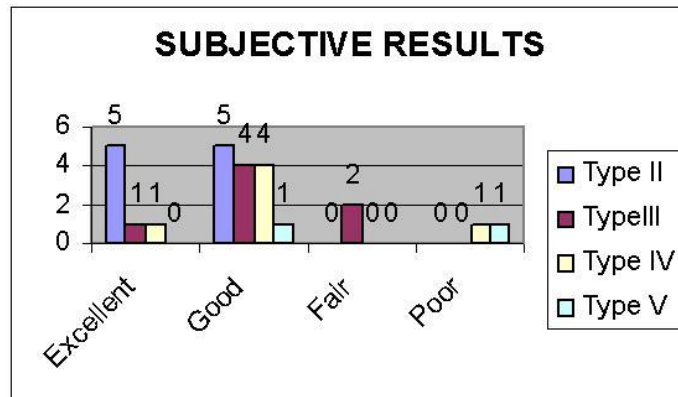


Figure 6

All the Type II fractures had excellent and good result. The articular surface was well maintained and the final R O M was near normal. Among the Type III fractures, fair results were seen in two patients. They were aged 48 & 50. There was limitation of dorsiflexion and plantar flexion. Due to the valgus angulation the pain was present.

Type IV fractures did well in younger age group with results good to fair. The patient who was 74 years old did badly. He has arthritis of the ankle joint and also had superficial infection due to concomitant diabetes. Type V fracture did badly in the old. In the patient who was aged 36 years the result was good though there was 1 cm shortening.

COMPLICATIONS:

Superficial Infection	6
Compartment Syndrome of Tarsal Tunnel	4
Tibial Shortening \geq 1cm	7
Ankle joint Arthritis	1
Malunion (Angulations)	3

CONCLUSION:

- The fractures of tibial plafond are seen in all age groups.
- Patients, who are old, sustain these fractures with minimal trauma.
- Quality of the bone is a very important factor in maintenance of reduction and union.

ORIGINAL ARTICLE

- Type III & Type II fractures which had around 1 cm of shortening also had good subjective results because the ankle mortise is maintained.
- Bad fractures (Type IV & V) had good subjective results in young.
- Early motion is associated with better results.
- A delay in open reduction did not influence the result.
- Patients who were more than 50 years obtained results that were equal to those of younger patients.
- All the patients who had good objective results invariably had good subjective results.

When there is a plafond fracture, patient wait for the swelling to come down, rigid internal fixation and bone grafting and delayed weight bearing always give a good result irrespective of the age of the patient. The most important variable influencing the result is the quality of the bone, age of the patient and associated factors like diabetes and alcoholism.

REFERENCES:

1. Lambotte, A. Chirurgie operative des fractures. French. Paris, Masson, 1913.
2. Destot, E. Traumatismes du Pied et Rayons x Malleoles: Astragale, Calcaneum, Avant-pied. French. Paris, Mason, 1911.
3. Fekete, G. [Pilon or Pylon?] Hungarian. Letter. Magyar Traumatol Ortop Helyreallito Seb 34: 236, 1991.
4. Bonin, J. G. Injuries to the Ankle. London, William Heinemann, 1950, pp. 248-260.
5. Trafton, P.G.; Bray, T.J.; Simpson, L. A. Fractures and soft tissue injuries of the ankle. In: Browner, B.; Jupiter, J.; Levine, A.; Trafton, P.G., eds. Skeletal Trauma, Vol. 2. Philadelphia, W.B. Saunders, 1992, pp. 1931-1941.
6. Heim, U. The Pilon Tibial Fracture: Classification, Surgical Techniques, Results. Philadelphia, W.B. Saunders, 1995.
7. Mast, J.W.; Spiegall, P.G.; Pappas, J.N. Fractures of the tibial pilon. Clin Orthop 230:68-82, 1988.
8. Ruëdi, T.; Allgöwer, M. Fractures of the lower end of the tibia into the ankle joint. Injury 1:92-99, 1969.
9. Trafton, P.G.; Bray, T.J.; Simpson, L.A. Fractures and soft tissue injuries of the ankle. In: Browner, B.; Jupiter, J.; Levine, A.; Trafton, P.G., eds. Skeletal Trauma, Vol. 2. Philadelphia, W.B. Saunders, 1992, pp. 1931-1941.
10. Ruëdi, T.P.; Allgöwer, M. The operative treatment of intra-articular fractures of the lower end of the tibia. Clin Orthop 138:105-110, 1979.
11. Ruëdi, T.; Matter, P.; Allgöwer, M. Die intra-artikularen frakturen des distalen unterschenkelendes. German. Helv Chris Acta 35:556, 1968.
12. Maale, G.; Seligson, D. Fractures through the distal weight-bearing surface of the tibia. Orthopedics 3:517-521, 1980.
13. Jergesen, F. Open reduction of fractures and dislocations of the ankle. Am J Surg 98:136, 1959.
14. Allgöwer, M.; Müller, M.E.; Willenegger, H. Technik der Operativen Frakturbehandlung. New York, Springer-Verlag, 1963.

ORIGINAL ARTICLE

15. Müller, M.E.; Allgöwer, M.; Schneider, R.; Willenegger, H. Manual of Internal Fixation: Techniques Recommended by the AO Group, 2nd Ed. New York, Springer-Verlag, 1979, pp. 146, 147, 208–210, 214–215, 586–612.
16. Mast, J.W.; Spiegel, P.G.; Pappas, J.N. Fractures of the tibial pilon. Clin Orthop 230:68–82, 1988.

AUTHORS:

1. Athmaram M.
2. B. Jayachandra Reddy

PARTICULARS OF CONTRIBUTORS:

1. Associate Professor, Department of Orthopaedics, Government Medical College, Anantapur.
2. Associate Professor, Department of Orthopaedics, Government Medical College, Anantapur.

NAME ADDRESS EMAIL ID OF THE CORRESPONDING AUTHOR:

Dr. Athmaram M,
#13-2-540,
Ramachandra Nagar,
Anantapur-515001,
Andhra Pradesh.
E-mail: athmaramadishes@yahoo.com

Date of Submission: 27/01/2015.
Date of Peer Review: 28/01/2015.
Date of Acceptance: 31/01/2015.
Date of Publishing: 09/02/2015.