

COMPARATIVE STUDY OF PUNCH AND SPLIT THICKNESS GRAFTING IN STABLE LIP VITILIGO PATIENTSG. Srinivasulu¹, D. Subba Rao²**HOW TO CITE THIS ARTICLE:**

G. Srinivasulu, D. Subba Rao. "Comparative Study of Punch and Split Thickness Grafting in Stable Lip Vitiligo Patients". Journal of Evolution of Medical and Dental Sciences 2014; Vol. 3, Issue 58, November 3; Page: 13086-13091, DOI: 10.14260/jemds/2014/3740

ABSTRACT: BACKGROUND: Our study was conducted to prove the efficacy of surgical modalities in vitiligo. **AIM:** To Compare the efficacy of well established, easier and safer punch grafting with split thickness grafting in stable lip Vitiligo patients. **MATERIALS AND METHODS:** patients with stable lip Vitiligo for more than 1 year. **RESULTS:** with punch grafting 5 out of 12 patients and with split thickness grafting 10 out of 12 patients developed more than 75% pigmentation. **CONCLUSION:** Punch grafting is technically less demanding, easier to perform can be done in any kind of setup with minimal equipment but associated with textural abnormalities. Split thickness grafting requires skill, and well equipped OT theatre and gives excellent cosmetic result.

KEYWORDS: Punch grafting, split thickness grafting, donor site, recipient site, pigmentation, graft. margin area.

INTRODUCTION: Vitiligo is a common de pigmenting disorder with incidence between 0.5–2 % causing severe cosmetic distress particularly in darkly pigmented skin leading to psychological trauma, profound impact on quality of life and also associated with social stigma. Though conventional therapies like steroids, phototherapy exists they are not always successful over acral sites. This led to Various Surgical modalities to treat stable Vitiligo. Our present study deals with lip Vitiligo where the disease is very distressing.

AIM: To compare efficacy, acceptability and complications associated with punch and split thickness grafting. The study was conducted in department of dermatology, King George hospital, Visakhapatnam during the period from Nov 1st 2007 to Dec 31st 2010. The study group includes 12 patients for each procedure above 12 years of age having lip Vitiligo for varying duration. The patients were randomly chosen for punch and split thickness grafting.

MATERIALS AND METHODS: Patients with stable Vitiligo for more than 1 year and resistant to medical therapy. Patients with keloidal tendency, bleeding diathesis and seropositivity for HIV and Hbsag were excluded. In all these patients a complete history regarding age at onset, duration, associated conditions like Thyroid, DM, Alopecia areata, pernicious anemia, Addison's disease and cutaneous melanoma.

PRE-OPERATIVE EVALUATION AND COUNSELING: Haemogram, fasting blood sugar, serum creatinine, serum Thyroid stimulating hormone, urine examination for sugar, albumin, microscopy, HIV, and Hbsag. In each case the nature of procedure, benefits and potent complications and consent was taken.

ORIGINAL ARTICLE

EVALUATION OF OUTCOME OF SURGERY: Outcome of surgery was evaluated in terms of area of repigmentation, colour match and textural abnormalities.

PREPARATION: Both donor and recipient sites were cleaned draped and infiltrated with local anaesthesia.

DONOR SITES: Cosmetically invisible sites like thighs, buttocks and post auricular region were chosen.

PUNCH GRAFTING: Punches were taken as close as possible so that more number of punches can be taken from small area. Similar size punches were taken from recipient site and replaced with grafts taken from donor site. Both donor and recipient were covered with chlorhexidine gauze and sterile pads.

SPLIT THICKNESS GRAFTING:

REQUIREMENTS:

- Motor dermabrader.
- Sterilized razor blade.
- Straight artery forceps.
- Sterilized slides.
- Tissue adhesive cyanoacrylate.

PROCEDURE: DONOR SITE: A thin even split thin graft is obtained by razor blade held with straight artery forceps and transferred on to a slide, the graft taken should be 5 mm larger than the recipient site to avoid peripigmentary hollow.

RECIPIENT SITE: The recipient site is dermabraded with burr attached to motor. The dermabrasion is carried at 2000 rpm till fine bleeding points are seen. All the patients were kept on oral antibiotics and advised only oral fluids for 24 hours and strict lip immobilization advised.

FOLLOW UP: All patients were subjected to phototherapy from day 7 for a period of 1 month. Regular Photographs were taken on every visit.

DISCUSSION: Surgical modalities in Vitiligo have come long way in the last 4 decades. Surgical modalities are broadly classified into tissue and cellular grafts. Tissue grafts carry dermis and subcutaneous fat in addition to epidermis. The differentiation, pigmentation and development of epidermal cells are regulated by dermis. In punch grafting both epidermis and dermis are grafted so the graft retains characteristic of donor site hence the pigmentation leading to cosmetic mismatch.

Age group of patients	12-20	20-30	30-40	40-50
Number Of Patients	8	10	4	2

ORIGINAL ARTICLE

SEX DISTRIBUTION:

In our study 12 patients were male and 12 patients were female.
Male to female ratio is 1:1.

DURATION OF SYMPTOMS: The duration of disease ranged from 1-2 years followed by 2-5 years. All the patients except for one patient had lesions on the lower lip.

FAMILY HISTORY: 2 patients had associated hypothyroidism.

COMPARISON BETWEEN PUNCH AND SPLIT THICKNESS GRAFTING: In our study 10 out of 12 patients developed >75% pigmentation with split thickness grafting and 5 out of 12 patients with punch grafting.

COMPLICATIONS:

SPLIT THICKNESS GRAFTING: Out of 12 patients with split thickness grafting 2 patients showed hyperpigmentation and 1 patient showed hypertrophy.

PUNCH GRAFTING: Out of 12 patients with punch grafting 2 patients developed hyperpigmentation and 6 patients showed cobbling.

GRAFT FAILURE RATE:

PUNCH GRAFTING: Graft failure was seen in 2 patients.

SPLIT THICKNESS GRAFTING: Graft failure was seen in 1 patient.

PUNCH GRAFTING: Among various surgical modalities punch grafting has already established its place as the easiest, fastest, safest and least aggressive forms of Vitiligo surgery. Cobbling is a significant problem with punch grafting, we tried to make punches as thin as possible by splicing up the fat from punch after cutting it from donor site but mild cobbling is inevitable. The spread of pigmentation occurs from the margin of graft indicating the graft margin area is the final determinant for area of repigmentation. The duration from surgery to complete re pigmentation was between 45 - 60 days.

SPLIT THICKNESS GRAFTING: Compared to punch grafting split thickness contains whole of epidermis and part of papillary dermis so less hypertrophy and excellent pigment match.

FACTORS INFLUENCING OUTCOME OF VITILIGO SURGERY:

Thickness/depth of the graft.
Graft margin area.

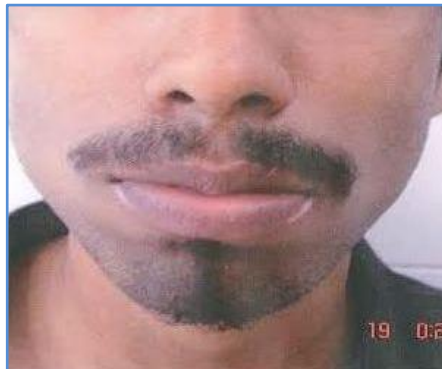Graft margin area is larger for punch grafting compared to split thickness grafting hence large area of de pigmented skin can be covered for the same donor area with punch grafting.

ORIGINAL ARTICLE

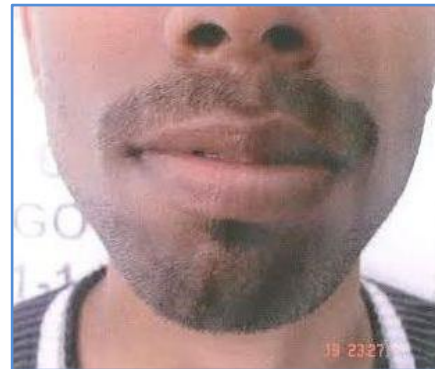
CONCLUSION: Punch grafting is technically less demanding, easier to perform can be done in any kind of setup with minimal equipment but associated with complications like cobbling and hyperpigmentation. Split thickness grafting requires skill, instruments like motor dermabrader, dedicated OT theatre but gives excellent colour match with minimal complications. Split thickness grafting is superior to punch grafting in terms of area of repigmentation, texture and cosmetic acceptability.

REFERENCES:

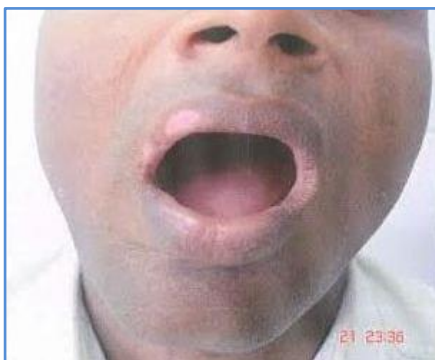1. IADVL text book of dermatology: 3rd ed. 1; 749.
2. Gauthier Y, Cario, Andri M, et al. A critical appraisal of vitiligo etiological theories is melanocyte loss-melanocytorrhagy? Pigment cell res 2003; 16: 322-32.
3. Das SK, manjumdar PP, chakraborty R, et al. studies in vitiligo. I. epidemiological profile in calcutta, India. Genet Epidemiol 1985; 2: 71-8.
4. Lerner ab on etiology of vitiligo and grey hair; am j med 1971; 51; 141-7.
5. Epidermis of patients with vitiligo and its successful removal by a UVB-activated pseudocatalase j investing dermatolsymp proc 1999; 4; 91-6.
6. Koga m, vitiligo: a new classification and therapy. Br j dermatol 1977; 97; 255-61.s



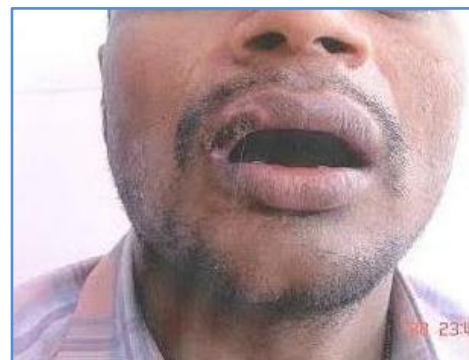Images (Split Thickness Grafting)



3 Months after Surgery

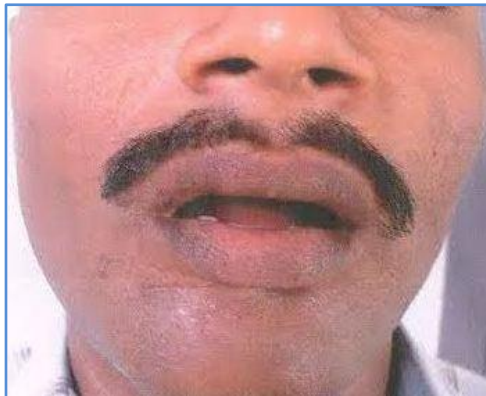

Patient 2 With Split Thickness Grafting

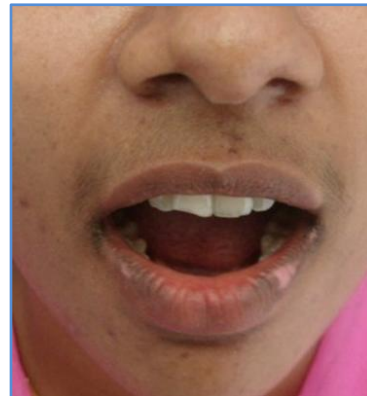

7 days after surgery

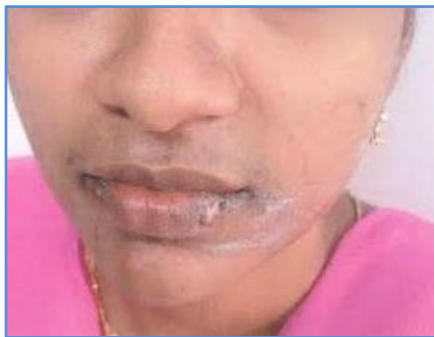ORIGINAL ARTICLE



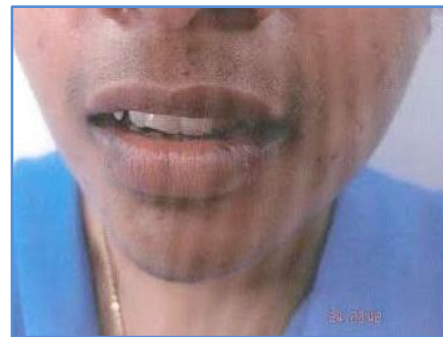3 months after surgery



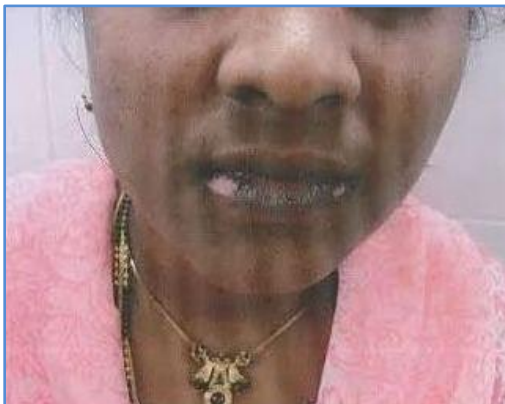Images (Punch Grafting)



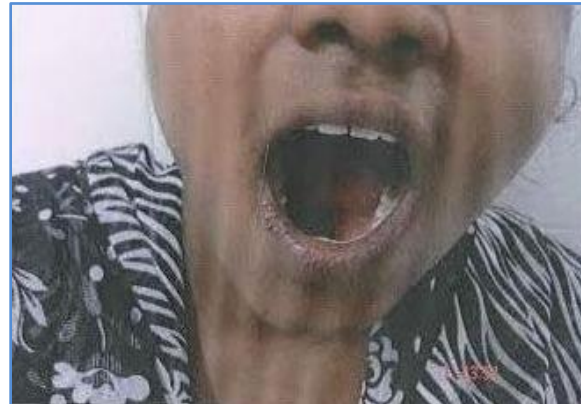7 days after surgery



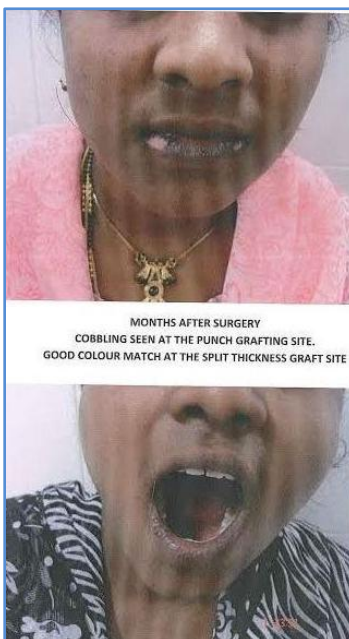3 months surgery



Punch grafting on right side and split Thickness grafing on side



Few months after surgery cobbling at punch grafting site excellent Pigment match at split thickness site



AUTHORS:

1. G. Srinivasulu
2. D. Subba Rao

PARTICULARS OF CONTRIBUTORS:

1. Assistant Professor, Department of DVL, ASRAM Medical College & Hospital, Eluru.
2. Professor, Department of DVL, ASRAM Medical College & Hospital, Eluru.

NAME ADDRESS EMAIL ID OF THE CORRESPONDING AUTHOR:

Dr. Gillela Srinivasulu,
Flat No. 622, Akash Block,
No. 6, Lotus Land Mark,
Ayodhya Nagar, Vijayawada.
Email: sinuela@gmail.com

Date of Submission: 21/10/2014.
Date of Peer Review: 22/10/2014.
Date of Acceptance: 29/10/2014.
Date of Publishing: 31/10/2014.