

## CASE REPORT

### HYPHIDROTIC ECTODERMAL DYSPLASIA: A REPORT OF TWO CASES IN A FAMILY

P. Guru Prasad<sup>1</sup>, M. Parvathi<sup>2</sup>, Krishnarao V. Pasagadugula<sup>3</sup>, S. Jhansi Lakshmi<sup>4</sup>,  
P. V. S. V. P. H. S. Brahma<sup>5</sup>

#### HOW TO CITE THIS ARTICLE:

P. Guru Prasad, M. Parvathi, Krishnarao V. Pasagadugula, S. Jhansi Lakshmi, P. V. S. V. P. H. S. Brahma. "Hypohidrotic Ectodermal Dysplasia: A Report of Two Cases in a Family". Journal of Evolution of Medical and Dental Sciences 2015; Vol. 4, Issue 04, January 12; Page: 716-720, DOI: 10.14260/jemds/2015/103

**ABSTRACT:** Ectodermal Dysplasia (ED) is a rare disorder with defects in two or more of the following structures: the teeth, skin and its appendages including hair, nails, eccrine, and sebaceous glands. Dental manifestations include hypodontia, complete anodontia or malformed teeth. The most common form of the ED is hypohidrotic ED and is usually inherited as an X-linked recessive trait. Female carriers may have a variable degree of clinical manifestations. The condition is thought to occur in approximately 1 in every 100, 000 live births. Dental treatment for these patients varies on an individual basis. Children with ED are often treated for dental problems with conventional adult appearing prosthesis. Here with we are reporting two classical cases of hypohidrotic ED with a review of the literature.

**KEYWORDS:** Ectodermal dysplasia, Genetic disorder, Hypohidrosis.

**CASE REPORT:** A 19-year-old male presented to the Skin Department for decreased sweating and dry skin. Patient gave history of very minimal sweating since childhood associated with heat intolerance. He gave h/o hyperthermia while exposed to sun light. Oral cavity revealed conical teeth. short, sparse and thin hair present over scalp, eyebrow, beard, axilla & pubis. Terminal hairs on trunk and limbs were sparse. The skin was smooth & shiny all over with wrinkling at places. No nail abnormality was seen. Palms & soles were normal with mild alteration in dermatoglyphic pattern. [Table/Fig-1]. Salivation and lacrimation was normal. No Otorhinolaryngological or ophthalmic abnormality was detected. Routine investigations along with LFT, RFT was normal. Skin biopsy shows normal epidermis, with absence of sebaceous and sweats glands. Deep dermis shows thick vessels. [Table/Fig-1]:

- While evaluating family history, his 19-year-old sister also has dental and hair abnormality. Oral cavity shows loss of upper 2 incisors and conical teeth. Hair was short, thin & sparse over scalp, eyebrow, axilla & pubis. [Table/Fig-2].
- Both brother and sister were born of a non-consanguineous marriage and by normal delivery without any complications. Family history was not significant with none of their parents, grandparents affected. Both had normal social, physical, sexual and mental development.

**DISCUSSION:** Ectodermal dysplasias are relatively rare and occur with a frequency varying between 1:10, 000 and 1:100, 000 live births.<sup>[1]</sup> Freire-Maia and Pinheiro<sup>[2]</sup> clinically classified Ectodermal Dysplasias into various subgroups according to defects like trichodysplasia, dental abnormalities, onychodysplasia and dyshidrosis using '1-2-3-4 system'. The most common form of Ectodermal Dysplasias, Christ-Siemens-Touraine syndrome {MIM 305100}, commonly known as anhidrotic/hypohidrotic ectodermal dysplasia (HED), is an X-linked recessive disorder characterized

## CASE REPORT

---

by heat intolerance, absence of sweat glands and abnormal spiky or absent teeth. It was first described in 1848 by Thurnam<sup>[3]</sup> and later in the 19<sup>th</sup> century by Darwin.<sup>[4]</sup> In 1913, Christ characterized it as a congenital ectodermal defect. In 1921, Siemens confirmed the X-linked nature of inheritance & in 1936, Touraine published on the wide range of features.

HED is inherited in an X-linked recessive, autosomal dominant or autosomal recessive manner. A 95% of randomly selected individuals with HED have the X-linked recessive inheritance. The remainders (5%) have either the autosomal recessive or autosomal dominant inheritance. It is fully expressed in males only. Heterozygotic females may be mildly affected. In our cases both brother and sister are affected.

It is caused by mutation in gene ectodysplasin (EDA, EDA1) located at Xq12-13 coding for transmembrane protein, ectodysplasin A.<sup>[5]</sup> HED is a diffuse, non-progressive disease present birth and involves at least two tissues of ectodermal origin. In our cases two tissues of ectodermal origin are affected (teeth and hair).<sup>[6]</sup>

Main clinical feature of HED is sparse or absent eccrine gland as well as hypotrichosis and oligodontia with peg-shaped teeth with incisor and/or canine teeth mainly affected which looks conical and pointed and sometimes is the only obvious abnormality. The absence or diminished activity of sweat gland results in patients having more chances of developing hyperthermia with minimal exertion. Affected infant may present with recurrent fever.<sup>[7]</sup> Our patient also had similar complaints of recurrent high grade fever with intolerance to warm environment. Sparse and often light pigmented scalp hair, eyebrow, eyelashes with nail abnormality is common.

In our cases they show light pigmented sparse hair, eyebrows, eyelashes without nail abnormalities. HED patient have a characteristic faces with frontal bossing, a saddle nose, and full, everted lips. Our patients did not show any facial abnormalities. Abnormal mucous gland results in extreme nasal secretion leading to recurrent respiratory tract infections. Most infants have difficulties in feeding or episodes of severe illness associated with infections commonly pneumonia. This ill health adversely affects their growth and development. Most female carriers of HED are recognised by dental anomalies, and most of those whose teeth are normal may be recognised by their abnormal pattern of sweating.<sup>[8]</sup> In our case female patient showed dental anomaly, absence of sweating and sparse eyebrows and eye lashes.

Histologically, the epidermis is thin and flattened, the eccrine sweat gland are absent or rudimentary. The dermal connective tissue is grossly normal but elastic and collagen fibre may be sparse or fragmented. Mucous gland may be absent in respiratory tract.<sup>[9]</sup> In our study histopathology shows absence of sweat and sebaceous glands.

The management of children and adults with HED is a challenge because of their heat intolerance and their susceptibility to pulmonary infections. Maintenance of cool ambient temperature is vital to prevent hyperpyrexia. Heat intolerance seems to decrease with age due to the development of some ability to sweat in adolescence and adaptation of changed lifestyle. DNA-based mutational analysis now offers the opportunity for prenatal diagnosis of this condition.<sup>[10]</sup>

Most do well with simple measures such as wet clothes, air conditioning, wet bands etc. Dental restoration is of great psychological benefit and early implementation of dentures is very helpful. Early prosthetic therapy for children with ectodermal dysplasia provides a unique opportunity for cooperative effort between the pedodontist and the prosthodontist, as pedodontists are better trained in the psychological management of children. Prosthodontic treatment may

## CASE REPORT

---

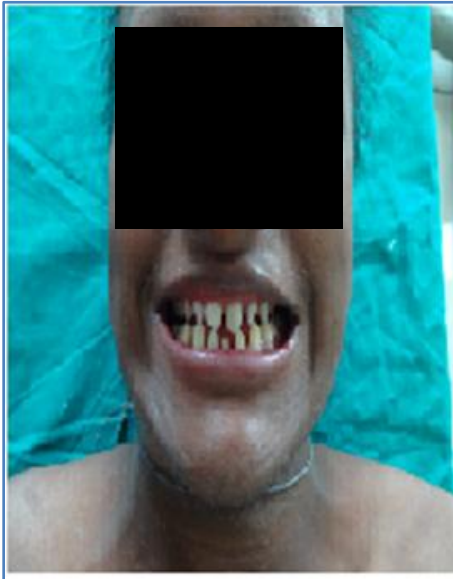commence at an early age of 3-4 y as it enhances conditions for growth and development of orofacial structures.<sup>[11]</sup> Future treatments may involve gene correction or administration of recombinant EDA protein. These two patients were counselled regarding the condition & referred to Dental, ENT departments and advised regarding the lifestyle changes including restriction of physical exertion, choice of occupation to ensure a disease free life. Dental prosthesis was offered and the both were advised regarding regular follow up and to be extra careful during febrile episodes. This presentation of two cases is done due to its rarity and the need for the dermatologist to diagnose such cases at the earliest. It is to be stressed that the counseling of the patients empowers them to get adjusted to the society and helps them live a better life by simple lifestyle modifications.

### REFERENCES:

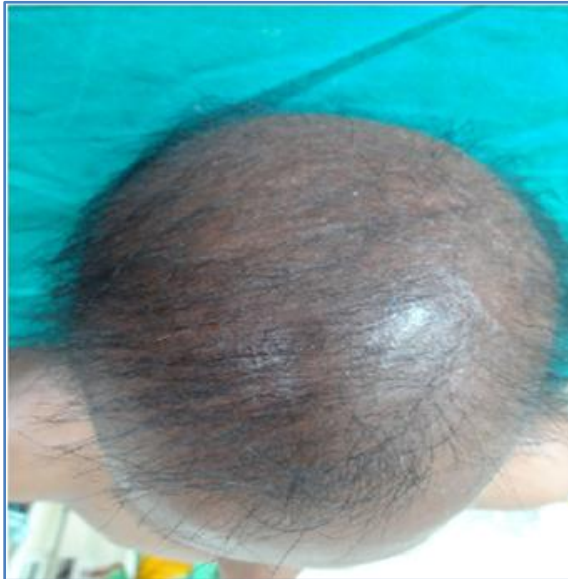1. Vallejo AP, Monje ELA, Garcia MG, Fernandez MM, Buylla FBMA. Treatment with removable prosthesis in hypohidrotic ectodermal dysplasia: a clinical case. *Med Oral Patol Oral Cir Bucal*. 2008; 13: 119–23. [PubMed].
2. Freire-Maia N, Pinheiro M. Ectodermal dysplasia: a clinical classification and a causal review. *Am J Med Genet*. 1994; 53: 153. [PubMed].
3. Thurnam J. Two cases in which the skin, hair and teeth were very imperfectly developed. *Med Chir Trans*. 1848; 31: 71–82. [PMC free article] [PubMed].
4. Darwin C. *The Variations of Animals and Plants under Domestication*. 2<sup>nd</sup> edn. Vol. 2. London: John Murray; 1857. p. 319.
5. Kere J, et al. X-linked anhidrotic (hypohidrotic) ectodermal dysplasia is caused by a mutation in a novel transmembrane protein. *Nature Genet*. 1996; 13: 409. [PubMed].
6. Mokhtari Sepideh, Mokhtari Saeedeh, Lotfi Ali. Christ-Siemens-Touraine Syndrome: A Case Report and Review of the Literature. *Case Reports in Dentistry*. 2012; vol. 2012:3. Article ID 586418. [PMC free article][PubMed].
7. Agrawal S, Gupta S. Hypohidrotic ectodermal dysplasia. *Indian Dermatol Online J*. 2012; 3: 125–27. [PMC free article] [PubMed].
8. Clarke A, Philips DI, Brown R, et al. Clinical aspects of X-linked hypohidrotic ectodermal dysplasia. *Arch Dis Child*. 1987; 62: 989–96. [PMC free article] [PubMed].
9. Mahajan V, Sharma N, Sood A. Ectodermal dysplasias: Severe palmoplantar Hyperkeratosis and Chronic Angular Cheilitis. *Indian J Dermatol*. 2003; 48 (4): 223–28.
10. Zonana J, Schinzel A, Upadhyaya M, et al. Prenatal diagnosis of X-linked hypohidrotic ectodermal dysplasia by linkage analysis. *Am J Med Genet*. 1990; 35: 132–35. [PubMed].
11. Kaul S, Reddy R. Prosthetic rehabilitation of an adolescent with hypohidrotic ectodermal dysplasia with partial anodontia: Case report. *J Indian Soc Pedod Prev Dent*. 2008; 26: 177–81. [PubMed].

## CASE REPORT

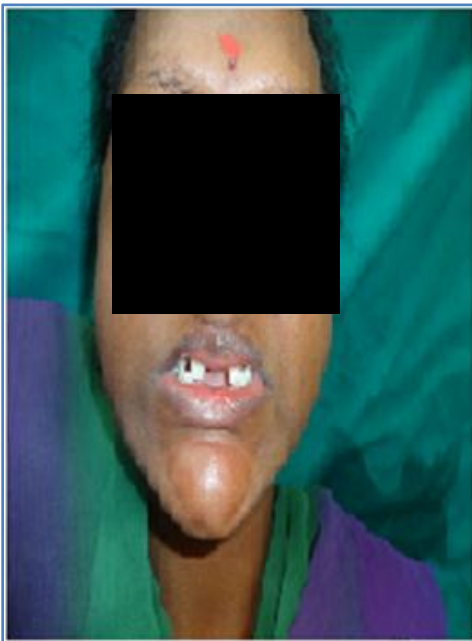---



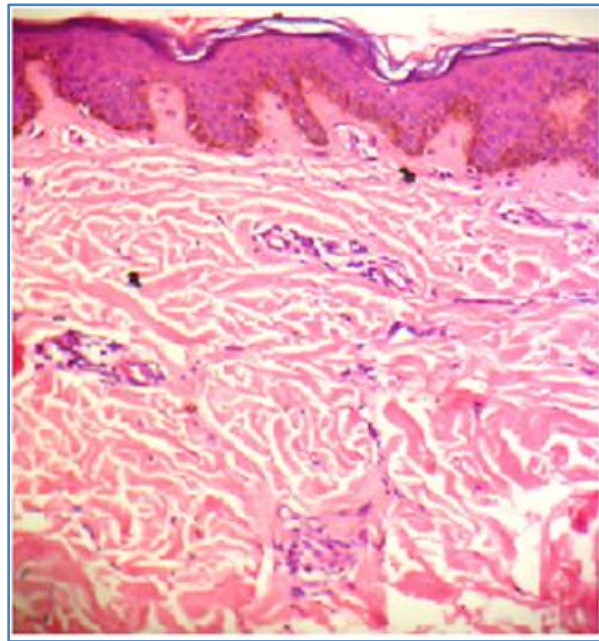
**CONICAL TEETH**



**SPARSE HAIR**



**LOSS OF CENTRAL INCISOR**



**SKIN BIOPSY ABSENCE OF SEBACEOUS AND SWEAT GLANDS**

## CASE REPORT

---

### **AUTHORS:**

1. P. Guru Prasad
2. M. Parvathi
3. Krishnarao V. Pasagadugula
4. S. Jhansi Lakshmi
5. P. V. S. V. P. H. S. Brahma

### **PARTICULARS OF CONTRIBUTORS:**

1. Professor, Department of Dermatology, Andhra Medical College.
2. Professor, Department of Dermatology, Andhra Medical College.
3. Assistant Professor, Department of Dermatology, Andhra Medical College.
4. Assistant Professor, Department of DVL, Andhra Medical College.

5. Junior Resident, Department of DVL, Andhra Medical College.

### **NAME ADDRESS EMAIL ID OF THE CORRESPONDING AUTHOR:**

Dr. P. Guru Prasad,  
Professor,  
Department of Dermatology,  
Andhra Medical College,  
Vizag.  
E-mail: gppatnala@yahoo.co.in

Date of Submission: 25/12/2014.  
Date of Peer Review: 26/12/2014.  
Date of Acceptance: 03/01/2015.  
Date of Publishing: 12/01/2015.