

A CLINICAL STUDY ON CONGENITAL ANOMALIES OF BREAST IN ROHILKHAND REGIONJagadamba Sharan¹, Kaushal Kumar², Md. Arshad Raza³, Vijai Prakash Srivatsava⁴**HOW TO CITE THIS ARTICLE:**

Jagadamba Sharan, Kaushal Kumar, Md. Arshad Raza, Vijai Prakash Srivatsava. "A Clinical Study on Congenital Anomalies of Breast in Rohilkhand Region". Journal of Evolution of Medical and Dental Sciences 2015; Vol. 4, Issue 04, January 12; Page: 525-529, DOI: 10.14260/jemds/2015/78.

ABSTRACT: Congenital anomalies of breast may be unilateral or bilateral, involve either nipple or breast or both. These anomalies may be seen at birth, during childhood, adolescence or during pregnancy. These shall be diagnosed properly and managed accordingly. Most of these anomalies are amenable surgically with excellent results.

KEYWORDS: Breast, congenital anomaly, polythelia, polymastia, accessory nipple, accessory breast.

INTRODUCTION: Congenital anomalies of breast may present as Amastia (Absence of breast tissue) Athelia (Absence of the nipple), neonatal breast hypertrophy, polymastia (Accessory breast tissue) Polythelia (Supernumerary nipples), symmastia (Webbing between the breasts across the midline) Diffuse hypertrophy of the breast, and Tuberosus breast (Breast is elongated from a narrow base to take a sausage-shaped contour, with a disproportionately large and protuberant areola and nipple). Amastia and athelia are rare anomalies. Unilateral rudimentary breast development is much more common, as is adolescent hypertrophy of one breast with lesser development of the other. Here we report 7 cases presenting with congenital anomalies of breast observed over a duration of 6 years of which 3 patients had ectopic breast tissue presenting as axillary swelling, Unilateral supernumerary nipple in 1 patient, one case of bilateral supernumerary nipple, one case with Symmastia and 1 patient with Pubertal hypertrophy of breast.

OBSERVATIONS:

CASE 1: A 25 year old female presented with bilateral axillary swellings for last 5 years. She noticed the swelling during her first pregnancy. She had no complaint of pain or discharge of any type. On examination bilateral non-tender, soft swellings with smooth surface and distinct borders in both axilla were noted. Clinically ectopic breasts were suspected but there was no accessory nipple or areola. FNAC of the bilateral lumps was done which suggested breast tissue. Patient was advised surgery for the same which she refused. (Figure 1A).

**Fig. 1A**

ORIGINAL ARTICLE

CASE 2: A 19 year old female presented with a swelling in the right axilla for past 4 years. The swelling was painless and had gradually increased in size. On examination a well circumscribed non-tender, soft swelling with smooth surface was noted. Clinically lipoma was suspected and the patient underwent excision of the lump. Histopathological examination suggested accessory breast tissue. Postoperative period was uneventful. (Figure 1B)

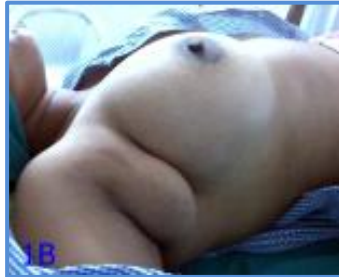

Fig. 1B

CASE 3: A 30 year old female presented with a small lump in the right axilla for past 3 years. The lady noticed the lump during lactation which persisted even after cessation of lactation. On examination a small soft, non-tender lump was noted. FNAC suggested breast tissue. The patient requested for surgery due to fear of cancer, despite of proper counseling she underwent surgery. postoperative period was uneventful. Histopathological examination suggested breast tissue. (Figure 1C).

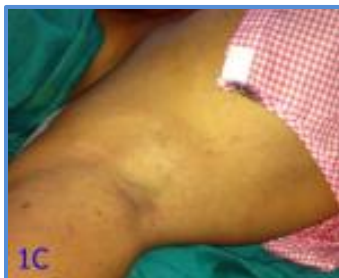

Fig. 1C

CASE 4: A 35 year old lady presented with an extra nipple like lesion below the left breast. On examination it was found to be unilateral supernumerary nipple. Patient was advised operative treatment (Excision) but she refused (Figure 1D).

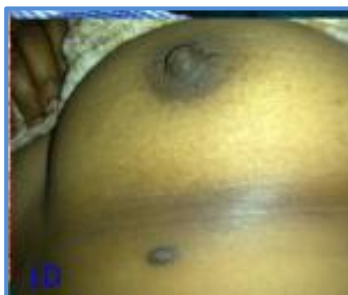

Fig. 1D

ORIGINAL ARTICLE

CASE 5: 63 yrs. Old male presented with retraction of left nipple for past 3 months. The patient was anxious, and worried for possibility of breast cancer. On examination he was found to have bilateral supernumerary nipples, which the patient considered to be birth marks. No evidence of malignancy or, any abnormality was noted. The patient was reassured, no treatment given. (Figure 2A, 2B).

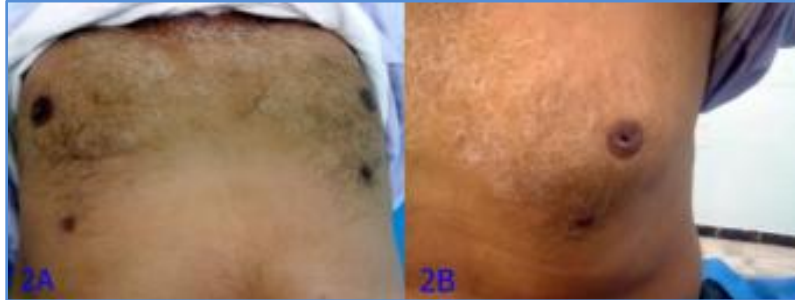


Fig. 2A & B

CASE 6:- 26 yrs. Old married female presented with pain and lump in both breasts for 2 months. On examination ANDI was suspected, incidental symmastia was noted, however the patient was unaware of the condition and was treated conservatively for ANDI.



Fig. 2C

CASE 7: 15 yrs. Old girl presented with bilateral massive enlargement of breasts, which started just after menarche. Both breasts were symmetrically and massively enlarged. On examination both areola were found to be stretched, superficial veins were dilated and on palpation breasts were soft, non-tender with generalized nodularity. The mammary tissue was not fixed to skin or, deeper structures. Clinically a differential diagnosis of diffuse hypertrophy of breast was suspected. Patient was treated medically with Dopamine agonist Cabergolin 0.25 mg once a week for 12 weeks which resulted in reduction in size of breasts on regular monthly follow up.(Figure 3A, 3B).

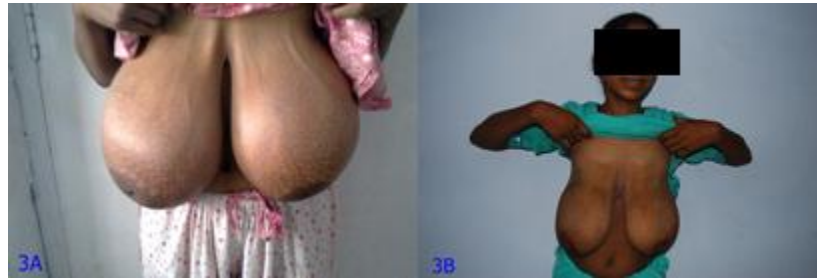

Fig. 3A & B

DISCUSSION: At 5 weeks of gestation, the 2 to 4 cell-layered ectodermal mammary streak develops on the trunk of the embryo.¹ This streak extends from the axilla to the groin bilaterally on the ventral surface. Most of this embryonic mammary line disappears, But a small amount remains bilaterally in the thoracic region. Tissue persisting along this "milk line" is referred to as ectopic, accessory, or aberrant breast tissue.² Accessory nipples may or may not be seen in addition to breast tissue. In women and girls, this tissue responds to the hormonal fluctuations during adolescence, pregnancy and also during the menstrual cycle. Amastia and athelia are rare anomalies.^{3,4} Congenital absence of the breast may occur on one or both sides. It results from an arrest in mammary ridge development. It is more common in males. May be seen as a feature of Poland' syndrome. Polymastia and accessory nipples are both not so common, seen in 2-6% of women.⁵ Accessory (ectopic) axillary breast tissue is the most common type of polymastia, accounting for 60% to 70% of all ectopic breast tissue.⁶ Other infrequently reported locations include the parasternal, subscapular, and vulvar regions. Ectopic axillary breast tissue is most commonly misdiagnosed on physical examination as a lipoma, or an enlarged lymph node. Usually these present as an enlarging mass during pregnancy which can increase in size with subsequent pregnancies.⁷ It develops at puberty secondary to hormonal changes and persists as excess tissue in the axilla. The clinical diagnosis can be confirmed by FNAC or, biopsy. These may be removed surgically if it is large or cosmetically deforming. If the primary complain is pain during pregnancy or, lactation, a conservative approach with subsequent follow up is done.

Supernumerary nipples are usually rudimentary and occur along the milk line from the axilla to the pubis. They may be mistaken for a small mole and are removed only for cosmetic reasons.

Diffuse hypertrophy of the breasts presents at puberty due to an alteration in the normal sensitivity of the breast to estrogenic hormones.⁸ It responds well to medical treatment with antiestrogens (Bromocryptine, Cabergoline etc).⁹ So medical treatment should be considered in these patients. Results of reduction mammoplasty are better after medical treatment. Chances of recurrence are very high when treated only by surgery.

CONCLUSION: Congenital anomalies of breast are under reported, commonly misdiagnosed and may lead to social embarrassment and psychological disturbances. Most of these anomalies are amenable surgically with excellent results. The serious mental, social and emotional disturbances associated with these anomalies mandate a sympathetic approach with proper counseling of the patient regarding the development of breast and it's anomalies and available treatment options.

REFERENCES:

1. Irvin WP, Cathro HP, Grosh WW, Rice LW, Andersen WA. Primary breast carcinoma of the vulva: a case report and literature review. *Gynecol Oncol* 1999; 73: 155-9.
2. Moore KL, Persaud TVN. *The developing human, clinically oriented embryology*, fifth edition. Philadelphia: Saunders, 1998, p.448-9.
3. Trier WC. Complete breast absence. Case report and review of the literature. *Plast Reconstr Surg* 1965; 36:431-9.
4. Lin KY, Nguyen DB, Williams RM. Complete breast absence revisited. *Plast Reconstr Surg* 2000; 106: 98-101.
5. Le Savoy MA, Gomez-Garcia A, Nejdil R, Yospur G, Syiau TJ, Chang P. Axillary breast tissue: clinical presentation and surgical treatment. *Ann Plast Surg* 1995; 35: 356-60.
6. Marshall MB, Moynihan JJ, Frost A, Evans RT. Ectopic breast cancer; case report and literature review. *Surg Oncol* 1994; 3: 295-304.
7. Jordan K, Laumann A, Conrad S, Medenica M. Axillary mass in a 20-year-old woman. *Arch Dermatol* 2001; 137: 1367-72.
8. Drife JO. Breast development in puberty. *Ann NY Acad Sci* 1986; 464: 5865.
9. Sridhar GR, Sinha MJ. Macromastia in adolescent girls. *Indian Pediatr* 1995; 32: 496-499.

AUTHORS:

1. Jagadamba Sharan
2. Kaushal Kumar
3. Md. Arshad Raza
4. Vijai Prakash Srivatsava

PARTICULARS OF CONTRIBUTORS:

1. Assistant Professor, Department of Surgery, Rohilkhand Medical College and Hospital, Pilibhit Bypass Road, Bareilly, UP.
2. Consultant Plastic Surgeon, Eshan Hospital Private Ltd. Rampur Garden, Bareilly.
3. Assistant Professor, Department of Surgery, Rohilkhand Medical College and Hospital, Pilibhit Bypass Road, Bareilly, UP.

4. Assistant Professor, Department of Surgery, Rohilkhand Medical College and Hospital, Pilibhit Bypass Road, Bareilly, UP.

NAME ADDRESS EMAIL ID OF THE CORRESPONDING AUTHOR:

Dr. Jagadamba Sharan,
Assistant Professor,
Department of Surgery,
Rohilkhand Medical College and
Hospital, Pilibhit Bypass Road,
Bareilly, UP-243006.
E-mail: Jsharan76@gmail.com

Date of Submission: 26/12/2014.
Date of Peer Review: 27/12/2014.
Date of Acceptance: 02/01/2015.
Date of Publishing: 09/01/2015.