

## A CADAVERIC STUDY OF VARIATION IN BRANCHING PATTERN OF COELIAC TRUNK IN SOUTH INDIAN POPULATION

Ch. Jayamma<sup>1</sup>, S. K. Vanisree<sup>2</sup>, V. Saila Kumari<sup>3</sup>, G. Rohini Devi<sup>4</sup>

### HOW TO CITE THIS ARTICLE:

Ch. Jayamma, S. K. Vanisree, V. Saila Kumari, G. Rohini Devi. "A Cadaveric Study of Variation in Branching Pattern of Coeliac Trunk in South Indian Population". Journal of Evolution of Medical and Dental Sciences 2015; Vol. 4, Issue 45, June 04; Page: 7848-7851, DOI: 10.14260/jemds/2015/1142

**ABSTRACT: BACKGROUND:** purpose of present study was to describe the variations in the branching pattern of caeliac trunk. Caeliac trunk is one of the ventral branch of abdominal aorta.it arises from the abdominal aorta opposite to intervertebral disc of T12 & L1 vertebrae.it has short course of 1.5 cm after which it terminates by dividing in to three branches splenic artery, left gastric artery and common hepatic artery. Here we report unusual branching pattern of caeliac trunk. Knowledge of such variations in branching pattern of caeliac trunk is very important for surgeons, anatomists and anaesthetists. **METHODS:** The present study is done on 30 cadavers irrespective of sex in department of Anatomy in KURNOOL MEDICAL COLLEGE, Kurnool. According to dissection guidelines of cunnighams practical manual of Anatomy. **RESULTS:** The present study was an attempt to study the occurrence of the branching pattern of the coeliac trunk. The available literature was reviewed. The coeliac trunk took origin from the ventral surface of the aorta in all the 30 specimens. The various patterns were normal hepatolienogastric trunk in 92%, lienogastric trunk in. In one Type I, 2% to Type II, 2% to Type III, 2% to Type IV. The most common pattern of branching of the Coeliac trunk was the Hepatogastrolial type, which has been accepted as the normal pattern of specimen, coeliac trunk divided into common hepatic & splenic arteries, the left gastric artery took origin from the splenic artery. **CONCLUSION:** In my study out of 30 specimens 92% belonged to Type I, 2% to Type II, 2% to Type III, 2% to Type IV. This classification is according to LIPSCHUTZ (1917). The most common pattern of branching of the Coeliac trunk was the Hepatogastrolial type, which has been accepted as the normal pattern of branching of the Coeliac trunk.

**KEYWORDS:** Coeliac trunk, hepatolienogastric artery hepatolieno trunk, gastro hepatic trunk, gastro splenic trunk.

**INTRODUCTION:** The ceeliac trunk is first branch of the abdominal aorta at the level of twelfth thoracic vertebrae.<sup>1</sup> Its branches are left gastric artery, common hepatic artery and splenic artery which supply primary organs of supracolic compartments. The common hepatic artery divides into three branches-splenic artery, left gastroduodenal artery and hepatic artery proper. The gastroduodenalartery terminates by dividing into superior pancreatico duodenal and right gastroepiploic arteries. The hepatic artery proper terminates by dividing into right and left hepatic arteries which supply right and left lobes of liver respectively.<sup>2</sup> The unusual embryological development of the ventral splanchnic arteries can lead to considerable variations in the origin of coeliac trunk and its branches.<sup>3</sup> Knowledge of variations of visceral arteries will be very much helpful for sugeons, anesthetists, anatomists, and radiologists. The present study includes the variations in branching pattern of caeliac trunk.<sup>4</sup>

**MATERIALS & METHODS:** The material for this study composed of 30 embalmed adult human cadavers of known sex obtained from Department of Anatomy, Kurnool Medical College, Kurnool, Andhra Pradesh. The abdomen was opened in cruciform incision passing through whole thickness of

## ORIGINAL ARTICLE

abdominal wall, all abdominal viscera were identified and removed according to cunnighams manual of practical anatomy, caeliac trunk was traced and branching pattern was observed.<sup>5</sup>

**RESULTS & DISCUSSION:** Anatomical variations involving the visceral arteries are common. The study of variations in branching pattern of the caeliac trunk<sup>6</sup> becomes important for patients undergoing diagnostic angiography for gastrointestinal bleeding or prior to an operative procedure.

Results are discussed in table given (Table 1).

Lipshutz gave a detailed account of caeliac trunk based on origin and distribution of gastric, splenic, and hepatic arteries <sup>7</sup>and classified his findings into 4 types.

**TYPE I (75% cases):** Celiac axis is a common trunk of origin for gastric, splenic and hepatic arteries.

**TYPE II (15% cases):** Celiac axis is a common trunk for origin of hepatic artery and splenic artery but left gastric artery had a varied origin either from caeliac trunk or directly from abdominal aorta.

**TYPE III (6% Cases):** Celiac axis is a common trunk for origin of gastric artery and hepatic artery but splenic artery was a separate branch from abdominal aorta.

**TYPE IV (4% cases):** Celiac axis is the common trunk of origin for gastric and splenic arteries but hepatic artery occurred as separate branch directly from abdominal aorta.

AUTHOR	YEAR	NO. OF SPECIMENS	TYPE 1	TYPE 2	TYPE 3	TYPE 4
Rossi & cova	1904	55	48	6	0	1
Picquand	1910	50	37	5	3	4
Descomps	1910	50	28	16	0	5
Rio branco	1912	50	30	15	3	1
Lipschutz	1917	83	140	47	10	9
Eaton	1917	206	28	2	0	0
Present Study	2014	30	92	2	2	2

Table 1: Comparisons of variation in branching pattern of coeliac trunk with previous studies

### CONCLUSION:

- In my study out of 30 specimens 92% belonged to Type I,
- 2% to Type II (Fig. 1),
- 2% to Type III (Fig. 2),
- 2% to Type IV (Fig. 3). This classification is according to LIPSCHUTZ (1917).
- The most common pattern of branching of the coeliac trunk was the Hepatogastrolial type, which has been accepted as the normal pattern of branching of the coeliac trunk. Knowledge of above variations are important to vascular surgeons, anatomists, anaesthetists, radiologists.

# ORIGINAL ARTICLE

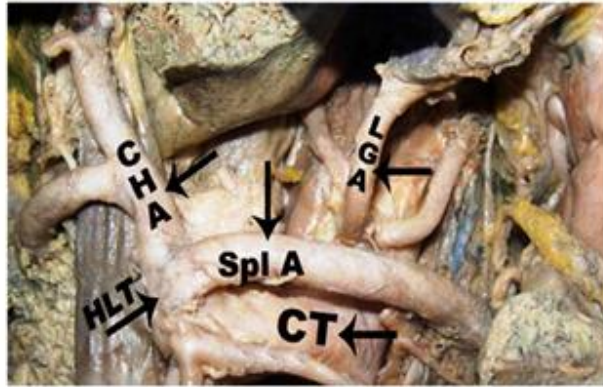


Fig. 1 Hepetolieno trunk from CT  
HLT - Hepetolieno trunk

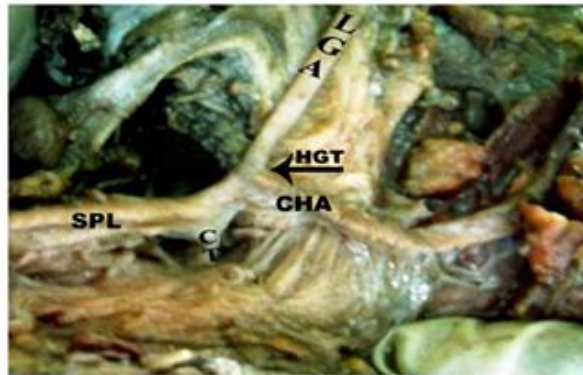


Fig.2 Hepatic Gastric Trunk from Coeliac trunk.  
HGT - Hepatic Gastric Trunk

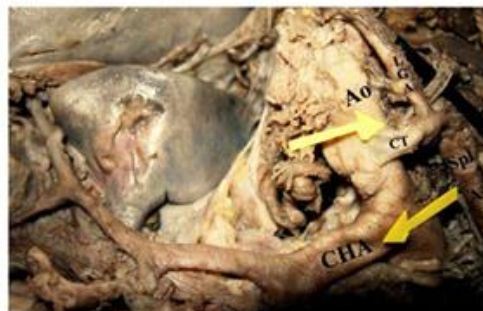

Fig. 3 Lienogastric trunk from coeliac trunk  
CT - Common Trunk,CHA-Common hepatic artery  
LGA-left Gastric Artery,SPL - Splenic Artery,Ao-Abdominal aorta

**REFERENCES:**

1. Asim Kumar Datta. Essentials of Human Anatomy 8th edition, part I, pg no: 154-155.
2. T. S. Ranganathan, A text book of Human Anatomy 1982, 3rd edition, pg no:325-327.
3. Text book of embryology pal, 189, 8<sup>th</sup> edition.
4. Descomps P. Letronecoelique, steinheil, paris 1910 cited. The branches of caeliactrunk actaanat 1985; 122 110-114.
5. Romanes Cunnigham, Manual of Practical anatomy, Vol. 3127/129,15<sup>th</sup> edition.
6. Antony sylvan D'souza, Vijaya lakshmi, Hemalatha, Pugazhadhi, H. Mamatha: Anatomical variations in the branches of coeliac trunk, JCDR/2012/3866:2060.
7. Lipshutz B. A, Composite Study of the coeliac axis artery. Annsurg, 1917; 65; 159-169.

**AUTHORS:**

1. Ch. Jayamma
2. S. K. Vanisree
3. V. Saila Kumari
4. G. Rohini Devi

**PARTICULARS OF CONTRIBUTORS:**

1. Associate Professor, Department of Anatomy, KMC, Kurnool, NTRUHS.
2. Assistant Professor, Department of Anatomy, KMC, Kurnool, NTRUHS.
3. Professor & HOD, Department of Anatomy, KMC, Kurnool, NTRUHS.

**FINANCIAL OR OTHER****COMPETING INTERESTS:** None

4. Senior Post Graduate, Department of Anatomy, KMC, Kurnool, NTRUHS.

**NAME ADDRESS EMAIL ID OF THE CORRESPONDING AUTHOR:**

Dr. Ch. Jayamma,  
W/o. B. Balasubramanyam,  
Flat No. 304, S. L. N. Mansion,  
Prakash Nagar, Kurnool.  
E-mail: rohinidevi2111@gmail.com

Date of Submission: 07/05/2015.  
Date of Peer Review: 08/05/2015.  
Date of Acceptance: 27/05/2015.  
Date of Publishing: 03/06/2015.