

CASE REPORT

EARLY-STAGE HODGKIN'S LYMPHOMA IN A CHILD: A CASE REPORT

Kandukuri Mahesh Kumar¹, Kazi Wajid Husain², Chinthakindi Sravan³, R. Swarupa⁴, Konduru Omkareshwar⁵

HOW TO CITE THIS ARTICLE:

Kandukuri Mahesh Kumar, Kazi Wajid Husain, Chinthakindi Sravan, R. Swarupa, Konduru Omkareshwar. "Early-stage Hodgkin's lymphoma in a child: a case report". Journal of Evolution of Medical and Dental Sciences 2014; Vol. 3, Issue 10, March 10; Page: 2649-2654, DOI: 10.14260/jemds/2014/2187

ABSTRACT: Of all the paediatric malignancies, lymphomas account for about 10-15% of the cases with half of them diagnosed as Hodgkin's lymphoma. With a 5-year survival rate approaching 95%, a high index of suspicion is necessary to diagnose Hodgkin's lymphoma at an early stage, since many children in the developing countries present with an advanced stage. We report a typical case of classical Hodgkin's lymphoma, mixed cellularity subtype in a 10-year old girl with early-stage unfavourable disease presenting as a slightly painful right cervical mass and "B" symptoms. Erythrocyte sedimentation rate (ESR) was elevated. Ultrasound neck scan suggested tuberculous lymphadenitis. Other laboratory and radiological findings were normal. Fine needle aspiration smears and histopathology helped in arriving at diagnosis of classical Hodgkin's lymphoma, mixed cellularity subtype. The child was treated with a combination of combined chemotherapy and radiotherapy.

KEYWORDS: Hodgkin's lymphoma; children; early-stage unfavourable disease; mixed cellularity subtype

BACKGROUND: Of all the paediatric malignancies, lymphomas account for about 10-15% of the cases¹ with half of them diagnosed as Hodgkin's lymphoma². Remarkably, this malignancy has a high cure rate with a 5-year survival rate approaching 95%¹. Hodgkin's lymphoma has an overall incidence rate of 14 per 100,000 under 15 years of age. It has a typical bimodal distribution with respect to age. In developed countries, the peak incidence is seen in the young adults and elderly. While, in developing countries the incidence is higher among children and young adults with a male preponderance. Histologically, mixed cellularity subtype of classical Hodgkin's lymphoma occurs commonly in the children and in developing countries³. We report a typical case of classical Hodgkin's lymphoma, mixed cellularity subtype in a 10-year old girl with early-stage unfavourable disease presenting as a slightly painful right cervical mass and "B" symptoms.

CASE REPORT: A 10-year-old girl presented to a general practitioner with 4-month history of swelling in the right neck region associated with fever, night sweats, lethargy and weight loss. Initially, the swelling was small and slightly painful. The child remained asymptomatic for few days with analgesics and antibiotics though the size of the swelling was same. Symptoms recurred after 15 days of treatment with an increase in size of the swelling, for which the child came to our hospital. The child had a temperature of 38.3° C. Systemic examination showed no organomegaly. On local examination, the right neck mass measured 4 cm x 2.5 cm, was firm, non-tender, and slightly mobile, with normal skin above the swelling. Laboratory investigations like complete blood picture and urine examination were within normal ranges. Erythrocyte sedimentation rate was elevated. Refer Table 1 for the laboratory findings.

CASE REPORT

LABORATORY FINDINGS	
COMPLETE BLOOD PICTURE	
Haemoglobin	11.6 gm/dl
Total leukocyte count	9600/ cu.mm
Differential leukocyte count	Neutrophils-58 %,Lymphocytes-34 %, Eosinophils-05%, Monocytes-04 %, Basophils-0%
Platelet count	2.6 lakhs/ cu.mm
RBC morphology	Normocytic normochromic blood picture
SEROLOGY	
HIV 1 and 2	Non-reactive
HBsAg	Non- reactive
OTHERS INVESTIGATIONS	
ESR	46 mm/hr.
Mantoux test	Non-reactive
Urine examination	Normal
Table 1: Laboratory findings	

Ultrasound neck scans show an enlarged lymph node measuring 3.7 cm x 2.6 cm x 1.5 cm in the right anterior triangle of the neck suggesting tuberculous lymphadenitis. Refer Table 2 for the radiological findings.

RADIOLOGICAL FINDINGS	
RADIOGRAPH	
Chest	Normal
Abdomen and pelvis	Normal
ULTRASOUND SCAN	
Neck	Suggestive of tuberculous lymphadenitis
Abdomen and pelvis	Normal
Table 2: Radiological findings	

Cytosmears from fine needle aspiration of the right neck mass were suggestive of lymphoid neoplasm, possibly Hodgkin's lymphoma (Figure 1A and 1B).

CASE REPORT

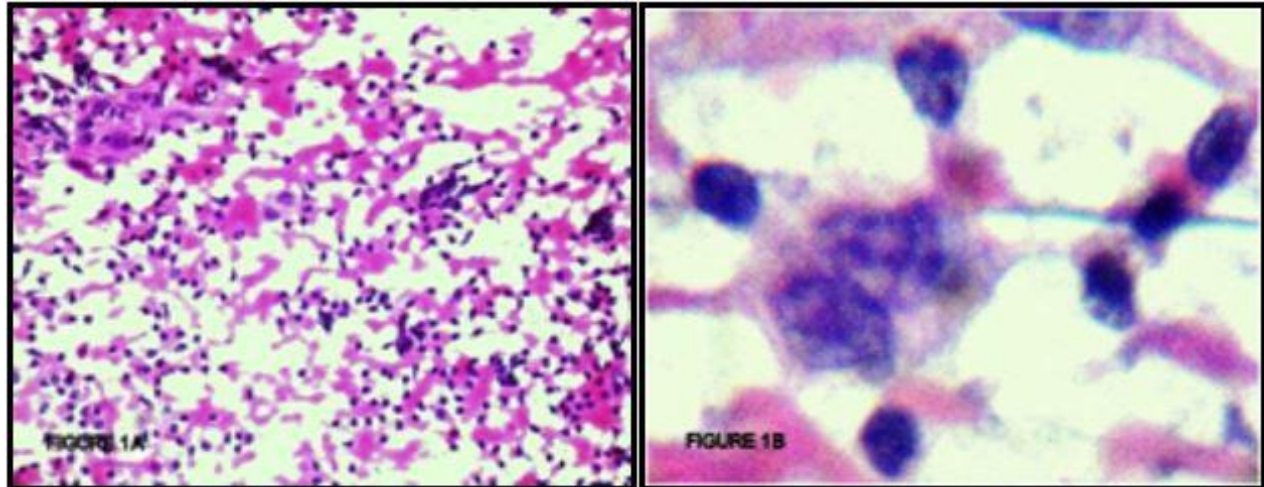


Fig 1: FNAC RIGHT NECK MASS (A) Cytosmear shows small and large lymphocytes, few binucleate cells against haemorrhagic background (Haematoxylin and Eosin, 40x) **(B)** Cytosmear shows a classical Reed-Sternberg cell with a bilobed nucleus, prominent eosinophilic nucleoli with perinucleolar halo and abundant cytoplasm (Haematoxylin and Eosin, 100x)

The right neck mass was surgically excised and biopsy specimen sent for pathological examination.

PATHOLOGY FINDINGS:

Gross examination: Grossly, the specimen of excision biopsy was a single well-circumscribed lymph node mass measuring 3.5 cm x 2.5 cm with focal nodularity (Figure 2 A). Cut section was fleshy, homogenous with grey white areas. No areas of haemorrhage or necrosis were observed (Figure 2 B).



Fig 2: GROSS PATHOLOGY (A) Gross specimen of an excised lymph node mass with surface nodularity **(B)** Cut section showing fleshy homogenous grey, white areas.

CASE REPORT

Microscopy showed diffuse effacement of the lymph node architecture by a polymorphic population of cells, mainly comprising of small and large lymphocytes, plasma cells, eosinophils (Figure 3 B, C and D), large mono-nucleate Hodgkin's cells and classical Reed-Sternberg cells (Figure 3 D) with a bilobed nucleus, prominent eosinophilic nucleoli with perinucleolar halo and abundant cytoplasm suggestive of classical Hodgkin's lymphoma-mixed cellularity type.

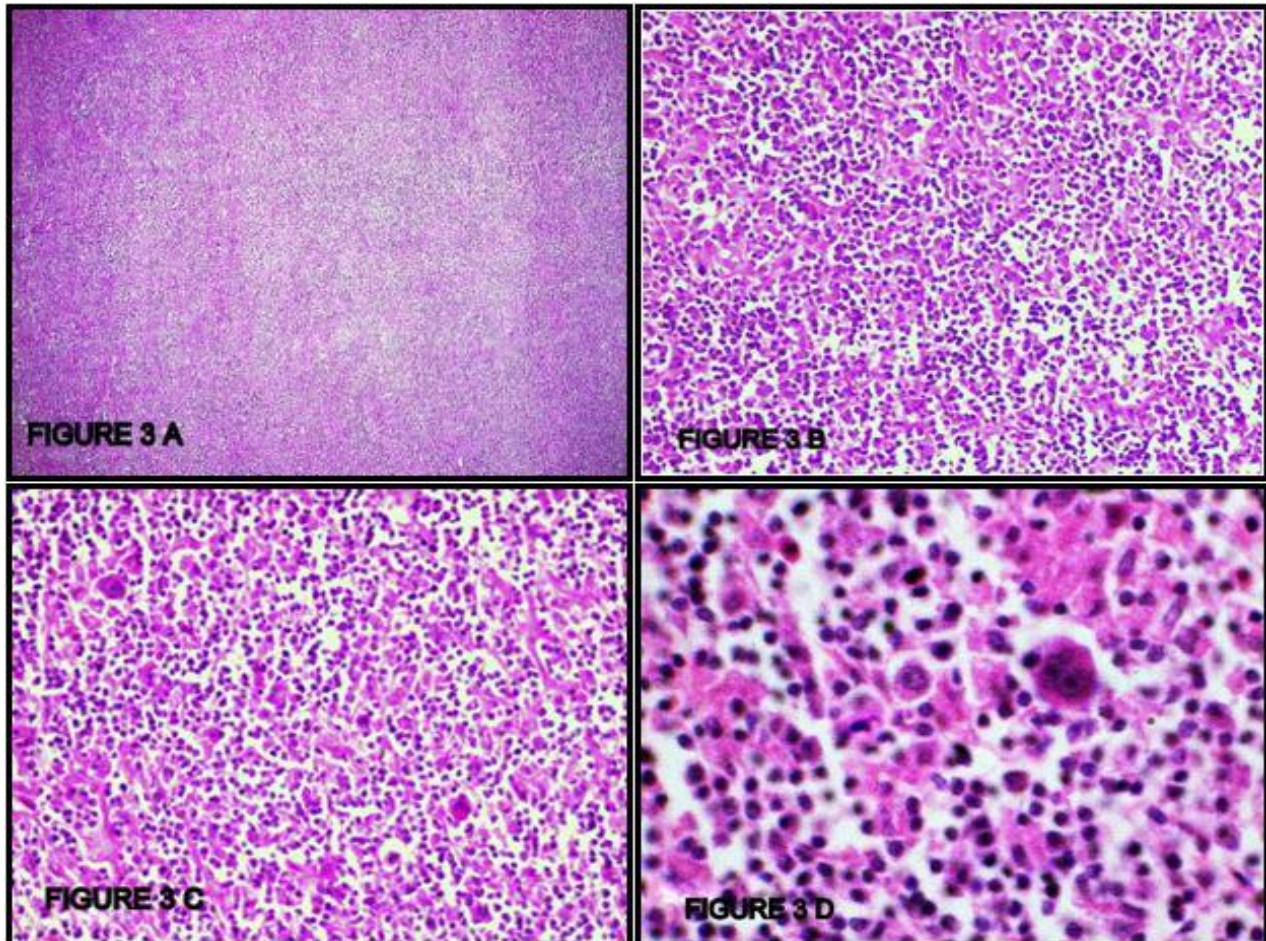


Fig 3: Classical Hodgkin's lymphoma-mixed cellularity type. (A) Photomicrograph shows diffuse effacement of lymph node architecture (Haematoxylin and Eosin, 4x) (B, C) Photomicrographs showing mainly small and large lymphocytes, plasma cells, eosinophils, few bi-nucleate cells. (Haematoxylin and Eosin, 10x) (D) Photomicrograph shows a classical Reed-Sternberg cell and a Hodgkin's cell in the background of inflammatory cells. (Haematoxylin and Eosin, 40x)

STAGING AND FURTHER MANAGEMENT: The child had early-stage I B disease, but unfavourable due to the presence of "B" symptoms and raised ESR. Bone marrow study was normal. The child was treated with a combination of combined chemotherapy and radiotherapy.

DISCUSSION: Thomas Hodgkin offered the first description of Hodgkin's lymphoma in 1832, in a paper titled "On some morbid appearances of the absorbent glands and spleen"^{4,5}. In 1856, Samuel Wilks coined the term "Hodgkin's disease"⁵.

CASE REPORT

Association of Epstein Barr virus infection to classical Hodgkin's lymphoma is prominent in children from developing countries with an incidence of 91-98%. About 4.5% of cases show genetic susceptibility. Interestingly, 10-fold rise in incidence of classical Hodgkin's lymphoma is found in Human Immunodeficiency virus infected individuals. It may be associated with autoimmune diseases and can occur with Non-Hodgkin's lymphoma⁵.

WHO classification categorises Hodgkin's lymphoma into classical and nodular lymphocyte-predominant types. Classical Hodgkin's lymphoma is further sub-typed into nodular sclerosis, lymphocyte-rich, mixed cellularity and lymphocyte-depleted subtypes^{1,5}.

In Hodgkin's lymphoma, the neoplastic cells constitute less than 1% in the affected lymph node. Classical Reed-Sternberg cells are relatively infrequent, although cells with a similar phenotype but a varied morphology termed, as Hodgkin/Reed-Sternberg cells are common. Immunophenotypic studies show that these cells are derived from B cells in germinal centre of the lymph node and are CD15; CD30 positive. Interactions between Hodgkin/Reed-Sternberg cells and surrounding inflammatory cells are significant in the pathogenesis of Hodgkin's lymphoma⁵.

Paediatric Hodgkin's lymphoma commonly presents with unilateral, painless cervical lymphadenopathy. In 3% of cases, the primary site is subdiaphragmatic⁶. Those with mediastinal involvement present with persistent cough. Rarely, the child may present with splenomegaly; enlarged axillary or inguinal lymph nodes⁴. The "B" symptoms include temperature above 38°C, drenching night sweats, and unexplained loss of more than 10% of body weight within the past 6 months occur in about 50% of children from developing countries³.

Radiological investigations like CT and PET scan helps in localisation of the Hodgkin's lymphoma. The disease extent is evaluated with the Cotswolds' four-stage modification of the Ann Arbor classification⁷. The child in our report presented with early-stage I B nonbulky, unfavourable disease, which according to Cotswolds staging classification⁷ is the involvement of a single lymph-node region or lymphoid structure like spleen, thymus, Waldeyer's ring or involvement of a single extra lymphatic site and the presence of "B" symptoms.

Management of Hodgkin's lymphoma, early-stage unfavourable disease comprises combined chemotherapy and involved-field irradiation⁷.

CONCLUSION: With an increased incidence of paediatric Hodgkin's lymphoma in the developing countries, general practitioners should be aware of its early clinical manifestations. A high index of suspicion is necessary to diagnose Hodgkin's lymphoma at an early stage, since many children present with an advanced stage. Radiological investigations help in defining the extent of disease. Fine needle aspiration plays a valuable role in the initial assessment of a child with Hodgkin's lymphoma with histopathological examination offering the definitive diagnosis supplemented by immunophenotyping. Staging the extent of the disease helps in risk stratification and planning treatment options.

REFERENCES:

1. Frew JA, Lewis J, Lucraft HH. The management of children with lymphomas. *Clin Oncol (R Coll Radiol)*. 2013 Jan; 25(1):11-8.
2. Arya LS, Dinand V. Current strategies in the treatment of childhood Hodgkin's disease. *Indian Pediatr*. 2005 Nov; 42(11):1115-28.

CASE REPORT

3. Pötter R. Paediatric Hodgkin's disease. Eur J Cancer. 1999 Oct; 35(10):1466-74; discussion 1474-6.
4. Stefan DC, Jacobs P. Lymphoma: a pediatrician's perspective. Transfus Apher Sci. 2010 Apr; 42(2):185-7.
5. Mani H, Jaffe ES. Hodgkin lymphoma: an update on its biology with new insights into classification. Clin Lymphoma Myeloma. 2009 Jun; 9(3):206-16.
6. Dinand V, Arya LS. Epidemiology of childhood Hodgkin's disease: is it different in developing countries? Indian Pediatr. 2006 Feb; 43(2):141-7.
7. Diehl V, Thomas RK, Re D. Part II: Hodgkin's lymphoma--diagnosis and treatment. Lancet Oncol. 2004 Jan; 5 (1): 19-26.

AUTHORS:

1. Kandukuri Mahesh Kumar
2. Kazi Wajid Husain
3. Chinthakindi Sravan
4. R.Swarupa
5. Konduru Omkareshwar

PARTICULARS OF CONTRIBUTORS:

1. Assistant Professor, Department of Pathology, Malla Reddy Institute of Medical Sciences, Hyderabad, Andhra Pradesh.
2. Assistant Professor, Department of Pathology, Sri Venkateshwara Medical College, Hospital and Research Centre, Pondicherry.
3. Consultant Pathologist, Department of Pathology, Vijaya Diagnostic Centre, Hyderabad, Andhra Pradesh.

4. Consultant Pathologist, Department of Pathology, Vijaya Diagnostic Centre Hyderabad, Andhra Pradesh.
5. Associate Professor, Department of Pathology, Malla Reddy Institute of Medical Sciences, Hyderabad, Andhra Pradesh.

NAME ADDRESS EMAIL ID OF THE CORRESPONDING AUTHOR:

Dr. Kandukuri Mahesh Kumar,
Assistant Professor,
Department of Pathology,
Malla Reddy Institute of Medical Sciences,
Hyderabad, Andhra Pradesh, India.
E-mail: doctormaheshgoud@gmail.com

Date of Submission: 10/02/2014.
Date of Peer Review: 11/02/2014.
Date of Acceptance: 21/02/2014.
Date of Publishing: 07/03/2014.