

SURGICAL FIXATION OF TALAR FRACTURES- OUR EXPERIENCES. Sreenivasa Reddy¹, Y. Thimma Reddy², Ravikiran³, Kali Vara Prasad Vadlamani⁴, D. Narender⁵**HOW TO CITE THIS ARTICLE:**

S. Sreenivasa Reddy, Y. Thimma Reddy, Ravikiran, Kali Vara Prasad Vadlamani, D. Narender. "Surgical Fixation of Talar Fractures - Our Experience". Journal of Evolution of Medical and Dental sciences 2015; Vol. 4, Issue 75, September 17; Page: 13101-13113, DOI: 10.14260/jemds/2015/1887

ABSTRACT: BACKGROUND: Fractures and dislocations of the talus are challenging injuries. The frequent incidence of serious complications, such as osteonecrosis, associated with talus fractures leads to a substantial risk of unsatisfactory results. The results of surgical intervention in these cases have improved over the years, thanks to the usage newer implants and superior surgical skills.

MATERIALS AND METHODS: The present study was undertaken in the department of Orthopedics and Traumatology, Osmania General Hospital, during the period September 12 to September 14, and comprises 30 patients who underwent surgical management of displaced talar fractures.

CONCLUSIONS: Most of the fractures of the talus should be treated with reduction and internal fixation to reduce the complications. Once the fractures are fixed the joints can be mobilized early so that Post traumatic stiffness can be prevented. However development of Aseptic necrosis and pain the joint are independent of method of treatment and are dependent on the initial displacement of the fragments.

KEYWORDS: Talar Fractures, Internal Fixation, Aseptic Necrosis of Talus.

INTRODUCTION: The talus is the second most commonly fractured tarsal bone. Talus fractures make up 0.5% of all fractures, 2% of all lower extremity injuries and 5% of foot fractures, neck fracture make up more than 40% of talar fractures, talar body fractures-about 20% of talar fractures, talar head fractures make up about 10% of talar fractures.^{1,2} In recent years, improved recognition has resulted in an increased number of talar process fractures being diagnosed. Although sports injuries often account for talar process fractures, fractures of the talar neck and body are often secondary to high-energy trauma.

AIMS AND OBJECTIVES³:

- To evaluate the rate of early and late complications after operative treatment of displaced talar fractures.
- To determine the functional outcomes after operative treatment.
- To evaluate the mode of injury.
- To gain experience with the surgical management of displaced talar fractures with or without comminution treating with plate with screws and screws.

MECHANISM OF INJURY: Most serious fractures of the talus are high-energy injuries. Fractures of the talar neck are commonly the result of a hyperdorsiflexion type injury. Flying accidents were also common in the description by Coltart.⁴ Currently, motor vehicle collisions and falls from a height are more common mechanisms of serious talus fractures.

TALAR NECK FRACTURE CLASSIFICATION: Hawkins.⁵ in 1970 developed a classification system for talar neck fractures; this classification was for vertical neck fractures and based on X-ray appearance at time of the injury, the classification depends on the degree of original displacement and the number of joints involved, it is the most commonly used.

ORIGINAL ARTICLE

TREATMENT: Fractures of the Talar Neck and Body. These represent a continuum and are considered together.

Non-displaced Fractures:

- Fractures that appear Non-displaced on plain radiographs may show unrecognized comminution or articular step-off on CT scan. Fractures must truly be Non-displaced with no evidence of subtalar incongruity to be considered a type I fracture.
- Treatment consists of a short leg cast or boot for 8 to 12 weeks. The patient should remain non-weight bearing for 8 to 12 weeks until clinical and radiographic evidence of fracture healing is present.

Displaced Fractures:

- Immediate closed reduction is indicated, with emergency open reduction and internal fixation (ORIF) for all open or irreducible fractures.
- If anatomic reduction is obtained and confirmed by CT scan, the patient should be placed in a short leg cast, with treatment as for nondisplaced fractures.
- If open reduction is necessary, all major fragments should be salvaged. Primary arthrodesis should be avoided.

Surgical Approaches include:

- **Anteromedial:** This approach may be extended from a limited capsulotomy to a wide exposure with malleolar osteotomy. The internal is just medial to the anterior tibial tendon. This approach allows visualization of the talar neck and body. Care must be taken to preserve the saphenous vein and nerve and, more importantly, the deltoid artery.
- **Posterolateral:** This approach provides access to posterior process and talar body. The interval is between the peroneus brevis and the flexor hallucis longus. The sural nerve must be protected. It is usually necessary to displace the flexor hallucis longus from its groove in the posterior process to facilitate exposure.
- **Anterolateral:** This approach allows visualization of the sinus tarsi, lateral talar neck, and subtalar joint. Inadvertent damage to the artery of the tarsal sinus can occur through this approach.
- **Combined anteromedial-anterolateral:** This is often used to allow maximum visualization of the talar neck.
- **Internal fixation:** Two inter-fragmentary lag screws or headless screws are placed perpendicular to the fracture line. The screws can be inserted in ante-grade or retrograde fashion. Posterior-to-anterior directed screws have been demonstrated to be biomechanically stronger.
- Use of titanium screws allows better visualization with MRI for evaluation of subsequent osteonecrosis.
- Areas of significant comminution and bone loss should be grafted.
- A plate can be used to buttress areas of comminution.
- A short leg cast or removable boot should be placed postoperatively for 8 to 12 weeks, and the patient should be kept non-weight bearing.

ORIGINAL ARTICLE

- **Hawkins sign:** Subchondral osteopenia (Seen on the AP ankle radiograph) in the talus at 6 to 8 weeks tends to indicate talar viability. However, the presence of this sign does not rule out osteonecrosis; its absence is also not diagnostic for osteonecrosis.

IMPLANTS: The size of screws used depends upon the size of the talar fragments. Usually 2.7, 3.5mm and 4mm screws or 4.0-mm, 4.5-mm, and 6.5mm partially threaded cannulated screw can be used to stabilize the primary fracture fragments, with smaller 2.0- or 2.4-mm screws for comminuted fragments. 2.0-mm blade, straight, or T plate or even the stouter new 2.4- and 2.7-mm plates are available and can be contoured to the medial or lateral column.

MATERIALS AND METHODS: Present study consisting of 30 patients, reporting to Osmania General Hospital, Hyderabad from Sep. 2012 to Sep. 2014, treated by internal fixation using screws and plates with screws, and those who were available for follow up.

Adult patients with displaced talar fractures, operated at OGH, using screws and plating during the above mentioned period were evaluated during their hospital stay.

Inclusion Criteria:

- All patients between 18 to 60 years of age.
- All displaced talar fractures.
- Patients should be walking prior to the fracture.

Exclusion Criteria:

- Undisplaced talar fractures.
- Open fractures
- Pathological fractures
- Talar fractures with other associated fracture in lower limb.
- Fractures in children.
- Fractures in adults >60years.
- Severely osteoporotic bone.

A thorough history and clinical examination was done. The swelling of the ankle and status of the skin was recorded. X rays of the talus were taken on admission which included lateral and anteroposterior views. CT scans were taken to further evaluate the fracture pathology. The patient was temporarily put on a below knee slab with adequate limb elevation until oedema subsided.

The fractures were classified based on the Hawkins and sneppen's classification. All the fractures in our study were displaced type with 25 patients having Hawkins type and 5 having Sneppen's type fracture.

The patient was then posted for internal fixation with screws and plates with screws, whatever is appropriate. Anteromedial or anterolateral or poster lateral or poster medial or combined approach with or without malleolar osteotomy or percutaneous fixation was used.

FOLLOW UP AND CRITERIA FOR EVALUATION: The patients were followed up clinically and radiologically at 6 weeks, 12 weeks, 6 months, and 1 year, with respect to radiological union, AVN changes, range of movements at ankle joint, subtalar joints. At every follow up clinical examination was done to assess status of the surgical wound, pain, tenderness, range of motion of ankle joint and sub-

ORIGINAL ARTICLE

talar joint. Roentgenograms were taken in Lateral and antero-posterior views to look for signs of radiological union.

This study concluded clinical union when the fracture site had become stable and pain free. The union is confirmed radiologically when plain X-ray showed bone trabeculae or cortical bone crossing fracture site. The time taken for clinical and radiological union was noted. If there are no clinical and radiological signs of union by 12 weeks, the fracture was categorized as delayed union and in the absence of fracture union after 24 weeks after injury was categorized as non-union. This study had 1 case of delayed union and 1 case of non-union following fixation.

The functional outcome was measured by the "American Orthopedic Foot and Ankle Society (AOFAS) Ankle Hindfoot scoring system" at twelve months. The AOFAS scoring system⁶ is a very useful tool to measure function of the foot developed by the American Academy of Orthopaedic Surgeons (AAOS) and has been validated by various studies. The AOFAS score is a 100 point scoring system mainly assessing the pain, function and alignment of the foot. The functional outcome decreases as the score decreases.

The result was then graded as Excellent, Good, Fair and poor as follows:

Excellent - ≥ 90 Points.

Good - 80 to 89 points.

Fair - 70 to 79 points.

Poor - ≤ 69 points.

OBSERVATIONS AND RESULTS: The present study consists of 30 patients of fresh displaced talar fractures which were treated surgically with plate with screws and screws for displaced talar fractures during the course of study at OGH. All the patients were available for follow-up at 6 weeks, 12 weeks, 6 months and 1 year. Results were analyzed both clinically and radiologically.

AGE INCIDENCE: Majority of the patients with Talar neck fracture i.e. 20 patients (80% of Neck fractures) were in the age group of 25-34 and 35-44 years and. The youngest patient was 23 years and oldest patient was 55 years. The average patient age for talar neck fractures was 36 years.

Majority of patients with Talar body fractures i.e. 2 patients (40% of talar body fractures) were between 25-34 years. The youngest patient was 19 years and oldest patient was 47 years the average age for body fractures was 33.8 years. Majority of the patients with Talar fracture i.e. 22 patients (73.33%) of fractures) were in the age group of 25-34 and 35-44 years. The average patient age for Talus fractures was 35.73 years.

SEX INCIDENCE: In this study there were 25 male patients (83.33% of all talar fractures) and 5 female patients (16.66% of all talar fractures)

Out of 25 talar neck fractures-22 male patients (88% of talar neck fractures) and 3 female patients (12% of talar neck fractures)

Out of 5 talar body fractures there were 3 male patients (60% of talar body fractures) and 2 female patients (40% of talar body fractures).

MODE OF INJURY: 18 of 30 Talar fractures were due to RTA (60%), 12 of 30 Talar fractures were due to fall from height (40%). 16 of 25 Talar neck fractures-due to RTA (64% of talar neck fractures), 9 of 25 Talar neck fractures-due to fall from height (36% of talar neck fractures). 2 of 5 talar body fractures

ORIGINAL ARTICLE

-due to RTA (40% of talar body), 3 of 5 Talar body fractures- due to fall from height (60% of talar body fractures).

SIDE AFFECTED: In this study for total talar fractures there were 20 patients (66.66%) of right side fracture and 10 patients (33.33%) of left side fracture

In this study for talar neck fractures there were 17 patients (68% of talar neck fractures) of right side fracture and 8 patients (32% of talar neck fractures) of left side fracture.

For talar body fracture there were 3 patients (60% of talar body fractures) on the right side and 2 patients (40% of talar body fractures) on the left side.

SITE OF FRACUTE: In this present study there were 25 patients of Neck fracture (83.3333%) and 5 patients (16.6666%) were Body fracture and there were no Talar Head fracture.

All the fractures were closed type. There were no associated medical illness in any patient.

CLASSIFICATION: Plain radiograph of ankle with foot was taken in anteroposterior view and lateral view to assess the site of fracture and the type of fracture. In this study Hawkins classification was followed for talar neck fractures and sneppen classification.⁷ was followed for talar body fractures.

Talar Neck fractures (25 cases)

Hawkins classification:

HAWKINS TYPE	No. of cases	%
1	0	0%
2	12	48%
3	8	32%
4	5	20%

Talar Body fractures (5 cases) Sneppen classification:

Type	No. of cases	%
1	0	0%
2	4	80%
3	0	0%
4	0	0%
5	1	20%

In talar body fractures 4 cases out of 5 cases belong to sneppen type 2. 2 cases-sagittal fractures, 2 cases-coronal fractures.

TIME INTERVAL FOR SURGERY: All the patients were operated as early as possible once the general condition of the patients was stable. In Talar neck fracture 12 patients (48%) were operated within 24 hours, 5 patients (20%) were operated On 2nd day due to fixed OT days in OGH, 1 case (4%) week was operated in 2nd week and 1 case (4%) was operated after 2 weeks due to skin problems and massive swelling.

In Talar body fractures 2 patients (40%) under gone surgery within 24 hours, 1 patient (20%) was operated on 2nd day, 1 patient (20%) was operated on 3rd day and 1 patient (20%) was Operated on 5th day. All the patients were operated under spinal anesthesia.

ORIGINAL ARTICLE

TYPES OF IMPLANT: For Talar neck fracture:

The talar neck fracture are fixed with screws and plating (Plate with screws).

In 18 patients (72%) screws were used, in 5 patients (20%) plates were used and in 2 patients (8%) plates and screws were used. Commonly screws were used.

TYPES OF IMPLANT: For Talar body fracture:

The talar body fracture are fixed with screws and plating (Plate with screws).

In 2 patients (40%) screws were used, in 1 patients (20%) plates were used and in 1 patients (20%) plates and screws were used. Commonly screws were used.

SURGICAL APPROACHES USED FOR TALAR NECK FRACTURES: In this study dual approach commonly used for 16 talar neck fractures (64%), percutaneous screw fixation method used for 2 cases of noncomminuted Hawkins type 2 fractures. In 12 cases out of 16 cases of dual approach AM and AL approach was used.

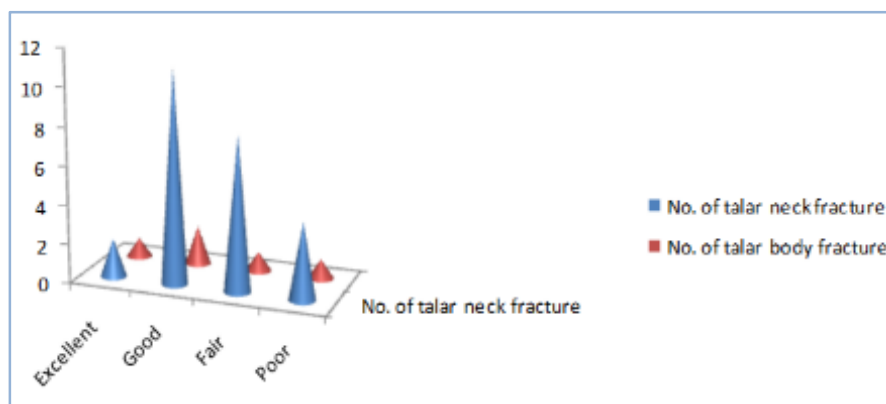
SURGICAL APPROACHES FOR TALAR BODY FRACTURES: DUAL APPROACH of Anteromedial and Anterolateral commonly used in talar body Fractures.

FUNCTIONAL OUTCOME: The functional outcome is assessed by American Orthopedic Foot and Ankle Society (AOFAS) Ankle Hind foot scoring.

Functional outcome	No. of talar neck fracture	% (of neck #)	No. of talar body fracture	% (of body #)	TOTAL	% (Of all)
Excellent	2	8%	1	20%	3	10%
Good	11	44%	2	40%	13	43.33%
Fair	8	32%	1	20%	9	30%
Poor	4	16%	1	20%	5	16.66%

In this study 11 patients (44%) of 25 talar neck fractures treated with plate and/or screws had good functional outcome, 8 patients (32%) had fair functional outcome, poor functional outcome in 4 patients (16%) and excellent functional outcome in 2 patients (8%).

2 patients (40%) of 5 talar body fracture fixed with plate and/or screws had good functional outcome, 1 patients (20%) had excellent functional outcome, 1 patient (20%) had fair functional outcome and 1 patient had poor functional outcome.



ORIGINAL ARTICLE

DISCUSSION: The present study of 25 patients with talar neck fractures is compared with Heather A. Vallier et al.⁸ study which reviewed only talar neck fractures, in this totally 100 patients with 102 fractures were reviewed, who were treated with open reduction and internal fixation with plate and screws. In Heather A. Vallier et al study forty-one patients with forty-two fractures were unavailable for follow-up. Two patients died of unrelated causes, two patients had severe closed head injuries and were unable to walk or to communicate, one patient was in jail, one patient did not speak English, and thirty-five patients could not be located. Seventeen of the thirty-five patients who could not be located had been followed for six to twelve months, and none of them had had any clinical problems or symptomatic radiographic abnormalities at the time of the most recent follow-up. The remaining fifty-nine patients (Sixty fractures) were evaluated at an average of thirty-six months (Range, twelve to seventy-four months) after surgery. Forty-five of these patients had complete functional outcome data, and thirty-nine had complete radiographic data.}

The present study of patients with displaced talar body fractures is compared with Nabil A. Ebraheim, et al.⁹ Study which reviewed 19 displaced talar body fractures to assess outcome after internal fixation of Fractures.

MODE OF INJURY: In this study 16 of 25 Talar neck fractures-due to RTA (64% of talar neck fractures), 9 of 25 Talar neck fractures-due to fall from height (36% of talar neck fractures).

In Heather A. Vallier et al 86. Study the mechanism of injury was a motor vehicle accident for sixty patients (60%), a fall from a height for twenty-seven (27%), a motorcycle accident for seven (7%), a pedestrian motor vehicle accident for two (2%), sports-related trauma for two (2%), a plane crash for one (1%), and an industrial accident for one (1%).

In this study. 2 of 5 talar body fractures -due to RTA (40% of talar body), 3 of 5 Talar body fractures- due to fall from height (60% of talar body fractures).

In Nabil A. Ebraheim, et al 32 study seven patients were injured due to a fall (36.84%), nine as a result of motor vehicle accident (MVA) (47.36%), two after motorcycle accidents (10.52%) and one patient was injured as a pedestrian in a MVA (5.26%).

Age Incidence: In this study Majority of the patients with Talar neck fracture i.e. 20 patients (80% of Neck fractures) were in the age group of 25-34 and 35-44 years and. The youngest patient was 23 years and oldest patient was 552 years. The average patient age for talar neck fractures was 36 years.

In Heather A. Vallier et al 86 study -Sixty male patients (60%) and forty female patients (40%) with an average age of 32.6 years (range, thirteen to seventy-seven years). In this study Majority of patients with Talar body fractures i.e. 2 patients (40% of talar body fractures) were between 25-34 years. The youngest patient was 19 years and oldest patient was 47 years the average age for body fractures was 33.8 years.

In Nabil A. Ebraheim, et al 32 study the mean age was 31 years with a range of 21-68.

Sex Incidence: Out of 25 talar neck fractures-22 male patients (88% of talar neck fractures) and 3 female patients (12% of talar neck fractures).

In Heather A. Vallier et al 86 study -Sixty male patients (60%) and forty female patients (40%). Out of 5 talar body fractures there were 3 male patients (60% of talar body fractures) and 2 female patients (40% of talar body fractures).

ORIGINAL ARTICLE

Associated Injuries: In this study of talar neck fractures there were no associated injuries. In Heather A. Vallier et al 86 study Forty-four patients had additional ipsilateral foot and ankle injuries, and twenty-six had Contra lateral foot and ankle injuries.

In this study of talar body fractures there were no associated injuries, there were no associated talar neck fractures. In Nabil A. Ebraheim, et al 32 study two patients had associated talar neck fractures.

Type of Fracture: In this study all patients with talar neck fractures were of closed type, In Heather A. Vallier et al 86 study- Twenty-four fractures were open; of these, one was classified as type I, one was classified as type II, and twenty-two were classified as type IIIA according to the criteria of Gustilo and Anderson. In this study all patients with talar body fractures were of closed type. In Nabil A. Ebraheim, et al 32 study six patients sustained open fractures: one type I, three were type II, one was type IIIA and one was type IIIB.

SIDE AFFECTED: In this study for talar neck fractures there were 17 patients (68% of talar neck fractures) of right side fracture and 8 patients (32% of talar neck fractures) of left side fracture.

For talar body fracture there were 3 patients (60% of talar body fractures) on the right side and 2 patients (40% of talar body fractures) on the left side.

In Nabil A. Ebraheim, et al 32 study Twelve fractures (63.15%) were to the right talus compared to seven (36.84%) on the left side.

Fracture Classification: In this study Hawkins classification was followed for talar neck fractures. There were no undisplaced fractures (Group I), 12 were associated with subluxation or dislocation of the subtalar joint (Group II), 8 were associated with dislocation of the tibiotalar joint (Group III), and 5 were associated with dislocation of the tibiotalar, subtalar, and talonavicular joints (Group IV).

In Heather A. Vallier et al 86 study the fractures were classified into groups as described by Hawkins¹⁴ and modified by Canale and Kelly¹³. Four fractures were minimally displaced (Group I), sixty-eight were associated with subluxation or dislocation of the subtalar joint (Group II), twenty-five were associated with dislocation of the tibiotalar joint (Group III), and five were associated with dislocation of the tibiotalar, subtalar, and talonavicular joints (Group IV).

In this study sneppen classification was followed for talar body fractures. In talar body fractures 4 fractures out of 5 fractures belong to sneppen type 2 (2 cases- sagittal fractures, 2 cases- coronal fractures), 1 fracture belongs to type 5 (crush fracture).

In Nabil A. Ebraheim et al 32 study Boyd and Knight Classification was followed. The type of talar body fractures according to Boyd and Knight was as follows: 17 type I fractures, 11 coronal and 6 sagittal and 2 crush fractures.

Time interval for Surgery: In this study Talar neck fracture 12 patients (48%) were operated within 24 hours, 5 patients (20%) were operated on 2nd day, 1 case (4%) was operated in 2nd week and 1 case (4%) was operated after 2 weeks due to skin problems and massive swelling.

In Heather A. Vallier et al 86 study the average time from injury to fixation was 3.7 days (range, four hours to forty-eight days).

ORIGINAL ARTICLE

In Talar body fractures 2 patients (40%) under gone surgery within 24 hours, 1 patient (20%) was operated on 2nd day, 1 patient (20%) was operated on 3rd day and 1 patient (20%) was operated on 5th day.

In Nabil A. Ebraheim et al 32 study the average time from injury to surgery was 2 days with seven patients undergoing surgery less than 24 h after sustaining the fracture; the range was 9 h to 13 days.

Types of Implant: In this study the talar neck fracture are fixed with screws and plating (Plate with screws). In 18 patients (72%) screws were used, In 5 patients (20%) plates with screws were used and In 2 patients (8%) plates and screws were used. Commonly screws were used non-comminuted fractures and plates for comminuted talar neck fractures.

In Heather A. Vallier et al 86 study talar neck fractures treated with stainless steel small-fragment and/or mini-fragment implants (Plates and/or screws).

The talar body fracture are fixed with screws and plating (Plate with screws). In 2 patients (40%) screws were used, in 1 patients (20%) plates were used and in 1 patients (20%) plates and screws were used. Commonly screws were used.

In Nabil A. Ebraheim et al 32 study Cancellous screws (4 mm) and small Herbert screws were used according to the fracture pattern.

SURGICAL APPROACH: In this study talar neck fractures approached through single or dual approach with or without malleolar osteotomy. Dual approach used for 16 fractures (Anteromedial and anterolateral for 12 fractures, anteromedial and poster lateral for 1 fractures, anterolateral and poster lateral for 2 fractures and anteromedial and poster medial for 1 fracture) , anteromedial approach for 5 fractures ,anterolateral approach for 2 fractures and percutaneous fixation used for 2 fractures

In Heather A. Vallier et al 86 study Dual anteromedial and anterolateral surgical approaches were used for ninety-one fractures. The remaining fractures were treated through a single medial approach (eight fractures) or a single lateral approach (three fractures). Eight patients also had an osteotomy of the medial malleolus to enhance the surgical exposure.

In this study talar body fractures approached through single or dual approach with or without malleolar osteotomy. Dual approach used for 3 fractures (Anteromedial and anterolateral), anteromedial approach for 1 fractures, anterolateral approach for 1 fracture.

In Nabil A. Ebraheim et al 32 study the surgical approach depended upon the fracture pattern and hence a single or combined approach was used. Medial malleolar osteotomy was also performed if a better exposure was needed. Medial approach was used in six procedures, the lateral approach was used in three and a combined approach was performed in ten. A medial osteotomy was performed in Six patients for better exposure of the fracture. No fibular osteotomy were performed.

Follow-up Period: In this study follow-up done for one year for both talar neck fractures and talar body fractures.

In Heather A. Vallier et al 86 study sixty talar neck fractures were evaluated at an average of thirty-six months (range, twelve to seventy-four months) after surgery. In Nabil A. Ebraheim et al 32 study of talar body fractures Average follow-up was 26 months (range: 18–43).

ORIGINAL ARTICLE

Duration of Union: In this study 16 talar neck fractures of 25 talar neck fractures (92%) united at the end of 12 weeks. In 1 patient (4%) delayed union occurred. In 1 patient (4%) non-union occurred.

In Heather A. Vallier et al 86 study fifty seven fractures (95%) united within three months ,three of the sixty fractures did not demonstrate radiographic evidence of union within the first three months (two patients (3.33%) had nonunion and one patient (1.66%) had delayed union).

In this study all talar body fractures (100%) united within 12 weeks. In Nabil A. Ebraheim et al 32 study 18 fractures (94.74%) united within 12 weeks there was delayed union in one fracture (5.26%).

Complications:

Superficial Infection:

In this study two patients (8%) of 25 patients with talar neck fractures developed superficial infection after internal fixation. These two patients were successfully managed with oral antibiotics and dressing changes.

In Heather A. Vallier et al 86 study two of 60 patients (3.33%) had development of a superficial infection superficial infection in talar neck fractures.

In this study no patient with talar body fracture developed superficial infection after internal fixation of talar body fracture.

In Nabil A. Ebraheim et al 32 study two patients (10.52%) of 19 patients developed superficial wound infections superficial infection in talar body fractures.

Deep Infection: In this study one patients (4%) of 25 patients with talar neck fractures developed deep infection after internal fixation. This patient was successfully managed with serial irrigation and debridement and intravenous administration of antibiotics.

In Heather A. Vallier et al 86 study 5.0% (3 of 60) patients developed deep infection. In this study no patient with talar body fracture developed deep infection after internal fixation of talar body fracture. In Nabil A. Ebraheim et al 32 study 5.26% (1 of 19) developed deep infection.

Wound Dehiscence: In this study one patients (4%) of 25 patients with talar neck fractures developed wound dehiscence after internal fixation. This patient was successfully managed with serial irrigation and debridement and intravenous administration of antibiotics. In Heather A. Vallier et al 86 study 3.3% (2 of 60) patients developed wound dehiscence. In this study no patient with talar body fracture developed wound dehiscence after internal fixation of talar body fracture. In Nabil A. Ebraheim et al 32 study one patient (5.26%) of 19 developed partial wound dehiscence.

Delayed union: In this study one patients (4%) of 25 patients with talar neck fractures developed Delayed union after internal fixation. In Heather A. Vallier et al 86 study 1.7% (1 of 60) patient developed delayed union. In this study no patient with talar body fracture developed delayed union after internal fixation of talar body fracture In Nabil A. Ebraheim et al 32 study one patient (5.26%) of 19 developed delayed union.

Non-union: In this study one patients (4%) of 25 patients with talar neck fractures developed nonunion after internal fixation. In Heather A. Vallier et al 86 study 3.3% (2 of 60) patient developed nonunion. In this study no patient with talar body fracture developed nonunion after internal fixation of talar body fracture. In Nabil A. Ebraheim et al 32 study no patient developed nonunion

ORIGINAL ARTICLE

Malunion: In this study one patients (4%) of 25 patients with talar neck fractures developed malunion after internal fixation. In Heather A. Vallier et al 86 study no patient developed malunion.

In this study no patient with talar body fracture developed malunion after internal fixation of talar body fracture In Nabil A. Ebraheim et al 32 study one patient developed malunion.

OSTEONECROSIS IN TALAR NECK FRACTURES: In this study of talar neck fractures radiographic evidence of osteonecrosis was identified in thirteen (52%) of twenty five patients. Osteonecrosis was seen in association with five (41.66%) of twelve Hawkins' II fractures, four (50%) of eight Hawkins' III fractures, and four (80%) of five Hawkins' IV fracture. Over all AVN in talar neck fractures-52%.

In Heather A. Vallier et al 86 study Radiographic evidence of osteonecrosis was identified in nineteen (49%) of thirty-nine patients. Osteonecrosis was seen in association with nine (39%) of twenty-three Hawkins' II fractures, nine (64%) of fourteen Hawkins' III fractures, and one Hawkins' IV fracture.

AVN IN TALAR BODY FRACTURES: In this study of talar body fractures radiographic evidence of osteonecrosis was identified in two (40%) of five patients. Nabil A. Ebraheim et al 32 study avascular necrosis developed in seven patients (36.84%).

Osteoarthritis: In this study four (16%) of twenty-five talar neck fractures developed osteoarthritis. In Heather A. Vallier et al 86 study Twenty-one (54%) of thirty-nine patients had development of posttraumatic arthritis. When comparing this study with Heather A. Vallier et al 86 study the prevalence of osteoarthritis was low in present study because this study was a short term follow-up study whereas Heather A. Vallier et al 86 study was a long term follow-up study. In this study one patient (20%) of five talar body fractures developed osteoarthritis. In Nabil A. Ebraheim et al 32 study 11 patients (58%) of 19 talar body fractures developed osteoarthritis.

When comparing this study with Nabil A. Ebraheim et al 32 study the prevalence of osteoarthritis was low in present study because this study was a short term follow-up study whereas Nabil A. Ebraheim et al 32 study was a midterm follow-up study.

This study, which included only isolated displaced talar neck and talar body fractures, confirms previous reports of osteonecrosis but prevalence of posttraumatic arthritis was low as this study was short-term follow-up study.

In our study of isolated displaced talar neck and body fractures, the prevalence of osteonecrosis was 50%. The rate of osteonecrosis was associated with the Hawkins classification, as was noted in other published reports. The rate of osteonecrosis was not related to the timing of fixation but rather to the initial degree of fracture displacement.

It is probable that modern techniques of fixation offer enough stability and compression to allow revascularization to occur even after a delay in treatment. It appears that the severity of the injury itself, and not a delay in fracture fixation, may ultimately be responsible for higher rates of osteonecrosis.

Functional outcome: In the present study functional outcome is assessed by American Orthopedic Foot and Ankle Society (AOFAS) Ankle Hind foot scoring.

In this study in 2 patients (8%) of 25 talar neck fractures treated with plate and/or screws had excellent functional outcome, 11 had patients (44%) good functional outcome, 8 patients (32%) had fair functional outcome, poor functional outcome in 4 patients (16%).

ORIGINAL ARTICLE

In Heather A. Vallier et al 86 study, of the forty-five patients who completed functional outcome questionnaires, thirty-two (71%) had returned to work. Five were employed in jobs involving heavy construction or industrial work. Six patients who had returned to work had modified their work duties because of the injury. Two patients had been unemployed before the talar fracture, and one of them was working at the time of the most recent follow-up. The other patient was not employed outside of the home, however, he reported that he did not feel limited by the injury.

Two women who were more than sixty-five years of age had not been employed before the talar fracture. Both of them reported that they felt severely limited because of the foot injury. Eleven patients never returned to any form of employment. One of these patients was not capable of working because of a severe closed head injury that had been sustained during the same accident.

In this study talar body fracture fixed with plate and/or screws, 1 patient (20%) had excellent functional outcome, 2 patients (40%) had good functional outcome, 1 patient (20%) had fair functional outcome and 1 patient (20%) had poor functional outcome.

In Nabil A. Ebraheim et al 32 study four patients (21%) of 19 talar body fractures had excellent functional outcome, six patients (31.6%) had good functional outcome four patients (21%) had fair functional outcome and five patients (26.3%) had poor functional outcome.

CONCLUSION:

1. Displaced talar neck and/or body fractures should be treated with anatomical reduction and internal fixation.
2. A delay does not appear to adversely affect the outcome, specifically with regard to the development of osteonecrosis.
3. Osteonecrosis developed after 50% of the isolated, displaced talar neck and/or body fractures and probably is a result of the degree of displacement.
4. Comminuted fractures fared dramatically worse than non comminuted fractures with regard to nearly all aspects evaluated especially post traumatic arthritis.
5. Patients with a displaced fracture of the talus should be counseled that osteonecrosis, posttraumatic arthritis and chronic pain are expected outcomes even after anatomic reduction and rigid internal fixation.

REFERENCES:

1. Robert W. Bucholz, Charles M. Court-Brown, James D. Heckman et al; Rockwood And Green's Fractures In Adults, 7th Edition ,volume 2,Page 2022-2061.
2. S. Terry Canale, James H. Beaty; Campbell's operative orthopaedics, 12th Edition, 4th volume, Page 4157-4177.
3. Anderson HG. The medical and surgical aspects of aviation. London: Oxford University Press, 1919.
4. Coltart WD. Aviator's astragalus. J Bone Joint Surg 1952; 34B:545-566.
5. Hawkins LG. Fractures of the neck of the talus. J Bone Joint Surg 1970; 52A:991-1002.
6. Rodrigues RC, Masiero D, Mizusaki JM, Imoto AM, Peccin MS, Cohen M et al. Translation, cultural adaptation and validity of the .american orthopaedic foot and ankle society (AOFAS) ankle-hindfoot scale. Acta Ortop Bras. [Serial on the Internet]. 2008; 16 (2):107-111.

ORIGINAL ARTICLE

7. Sneppen O, Christensen SB, Krogsoe O, et al. Fracture of the body of the talus. *Acta Orthop Scan* 1977; 48:317-324. Swanson TV, Bray TJ, Holmes GB Jr. Fractures of the talar neck. A mechanical study of fixation. *J Bone Joint Surg Am* 1992;75:544-551.
8. Vallier HA, Nork SE, Barei DP, et al. Talar neck fractures: results and outcomes. *J Bone Joint Surg* 2004; 86-A: 1616-1624.
9. Nabil A. Ebraheim, et al, Clinical outcome of fractures of the talar body *Int Orthop*. Dec 2008; 32 (6): 773-777, Epub jun 22 2007. doi: 10.1007/s00264-007-0399-5. Hawkins LG. Fractures of the neck of the talus. *J Bone Joint Surg* 1970; 52A:991-1002.

AUTHORS:

1. S. Sreenivasa Reddy
2. Y. Thimma Reddy
3. Ravikiran
4. Kali Vara Prasad Vadlamani
5. D. Narender

PARTICULARS OF CONTRIBUTORS:

1. Former Professor, Department of Orthopedics, Osmania Medical College Hyderabad.
2. Associate Professor, Department of Orthopedics, Osmania Medical College Hyderabad.
3. Assistant Professor, Department of Orthopedics, Osmania Medical College Hyderabad.

FINANCIAL OR OTHER

COMPETING INTERESTS: None

4. Associate Professor, Department of Orthopedics, Osmania Medical College Hyderabad.
5. Consultant Orthopedic Surgeon, Department of Orthopedics, Hyderabad.

NAME ADDRESS EMAIL ID OF THE CORRESPONDING AUTHOR:

Dr. Kali Vara Prasad Vadlamani,
F12, Sneha Enclave, St. No. 4,
West Maredpally,
Secunderabad-500026.
E-mail: prasadvkv@gmail.com

Date of Submission: 02/09/2015.
Date of Peer Review: 04/09/2015.
Date of Acceptance: 14/09/2015.
Date of Publishing: 15/09/2015.