

**SPLIT SKIN GRAFT HARVESTING UNDER LOCAL ANESTHESIA INFILTRATION VERSUS TOPICAL LOCAL ANESTHESIA**K. S. Shahi<sup>1</sup>, Geeta Bhandari<sup>2</sup>, Bhuvan<sup>3</sup>, Prashant<sup>4</sup>, Sanjeev<sup>5</sup>, Rakesh<sup>6</sup>, Malvika<sup>7</sup>**HOW TO CITE THIS ARTICLE:**

K. S. Shahi, Geeta Bhandari, Bhuvan, Prashant, Sanjeev, Rakesh, Malvika. "Split Skin Graft Harvesting under local Anesthesia Infiltration versus Topical Local Anesthesia". Journal of Evolution of Medical and Dental Sciences 2014; Vol. 3, Issue 17, April 28; Page: 4615-4620, DOI: 10.14260/jemds/2014/2485

**ABSTRACT: OBJECTIVE:** To compare the effectiveness of topical local anesthesia using PRILOX cream versus local anesthesia infiltration using lignocaine and adrenaline in harvesting split skin graft. **METHODS:** A prospective study of 58 patients requiring split skin graft was carried. One group comprising 29 patients underwent harvesting of split skin graft under topical local anesthesia using PRILOX cream while the other group had local anesthesia infiltration using lignocaine and adrenaline. **RESULTS:** There were no significant differences between the 2 groups in terms of operating time, per operative pain, post-operative pain and post-operative requirement of analgesia. There was significant difference in time and pain during administration of local anesthesia and patient's acceptability/ satisfaction with method of anesthesia. **CONCLUSION:** Topical local anesthesia using PRILOX cream can be used effectively for harvesting of split skin graft and is good alternative to local anesthesia infiltration.

**KEYWORDS:** local anesthesia, topical anesthesia, split skin graft, PRILOX, pain.

**INTRODUCTION:** The harvesting of skin grafts under local anesthetic has been confined conventionally to those patients in whom only a small area of skin was required. Regional anesthesia is not often used for harvesting of split skin graft because of the unpredictable area of full anesthesia. Harvesting of split skin graft under local anesthesia require infiltration of relatively large volume of lignocaine and adrenaline beneath the skin and is a painful procedure. This has led to the use of general anesthesia for the majority of cases requiring skin grafts.<sup>1</sup>

Topical anesthesia can an ideal replacement for painful local anesthesia infiltrations, but the keratinized layer of the skin provides an effective barrier to diffusion.<sup>2</sup> The highly lipophilic amino-ester, ketocaine, was introduced in the late 1970s as an effective topical anesthetic for intact skin but was withdrawn due to local toxic reactions, especially upon repeated application<sup>3</sup>. PRILOX cream is a eutectic mixture of the two established safe local anesthetics, lignocaine and prilocaine, in a vehicle of emulsifier, stabiliser and water at pH 9.4<sup>2</sup>

The eutectic phenomenon is the spontaneous lowering of the melting point of two substances when the solid forms are mixed together. This occurs at room temperature in the case of lignocaine and prilocaine, and the resultant oil considerably increases the concentration of local anesthetic which can be formulated into an emulsion.<sup>2</sup> With PRILOX, sufficient anesthetic diffuses into the superficial layers of the skin to produce a clinically useful effect.

The anesthetic properties of this cream have been established in a number of controlled clinical trials, mainly concerned with alleviating the pain associated with venipuncture.<sup>4-6</sup> However, Ohlsen et al. have evaluated the efficacy of EMLA for harvesting split skin grafts in a trial of 146 patients. They were able to show that very low plasma concentrations of both lignocaine and prilocaine were detected even after large skin areas had been anaesthetized.<sup>7</sup>

## ORIGINAL ARTICLE

**OBJECTIVE:** To compare the effectiveness of topical local anesthesia using PRILOX cream versus local anesthesia infiltration using lignocaine and adrenaline in harvesting split skin graft.

**METHODS:** A prospective study was carried out comprising 58 patients requiring split skin grafting. The study was done during the period of October 2012 to September 2013. Fifty-eight patients (32 males, 26 females), with ages ranging from 17 to 73 years (mean 42 years) were enrolled into the study and divided into either treatment groups by use of random numbers. The two groups were matched in respect to age, sex, weight and indications for split skin grafting (Table: 1).

The patient having known history of allergic hypersensitivity to local anesthesia, skin disease and patient not giving consent were excluded from the study. The choice of donor site was restricted to the thigh and the maximum area considered was 100 cm.<sup>2</sup> The indications for need of graft were noted for each patient's. All the patients were kept in surgical ward to watch for post- operative pain, need of analgesia and review for patient's acceptability/satisfaction.

In local anesthesia infiltration group, lignocaine 0.5% and adrenaline 1: 200, 000 were administered by subcutaneous infiltration using a 25 G needle, 5 minutes prior to graft harvesting. In topical local anesthesia group, the donor site was shaved and cleaned with an alcohol swab before marking an area of 100 cm.<sup>2</sup> The PRILOX cream was applied in a thick layer evenly using 30 g PRILOX cream tube over 100 cm<sup>2</sup> and covered with an occlusive dressing.

The application of PRILOX cream and occlusive dressing took about 5 minutes. The PRILOX cream and occlusive dressing were kept in place for 90 minutes. The time of application and removal of PRILOX were noted. Grafts harvesting was done conventionally using a Humby knife. Discomfort experienced during the preparation of the site and the pain experienced during graft cutting were assessed using visual analogue scale.<sup>8</sup>

	<b>PRILOX CREAM (N=29)</b>	<b>LIGNOCAINE+ ADRENALINE(N=29)</b>
<b>MEAN AGE:</b>	41 YEARS	43 YEARS
<b>SEX: MALE</b>	15	17
FEMALE	14	12
<b>MEAN WEIGHT:</b>	56 KG	57.5 KG
<b>INDICATIONS:</b>		
BURN WOUNDS	2	3
LEG ULCER	4	3
TRAUMATIC LOSS	10	12
TATTOO EXCISION	7	6
CONTRACTURE RELEASE	4	3
OTHERS	2	2

Table 1: Patients variables

## ORIGINAL ARTICLE

**RESULTS:** The mean time for application of topical local anesthesia was 100 minutes and 11 minute in local anesthesia infiltration. In topical anesthesia group, PRILOX cream caused no discomfort to any of the patients during application. In local anesthesia infiltration group, varying degrees of pain from 20 to 94 on the visual analogue pain scale were recorded during infiltration (Figure: 1).

The degree of pain or discomfort local anesthesia infiltration was positively correlated with the volume of anesthetic administered. The donor sites were examined for side-effects immediately before graft cutting. Transient erythema was noted in only 3 PRILOX-treated patients, while pallor was noted in 18 in PRILOX treated group and 22 in local anesthesia infiltration group. Bleeding from donor site was more profuse in topical local anesthesia group.

The pain felt during graft harvesting in the two groups was recorded using visual analogue and verbal rating scale scores. The mean VAS pain scores were 6 in topical local anesthesia group and 15 in local anesthesia infiltration group (Figure: 2).

The pain felt in post-operative period and need for analgesia in post-operative period was same in both groups. The patients in topical local anesthesia group were more satisfied and reported the procedure as 'very good' and in local anesthesia infiltration group the patients reported the procedure as 'good' (Table: 2).

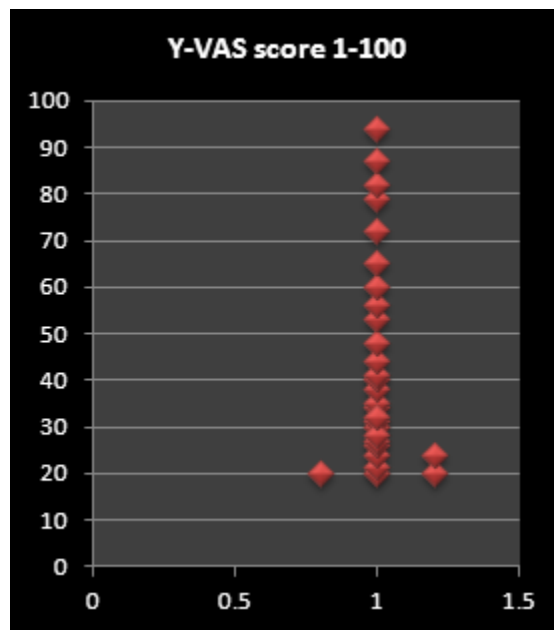


Figure 1

Figure 1: Scatter diagram showing level of pain on VAS during infiltration of local anesthesia. Pain level in topical local anesthesia on VAS is 0

## ORIGINAL ARTICLE

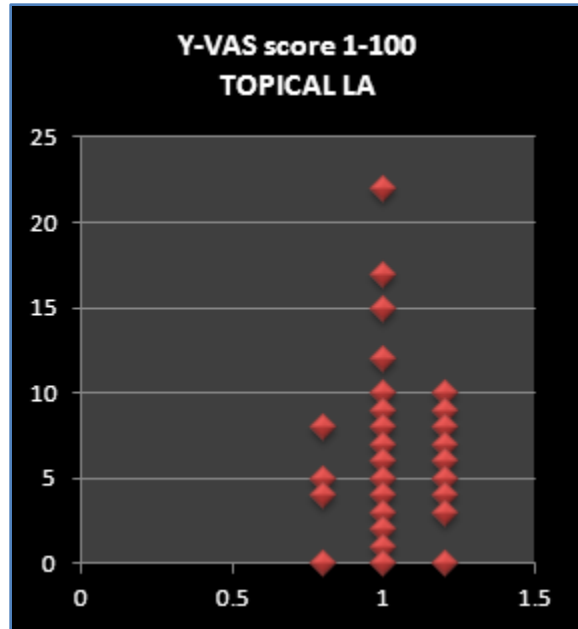


Figure 2 (A)

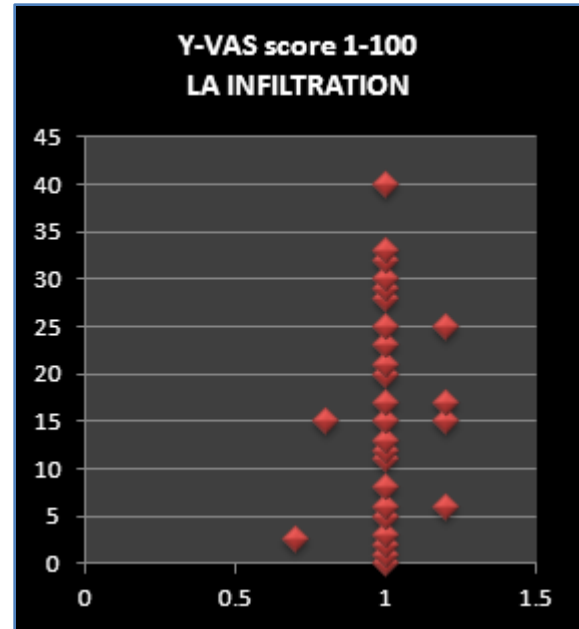


Figure 2 (B)

Figure 2: Scatter diagram showing pain level on VAS during harvesting of split skin graft. (A) Topical local anesthesia; (B) Local anesthesia infiltration.

	TOPICAL LOCAL ANAESTHESIA	LOCAL ANAESTHESIA INFILTRATION
MEAN TIME OF APPLICATION OF LA	100 MINUTES	11 MINUTES
ERYTHEMA	3	0
PALLOR	18	22
BLEEDING FROM DONOR SITE	7	0
MEAN OPERATING TIME	30 MINUTE	30 MINUTE
MEAN VAS SCORE FOR PER OPERATIVE PAIN	6	15
PAIN IN POST OPERATIVE PERIOD	5 HOURS	5.5 HOURS
REQUIREMENT OF ANALGESIA IN POST OPERATIVE PERIOD	SAME	
PATIENT ACCEPTABILITY/SATISFACTION	VERY GOOD	GOOD

Table 2: Comparison of various parameters in topical local anaesthesia and local anaesthesia infiltration

**DISCUSSION:** A eutectic mixture of local anesthetics (EMLA) contains 2.5% lidocaine and 2.5% prilocaine in an oil and water emulsion and has been found to give effective, safe analgesia on normal and diseased skin, making it useful for numerous medical and surgical procedures, such as anesthesia for superficial surgery, split-thickness skin grafts, venipuncture, argon laser treatment, epilation, and debridement of infected ulcers. Other indications have included use in post-herpetic neuralgia,

## ORIGINAL ARTICLE

---

hyperhidrosis, painful ulcers, and inhibition of itching and burning. To be effective, EMLA should ideally be applied to the desired area for at least 1 hour under an occlusive dressing. The medication has been approved since May 1991 in Canada for use on intact skin and has been available in Europe for many years.<sup>9</sup>

The absorption of EMLA cream by normal and diseased skin in adults is different. In normal skin, absorption is faster on the face than on the upper arm. In the case of skin affected by psoriasis or eczema, absorption is faster, with anesthesia noted in 15 min compared to 60 min in normal skin. However, the duration of anesthesia was shorter (15-30 min). Similar results were noted in children with atopic dermatitis.<sup>10, 11</sup>

This study clearly demonstrates that PRILOX topical anesthetic is as effective as conventional infiltration for harvesting split skin grafts, with markedly less discomfort associated with anesthetic administration.<sup>1,7</sup> Bleeding from donor site was more profuse in the PRILOX group, because PRILOX contains no vasoactive compound such as the adrenaline.<sup>1</sup>

**CONCLUSIONS:** Topical local anesthesia using PRILOX cream can be used effectively for harvesting of split skin graft and is good alternative to local anesthesia infiltration. This method causes no pain during application and have good patient's acceptability/satisfaction.

### REFERENCES:

1. Goodacre TEE, Sanders R, Watts DA, Stoker M. Split skin grafting using topical local anaesthesia (EMLA): a comparison with infiltrated anaesthesia. *British Journal of Plastic Surgery* (1988). 41, 533-538.
2. Gajraj NM, Pennant JH, Watcha MF. Eutectic Mixture of Local Anesthetics (EMLAB) Cream. *Anesth Analg* 1994;78:574-83
3. Ponten B, Ohlen L. Skin surface application of ketocaine to provide local anaesthesia for cutting split skin grafts. *British Journal of Plastic Surgery* 1977, 30, 251.
4. Juhlin L, Evers H, Bromberg F. A lidocaine prilocaine cream for superficial skin surgery and painful lesions. *Acta Dermatovenereologica (Stockholm)* 1980, 60, 544.
5. Ehrenstram-Reiz G M E, Reiz S L A. EMLA-a eutectic mixture of local anaesthetics for topical local anaesthesia. *Acta Anaesthesiologica Scandinavica* 1982, 26, 596.
6. Hallen B, Carlsson P, Uppfeldt A. A clinical study of lignocaine-prilocaine cream to relieve the pain of venepuncture. *British Journal of Anesthesia* 1985, 57, 326.
7. Ohlisen L, Engiesson S, Evers H. An anaesthetic lidocaine/prilocaine cream (EMLA) for epicutaneous application tested for cutting split skin grafts. *Scandinavian Journal of Plastic and Reconstructive Surgery* 1985, 19, 201.
8. Scott J, Huskisson E C. Graphic representation of pain. *Pain* 1976, 2, 175.
9. Barry ASL. EMLA A New and Effective Topical Anesthetic: *The Journal of Dermatologic Surgery and Oncology*, Volume 18, October 1992, Issue 10, 859-862.
10. Juhlin L, Hagglund G, Evers H. Absorption of lidocaine and prilocaine after application of a eutectic mixture of local anesthetics (EMLA) on normal and diseased skin. *Acta Derm Venereol* 74111925 (Stockh) 1989; 69:18-22.
11. Juhlin L, Rollman O. Vascular effects of a local anesthetic mixture in atopic dermatitis. *Acta Derm Venereol (Stockh)* 1984; 64:439-40.

**AUTHORS:**

1. K. S. Shahi
2. Geeta Bhandari
3. Bhuvan
4. Prashant
5. Sanjeev
6. Rakesh
7. Malvika

**PARTICULARS OF CONTRIBUTORS:**

1. Professor, Department of Surgery, GMC, Haldwani.
2. Professor, Department of Anaesthesiology, GMC, Haldwani.
3. Assistant Professor, Department of Surgery, GMC, Haldwani.
4. Senior Resident, Department of Surgery, GMC, Haldwani.

5. Junior Resident, Department of Surgery, GMC, Haldwani.
6. Junior Resident, Department of Surgery, GMC, Haldwani.
7. Junior Resident, Department of Surgery, GMC, Haldwani.

**NAME ADDRESS EMAIL ID OF THE CORRESPONDING AUTHOR:**

Dr. K. S. Shahi,  
Department of Surgery,  
GMC, Haldwani.  
E-mail: kedar\_shahi@rediffmail.com

Date of Submission: 26/03/2014.

Date of Peer Review: 27/03/2014.

Date of Acceptance: 05/04/2014.

Date of Publishing: 26/04/2014.