

# CASE REPORT

---

## MALPOSITION OF SUBCLAVIAN CENTRAL VENOUS CANNULATION INTO IPSILATERAL INTERNAL JUGULAR VEIN – AN UNUSUAL CASE REPORT

(Major) Vishal Arora<sup>1</sup>, Sumantra Saha<sup>2</sup>, (Col) Rajnikant Tripathi<sup>3</sup>, Dilpreet Kaur<sup>4</sup>, Shweta Chitranshi<sup>5</sup>

### HOW TO CITE THIS ARTICLE:

(Major) Vishal Arora, Sumantra Saha, (Col) Rajnikant Tripathi, Dilpreet Kaur, Shweta Chitranshi. "Malposition of subclavian central venous cannulation into ipsilateral internal jugular vein – an unusual case report". Journal of Evolution of Medical and Dental Sciences 2013; Vol. 2, Issue 46, November 18; Page: 8895-8898.

**ABSTRACT:** Central venous catheterization (CVC) via infraclavicular subclavian approach in neurosurgical patients is very common practice. Malpositioning of central venous catheter inserted into subclavian vein is a known and dreaded complication. Malpositioning of catheter tip into ipsilateral jugular vein is an unusual occurrence. We hereby describe a case where a subclavian central venous catheter malpositioned into ipsilateral jugular vein.

**KEY WORDS:** flush test, jugular, malpositioning.

**INTRODUCTION:** Exact placement of central venous catheters (CVC) is an essential prerequisite for long-term use of a central venous catheter. Unfortunately, malpositioning of the same is a known complication with reported incidence in an extremely wide range from less than 1% to more than 60%<sup>1</sup>. When subclavian CVC placement is done, malpositioning occurs most commonly to ipsilateral internal jugular vein<sup>2</sup>.

**CASE REPORT:** A 23 year old male with meningioma, posted for craniotomy was planned to have central line placement for central venous access. A CVC was placed in right subclavian through a conventional infraclavicular route using Seldinger technique. The guide wire was threaded freely through the needle without resistance and a 7F triple lumen catheter (Centrifix, B Braun, Germany) was passed over the guide wire again without any unusual resistance. The catheter was fixed at the 14 cm mark and adequate backflow of blood and free inflow of injected saline confirmed intravenous positioning.

Malposition of catheter tip was crosschecked by performing flush test, which was positive on the ipsilateral side of the neck<sup>2</sup>. This confirmed the catheter tip placement in the right IJV that was further substantiated by the post-operative chest X-ray (Fig 2). This CVC was removed and a left side subclavian CVC line was placed subsequently.

**DISCUSSION:** Central venous catheter insertion is a common procedure used in monitoring CVP, administration of some drugs, blood and blood products, antineoplastic treatment, parenteral nutrition, and bone marrow transplantation. Central venous catheters can be centrally or peripherally inserted; however, the commonly preferred technique is the internal jugular or subclavian veins<sup>3</sup>. These complications can be listed as arterial puncture, pneumothorax, chylothorax, vein and nerve damage, infection, thrombosis, malposition, folding of the catheter, hemothorax, cardiac tamponade, air embolism, arrhythmia and even death<sup>4-6</sup>.

During subclavian vein catheterization, the most common misplacement of the catheter is cephalad, into the ipsilateral internal jugular vein (IJV), accounting for about 60% of all malpositioning<sup>7</sup>. The J wire advanced via the indirect technique may malposition and anatomically

## CASE REPORT

follow the upper wall of subclavian vein. Other sites for malpositioning mentioned in literature include the azygos vein, left superior intercostal vein and the thymic vein<sup>8</sup>. We followed standard approach using anatomical landmarks as guiding factors. Studies have hypothesized that the final position of the catheter tip depends on course of the guide wire takes which may be influenced by the initial orientations of the J-type guide wire tip during the subclavian approach<sup>9-10</sup>. A randomized, controlled study suggests that keeping the guide wire J- tip directed caudad increased correct placement of central venous catheters towards the right atrium<sup>10</sup>. However it is near impossible to maintain the catheter tip in any particular orientation when doing this procedure without any fluoroscopic guidance.

Excessive lengths of guide wire and the length of the CVC inserted may itself be an alternative cause. It is recommended that an 18 cm length should be considered the upper limit of guide wire introduced during central catheter placement in adults. It is opined that the average safe insertion depth for a central venous catheter from the left or right subclavian vein is 16.5 cm for the majority of adult patients and that a central venous catheter should not be routinely inserted to a depth of > 20 cm. Use of ultrasound to direct insertion of CVC is controversial. Some authors suggest that ultrasound guidance improves the success rate of subclavian venous catheterization performed by less experienced operators<sup>11</sup>. On the other hand, other authors find that ultrasound guidance had no effect on the rate of complications or failures of subclavian- vein catheterization<sup>12</sup>. Hence, insertion of CVC remains essentially a blind procedure which utilizes guidance of fixed bony points. This would always result in a chance of malpositioning the catheter.

Flush test may be a useful bedside test to rule out the malposition of CVC tip into the IJV in situations where X-ray chest is not immediately available, such as intraoperative CVC placement. Flush test is carried out by palpating the neck over the region of IJV with the palmer aspect of the hand while flushing the CVC with 5–10 mL of normal saline using a syringe. If the tip of the CVC lies in the IJV, a fluid thrill felt by the palm or a bruit can be heard over the IJV using a stethoscope. This test has 100% sensitivity and specificity for detecting malpositioned CVC into the ipsilateral IJV. However, other malpositions may not be ruled out by this test as suggested by the authors<sup>13</sup>. Use of modalities such as intraluminal ECG guidance and flush test can guide the correct placement of CVC tip and prevent complications arising from malposition of CVCs.

The IJV occlusion test is another novel test that rapidly detects the misplacement of subclavian vein catheter into the IJV<sup>7</sup>. However, it does not detect any other misplacement. The test may allow avoidance of repeated exposure to x-rays after catheter insertion and repositioning.

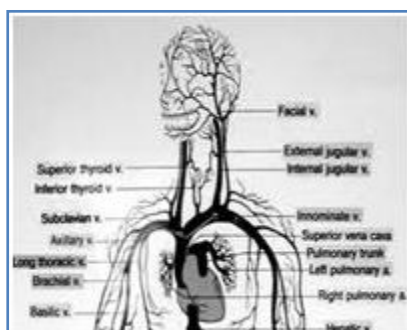


Fig. 1: Great vessels of mediastinum and neck

## CASE REPORT

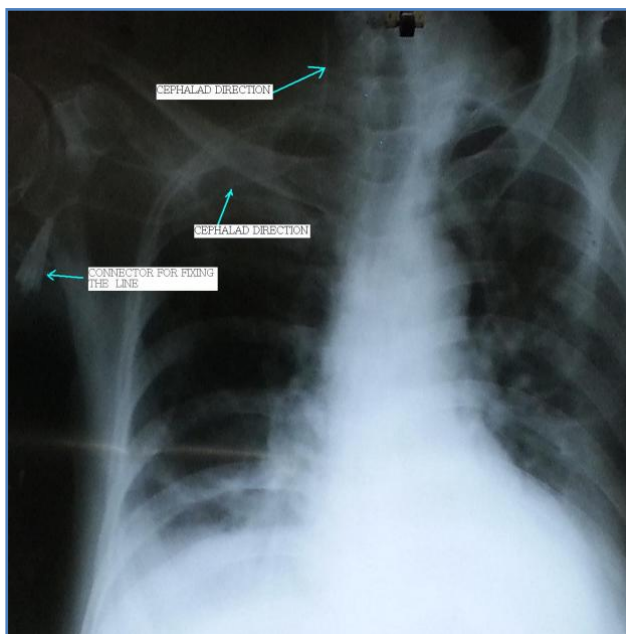


Fig. 2: Chest X Ray post CVP insertion

### REFERENCES:

1. Malatinský J, Kadlic T, Májek M, Sámel M. Misplacement and loop formation of central venous catheters . *Acta Anaesthesiol Scand* 1976;20:237-47.
2. Unal AE, Bayar S, Arat M, Ilhan O. Malpositioning of Hickman catheters, left versus right sided attempts. *Transfus Apher Sci* 2003 ;28:9-12.
3. Gladwin MT, Slonim A, Landucci DL, Gutierrez DC, Cunnion RE. Cannulation of the internal jugular vein: is postprocedural chest radiography always necessary? *Crit Care Med* 1999;27:1819-1823
4. Polderman KH, Girbes AR. Central venous catheter use Part 1: mechanical complications. *Intensive Care Med* 2002;28:1-17
5. Wicky S, Meuwly JY, Doenz F, Uske A, Schnyder P, Denys A. Life-threatening vascular complications after central venous catheter placement. *Eur Radiol* 2002; 12:901-907.
6. De Jonge RC, Polderman KH, Gemke RJ. Central venous catheter use in the pediatric patient: Mechanical and infectious complications. *Pediatr Crit Care Med* 2005; 6:329-339.
7. Ambesh SP, Pandey JC, Dubey PK. Internal jugular vein occlusion test for rapid diagnosis of misplaced subclavian vein catheter into the internal jugular vein. *Anesthesiology* 2001;95:1377-9.
8. Currarino G. Migration of jugular or subclavian venous catheters into inferior tributaries of the brachiocephalic veins or into the azygos vein, with possible complications. *Pediatr Radiol* 1996;26:439-49.
9. Hwang JW, Han SH, Bahk JH, Oh YS. Influence of orientations of guide wire tip on the placement of subclavian venous catheters. *Acta Anaesthesiol Scand* 2005;49:1460-3.

# CASE REPORT

---

10. Tripathi M, Dubey PK, Ambesh SP. Direction of the J-tip of the guidewire, in seldinger technique, is a significant factor in misplacement of subclavian vein catheter: a randomized, controlled study. *Anesth Analg* 2005 ;100:21-4.
11. Gualtieri E, Deppe SA, Sipperly ME, Thompson DR. Subclavian venous catheterization: greater success rate for less experienced operators using ultrasound guidance. *Crit Care Med* 1995;23:692-7.
12. Mansfield PF, Hohn DC, Fornage BD, Gregurich MA, Ota DM. Complications and failures of subclavian-vein catheterization. *N Engl J Med* 1994;29:1735-8.
13. Toshniwal GR, Rath GP, Bithal PK. Flush test-a new technique to assess the malposition of subclavian central venous catheter position in the internal jugular vein. *J Neurosurg Anesthesiol.* 2006; 18:268-9.

## **AUTHORS:**

1. (Major) Vishal Arora
2. Sumantra Saha
3. (Col) Rajnikant Tripathi
4. Dilpreet Kaur
5. Shweta Chitranshi

## **PARTICULARS OF CONTRIBUTORS:**

1. Assistant Professor, Department of Anaesthesia, ERA's Lucknow Medical College.
2. Registrar, Department of Anaesthesia, Medica Super Speciality Hospital, Kolkata.
3. Professor and HOD, Department of Anaesthesia, ERA's Lucknow Medical College.
4. JR-II, Department of Anaesthesia, ERA's Lucknow Medical College.

5. JR-I, Department of Anaesthesia, ERA's Lucknow Medical College.

## **NAME ADDRESS EMAIL ID OF THE CORRESPONDING AUTHOR:**

Dr. (Major) Vishal Arora,  
Wisdom Academy, Surendra Nagar,  
Urmilapuri, Kamta, Faizabad Road,  
Lucknow - 227105.

Email - aro\_vish@sify.com  
arovich1974@gmail.com

Date of Submission: 30/10/2013.

Date of Peer Review: 31/10/2013.

Date of Acceptance: 06/11/2013.

Date of Publishing: 12/11/2013