

MYCETOMA: AN UNUSUAL MANIFESTATION OF MULTIPLE BLISTERS

E. Shyamala¹, M. Valluvan², B. Divvyva³, V. Anandi⁴, P. Viswanathan⁵, Rehana Tippoo⁶, B. Krishna Swamy⁷, U. Manohar⁸

HOW TO CITE THIS ARTICLE:

E. Shyamala, M. Valluvan, B. Divvyva, V. Anandi, P. Viswanathan, Rehana Tippoo, B. Krishna Swamy, U. Manohar. "Mycetoma: An unusual Manifestations of Multiple Blisters". *Journal of Evolution of Medical and Dental Sciences* 2014; Vol. 3, Issue 33, Aug 07; Page: 8952-8957, DOI: 10.14260/jemds/2014/3151

ABSTRACT: Four cases of Mycetoma especially among farmers were confirmed both by demonstrating granules in histopathological sections and by isolating *Madurellagrisea* in two patients, *Madurellamycetomatis* in one and *Nocardia* asteroids in one, following retrieval trauma. Eumycotic and Actinomycotic agents produce severe morbidity. One cases of Actinomycotic mycetoma responded to Trimethoprim-Sulphamethasone and the remaining three had antifungal Ketoconazole therapy for six months and did not return up for further follow up. These four cases are being reported here for its unusual clinical manifestations of multiple blisters in the extremities without the sinus tract formation and clinically mycetoma could not be diagnosed and indicates the need for biopsy examination and mycology culture.

KEYWORDS: Mycetoma, *Nocardia*, *Madurella* species.

INTRODUCTION: Mycetoma is a chronic granulomatous inflammatory lesion with oozing sinuses often affects the exposed part of the body. The Infection can be caused by a variety of bacteria and fungi.¹⁻¹⁰ The grains are widely diverse in shape, size, colours, depending on etiologic agents.

Differentiation between the two mycetomas is important as the two etiologic agents have a different course of disease progression and treatment.¹¹⁻¹⁵ The incidence of Mycetoma was first reported from South India. Nowadays the reports on Mycetoma from Tamilnadu are a very few and it is almost a forgotten entity. We report four cases of Mycetoma within a span of eight months, from September 2013 to May 2014. Out of 288 cases of the inflammatory lesions studied, four cases have been reported to be Mycetoma.

MATERIALS AND METHODS: A total of 1038 biopsy material from surgical outpatient and inpatient department, Rajah Muthiah Medical College and Hospital, Annamalai University for histopathological examination were received during September 2013 to May 2014. Mycetoma was specially noted while examining Hematoxylin and Eosin sections of these 1038 biopsy tissues and mycology culture wherever necessary. Four patients were diagnosed to be Mycetoma by histopathology and confirmed by mycology cultures. The details of clinical, histopathology and mycology of these four patients with Mycetoma are described below.

CLINICAL HISTORY:

PATIENT NO. 1: A 50 years old male farmer reported to surgical outpatient department with complaints of swelling and pain on sole of right foot. Clinical history revealed that the patient had Thorn prick about three months back. He was irregularly treated with local application of soframycin on and off. On clinical examination of the right foot revealed tenderness and swelling with multiple blisters.

ORIGINAL ARTICLE

A punch biopsy was taken from the blisters and a part of it was sent for Mycology culture and the remaining biopsy tissue was put in 10% formaldehyde and sent for histopathological examination. Gross examination of excised masses has multiple grey white, grey yellow, grey brown soft tissue pieces largest measuring 3.5 x 1.5 x 0.5 cm, smallest measuring 0.7 x 0.5 cm. On cut section solid grey white, grey yellow areas identified.

Hematoxylin-and-eosin (H & E)-stained section of the biopsy specimen revealed, skin covered soft tissue piece where multiple micro abscesses were present in deep subcutaneous level. Several granules of compact fungus elements were identified. The section showed granuloma composed of histiocytes, plasma cells, giant cells, and polymorphs. The granules were seen within the granuloma.

The periphery of the granules has dense filament of fungal hyphae with a hollow centre having fungal hyphae with granuloma (fig. 1a).

PATIENT NO. 2: A, 29 years old male farmers reported to the surgical outpatient department with complains of swelling and pain on left sole. Clinical history revealed that the patient had thorn prick about two months back. He was treated irregularly treated with Ketoconazole on and off. Clinical examination of left sole revealed tenderness, and swelling with multiple blisters. A punch biopsy was taken from the blister and part of it was sent for mycology culture and the remaining biopsy tissue is put in 10% formaldehyde and sent for histopathological examination.

The patient underwent wide local excision under general anaesthesia, with an uneventful postoperative recovery. Gross examination of the excised mass, which measured 3.5×2.0×1.0 cm size, has grey black, grey brown soft tissue pieces with brown to black granules. On cut section grey black, grey brown areas identified. Haematoxylin-and-eosin (H & E)-stained section of biopsy specimen revealed multiple microabscesses.

Several granules of compact fungal elements were identified. The section showed granulomas composed of histiocytes, plasma cells, giant cells and polymorph. The granules were seen within the granuloma. The periphery of the granules has dense filaments of fungal hyphae with a hollow centre having a few fungal hyphae with granuloma (1b).

PATIENT NO. 3: A 19 years old female reported to surgical outpatient department with complains of swelling and pain on left lower limb. Clinical history revealed that the patient had thorn prick about three months back. She had irregularly treated with local application of betadine ointment and oral antibiotics. Local examination of the left lower limb revealed an irregular mass on her foot. The mass was 5 cm in diameter, firm in consistency, and fixed to the underlying structure; it was tender, and its temperature was slightly elevated.

Her full blood count and other biochemical test are within normal limits. A punch biopsy was taken from the blisters and part of it was sent for mycology culture and the remaining biopsy tissue is put in 10% formaldehyde and sent for histopathological examination. The patient underwent wide local excision under general anaesthesia, with an uneventful postoperative recovery. Gross examination of the excised mass, which measured 3.0×1.0×0.5 cm, has grey white, grey brown soft tissue pieces with brown to black granules.

On cut section grey white, grey yellow areas identified. Haematoxylin-and-eosin (H & E)-stained section of biopsy specimen revealed, skin covered soft tissue with multiple Microabscesses present in deep subcutaneous level. A brown, homogeneous matrix of granules with septate branched fungal hyphae with granuloma is seen (fig. 2).

ORIGINAL ARTICLE

PATIENT NO. 4: A 40 years old female reported to the surgical outpatient department with complaints of swelling and pain on right lower limb. Clinical history revealed that the patient had thorn prick about six months back.

She had irregularly treated with oral antibiotics. Clinical examination of right foot revealed tenderness, and swelling with multiple blisters. A punch biopsy was taken from the blisters and a part of it was sent for Mycology culture and remaining biopsy tissue was put in 10% formaldehyde and sent for histopathological examination.

Patient underwent wide excision biopsy under general anaesthesia, with uneventful postoperative recovery. Gross examination of the excised mass, which measured 7.0×3.0×2.0 cm size, has multiple grey white, grey brown soft tissue pieces. On cut section solid grey white areas were identified. Haematoxylin-and-eosin (H&E)-stained sections of biopsy specimen revealed, skin covered soft tissue up to the deep subcutaneous adipose tissue level identified.

There are multiple sinus tracts lined with inflammatory vascular granulation tissue. There are micro abscesses within the sinus tracts. Inflammatory giant cells and collection of histiocytes are seen. The granules appear pale within Microabscesses and grains were surrounded by inflammatory cells (fig. 3).

Mycology culture of patient 1 and 2 biopsy specimen had brown to black granules. They measure 0.5 to 1 mm in size. The granules were hard, brittle in nature and yielded *Madurella* species. Mycology culture of patient 3 biopsy specimen had yellow to brown granules yielded *Madurella* species and from patient 4 white granules were seen and *Nocardia* asteroides was isolated.

DISCUSSION: Mycetoma is a chronic granulomatous infection, often affects the exposed part of the body. The disease is distributed worldwide. The infections are caused by variety of bacteria and fungi. Differentiation between two causative agents of Mycetoma is important as, the two etiologic agents have a different course of disease progression and treatment.

In this study, from September 2013 to May 2014, there were 4 cases of mycetoma were diagnosed without clinical suspicion, in the pathology department on the basis Haematoxylin and eosin and various special stains as and when needed. Mycetoma usually presents as swelling with sinus tract formation and discharging granules, but in all of our 4 cases, the patient presented with swelling and blisters and granules were seen only after excision and squeezing of it.

The site of infections of all 4 patients is the foot. And all of them are farmers, who did not wear foot wears. All the patients had a history of thorn prick. This article is to highlight that the farmers should be cautious of thorn prick and should cover the feet appropriately which could prevent them from thorn prick.

In this study we found 1 case of bacteria namely *Nocardia* asteroides, and 3 fungi namely *Madurella* species. They were being treated with antimicrobials, antifungal therapy and excision done for not responding to drug therapy. After six months of treatment there was regression and the patient did not turn up for further follow up.

ORIGINAL ARTICLE

No.	Age	Sex	Site	Mycology culture
1	50	Male	Right sole	Madurellagrisea
2	29	Male	Left sole	Madurellagrisea
3	19	Female	Left lowerLimb	Madurellamycetomatis
4	40	Female	Right lower limb	Nocardiaasteroides

Table 1: Cases of Mycetoma and causative organisms

CONCLUSION: Out of 1038 surgical biopsies received from September 2013 to May 2014, there were 288 inflammatory lesions. Of these lesions 4 turned out to be Mycetoma caused by three different species of organisms. The importance of diagnosing and identifying the causative organism is the one which determines the modality of therapy. All except Nocardia (which can be treated with antibiotics), need surgical intervention.

REFERENCES:

- Rippon JW. Medical Mycology. Philadelphia. WB. Saunders Co 1988.
- Chander J. Text book of Medical Mycology. New Delhi. Mehta Publisher; 1995; 114-27
- Kwon-Chung KJ, Bennett JE. Medical Mycology. Lea &FebigerPhiladelphia. London 1992.
- Fahal AH. Mycetoma, Clinicopathological Monograph. Khartoum: Khartoum University Press. 2006
- Gokhale BB. Epidemiology of mycetoma. Hindustan Antibiot Bull 1981; 23: 18-24.
- Bendl BJ, Mackey D, Al-saati F, Sheth KV, Ofole SN, et al. Mycetoma in Saudi Arabia. J Trop Med Hyg 1987; 90: 51-59.
- Ahmed AO et al. Mycetoma caused by *Madurella mycetomatis*: a neglected infectious burden. Lancet Infect Dis. 2004 Sep; 4(9):566-74.
- Kaliswaran AV, Sentamilselvi G, Janaki C, Janaki VR (2003) Therapeutic response in mycetoma: A study of different regimes. Indian J Dermatol 48: 154-159.
- Ash, Spitz. Pathology of Tropical and Extraordinary diseases, Armed forces institute of pathology, Washington, D. C 1976; 2: 553-555.
- Arora B, Gupta S, Arora DR. Primary Mycetoma of the Patella. Indian Journal of orthopaedics 1979; Volume 13.Issue 1, Page: 84-86.
- Tilak R, Singh S, Garg A, Bassi J, Tilak V, Gulati AK. A case of Actinomycotic mycetoma involving the right foot. J Infect Dev Ctries. 2009 Feb 28; 3(1):71-3.
- Gupta S, Jain K, Parmar C, Shah P, Raval RC. Mycetoma: Nonvenereal perineallesions. Indian J Sex Transm Dis. 2010 Jan; 31(1):39-41.
- Papioannides D, Akritidis NK. Painless foot swelling with a chronic purulent discharge. West J. Med. 2001; 174: 96-97.
- Pulikot AM, Bappat SS, Tolat S. Mycetoma of the sole. Annals of Troughical Paediatrics 2002; 22: 187-190.
- McGinnis MR. Mycetoma.DermatolClin. 1996; 14: 97-104.

EQUIPMENT USED:

Nicon coolpix-8400.

X- Denotes the power of objective.

Stain used- Haematoxylin and eosin.

ORIGINAL ARTICLE

PLATE1:

MICROSCOPIC IMAGES OF MADURELLA GRISEA (CASE 1 & 2): Biopsy material shows fungal colonies within the micro abscesses. Organism identified is *Madurella grisea*. The periphery of the granules was dense with septate branched fungal filament with spherical chlamydospore as compared to the center. A very few septate filament were seen in the center almost had a hollow cylindrical appearance and identified histopathologically as *Madurella grisea* based on the description by Kwon-Chung and John E. Bennett 1992.

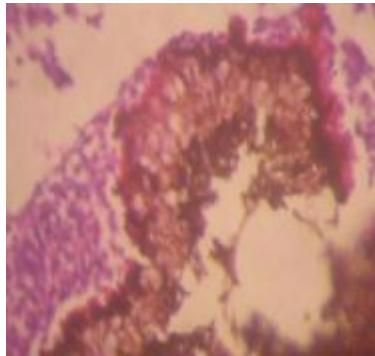


Fig.1a: H & E Stain-10X

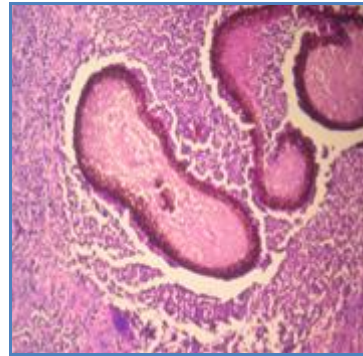


Fig.1b: H & E stain-40X

Periphery of the granule has a dense filaments of fungal hyphae with a hollow center having a few fungal hyphae with granuloma.

PLATE2:

Case 3: Madurellamycetomatis: H&E section revealed a brown, homogenous matrix of granules and septate branched fungal hyphae seen (fig). Fungal colonies are seen within the Microabscesses.

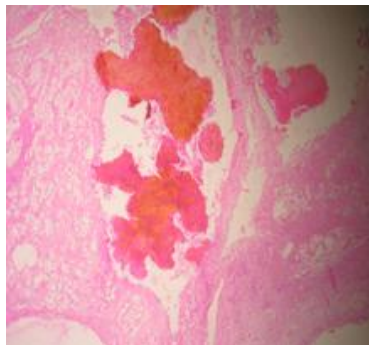


Fig.2: H & E Stain-4X

ORIGINAL ARTICLE

PLATE3:

Case 4: Nocardia Asteroids: Nocardia asteroides, the granules stains pale with Microabscesses and the grains were surrounded by inflammatory cells.

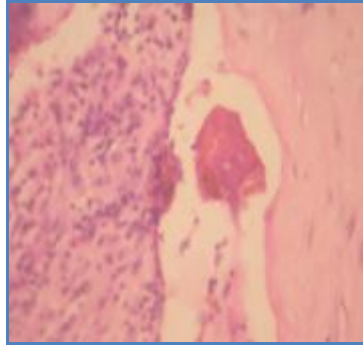


Fig. 3: H & E Stain- 40X

AUTHORS:

1. E. Shyamala
2. M. Valluvan
3. B. Divvy
4. V. Anandi
5. P. Viswanathan
6. Rehana Tippoo
7. B. Krishna Swamy
8. U. Manohar

PARTICULARS OF CONTRIBUTORS:

1. 2nd year Post Graduate, Department of Pathology, Rajah Muthiah Medical College, Annamalai University.
2. 2nd Year Post Graduate, Department of Pathology, Rajah Muthiah Medical College, Annamalai University.
3. 2nd Year Post Graduate, Department of Pathology, Rajah Muthiah Medical College, Annamalai University.
4. Professor, Department of Microbiology, Vinayaka Mission Medical College, Karaikal.
5. Professor and HOD, Department of Pathology, Rajah Muthiah Medical College, Annamalai University.

6. Professor, Department of Pathology, Rajah Muthiah Medical College, Annamalai University.
7. Professor, Department of Pathology, Rajah Muthiah Medical College, Annamalai University.
8. Professor, Department of Pathology, Rajah Muthiah Medical College, Annamalai University.

NAME ADDRESS EMAIL ID OF THE CORRESPONDING AUTHOR:

Dr. P. Viswanathan,
Professor and HOD,
Department of Pathology,
Faculty of Medicine,
Rajah Muthiah Medical College,
Annamalai University,
Annamalai Nagar-608002,
Tamilnadu, India.
Email: drpviswanathan2013@gmail.com

Date of Submission: 15/07/2014.

Date of Peer Review: 16/07/2014.

Date of Acceptance: 30/07/2014.

Date of Publishing: 07/08/2014.