

ROLE OF RADIO FREQUENCY IN THE MANAGEMENT OF INFERIOR TURBINATE HYPERTROPHYS. B. Amarnath¹, Arfin Aloor²**HOW TO CITE THIS ARTICLE:**

S. B. Amarnath, Arfin Aloor. "Role of Radio Frequency in the Management of Inferior Turbinate Hypertrophy". Journal of Evolution of Medical and Dental Sciences 2014; Vol. 3, Issue 57, October 30; Page: 12984-12988, DOI: 10.14260/jemds/2014/3723

ABSTRACT: BACKGROUND: Surgery of inferior turbinates is a divisive subject. Surgical management includes functional and invasive procedures. Radiofrequency ablation –A Minimally invasive well-designed daycare nasal surgery which also preserves mucosal function of the inferior turbinate. **OBJECTIVE:** To appraise the efficacy of radiofrequency in the management of inferior turbinate hypertrophy. **MATERIALS AND METHODS:** current study is a prospective cram conducted in the Department of ENT from August 2013 to August 2014 with 100 patients who had nasal obstruction due to Inferior turbinate hypertrophy and obstinate to medical therapy. Patients were excluded if they had history or physical examination that indicate other causes of nasal obstruction like nasal polyp, nasal tumors, previous nasal surgeries, diabetes mellitus, severe nasal deformities, coagulopathy disorders, severe systemic diseases, radiotherapy to nose. The study was based on history of diagnosis, clinical examination, diagnostic nasal endoscopy and imaging. We used radio frequency generator BM-780II unit with power of 70watt radio wave emission in bipolar mode for 5-9seconds, stopped the emission once visual blanching of mucous membrane occurred. Postoperative follow up scheduled as follows: 1stmonth, 3rdmonth, 6thmonth, 12thmonth. **RESULTS:** Among 100 patients 92 patients completely relieved of symptoms, 8 patients showed no improvement based on both subjective and objective parameters. **CONCLUSIONS:** Simple, harmless, minimally invasive, daycare procedure advantages made the Radiofrequency tissue ablation procedure as one amongst the best apt surgical option for management of inferior turbinate hypertrophy and the current study added credit to its efficiency once again.

KEYWORDS: Radiofrequency, nasal obstruction, inferior turbinate hypertrophy.

INTRODUCTION: Inferior turbinate hypertrophy is one of the commonest causes of nasal obstruction. Failure of medical treatment will route to various surgical techniques like partial or total turbinectomy, turbinoplasty, sub mucosal electrocautery, radiofrequency ablation, laser assisted resection / ablation and cryosurgeryetc.^(1,2,3) Radiofrequency ablation and microdebrider assisted turbinoplasty are functional procedures which conserves mucosal tissue. Goal of inferior turbinate surgery should aims to maximize volumetric reduction of turbinate with improvement in nasal obstruction and maintain nasal function with minimal complications.⁽¹⁾

Radiofrequency is a method which uses high frequency radio waves that heat the cells of turbinate and consequently causes coagulation necrosis. When thin needle terminals of bipolar probe are inserted into the sub-mucosal tissue which reduces vascular nervous tissue and consequently scar retracts resulting in reduction of volume of turbinate. This greatly limits the damage to superficial epithelium of turbinate.

ORIGINAL ARTICLE

MATERIALS AND METHODS: Present study is prospective interventional study performed on 100 patients presented to ENT department with nasal obstruction resulting from bilateral inferior turbinate hypertrophy with grades II or III (Friedman grading system 13) who are refractory to medical treatment in the form of anti histamines, steroid nasal spray for at least 12 weeks.

Patients were excluded if they had history or physical examination that indicate other causes of nasal obstruction like nasal polyp, nasal tumors, previous nasal surgeries, diabetes mellitus, severe nasal deformities, coagulopathy disorders, severe systemic diseases, radiotherapy to nose. The study was based on history of diagnosis, clinical examination, diagnostic nasal endoscopy and imaging. Inferior turbinate was graded by anterior rhinoscopy and nasal endoscopy according to the Friedman grading system (Table1).

Grade	Definition
GradeI	The turbinate was defined as mild enlargement with no obvious obstruction
GradeII	The turbinate was in between grade I and grade III
GradeIII	The turbinate completely occluded the nasal cavity

Table1: Friedman grading system of inferior turbinate hypertrophy

Source: Ref. 13.

The surgical intervention was performed in our department on an out-patient basis, after obtaining a written informed consent. The patients were operated under local anesthesia with 10% xylocaine spray and subsequent infiltration with 2ml of 4% xylocaine into the inferior turbinate. We used radio frequency generator BM-780II unit with bipolar terminals containing two parallel long needles with active tip.

The needles were placed parallel to the bone sub mucosally into the tissue of turbinate. We used a power of 70 watt radio wave emission in bipolar mode for 5-9 seconds, stopped the emission once visual blanching of mucous membrane occurred. Patient was discharged on the same day and advised to do alkaline saline douching for 2-3weeks. Postoperative follow up schedule as follows: 1stmonth, 3rdmonth, 6thmonth, 12thmonth.

RESULTS: All the patients presented with chronic nasal obstruction. Age of the patients varied from 12 years to 70 years. Out of 100 patients 55 were male and 45 were female. The cause for inferior turbinate hypertrophy was allergic rhinitis in 41patients, rhinitis medicamentosa in 22 patients, idiopathic rhinitis in 19 patients, chronic rhino sinusitis in 9 patients, and deviated nasal septum in 9 patients.

Cause	No. of patients
Allergic rhinitis	41
Rhinitis medicamentosa	22
Idiopathic rhinitis	19
Rhino sinusitis	9
DNS	9

Table 2: Various Causes of inferior turbinate hypertrophy observed in our study

ORIGINAL ARTICLE

Periodic follow up was done by the end of 1stmonth, 3rdmonth, 6thmonth and 12thmonth. Out of 100, 60 patients reported worsening of nasal patency during 1stweek of post-operative period due to edema and crusting of turbinate tissue, but the condition was improved within 3-4 weeks and it was confirmed by diagnostic nasal endoscopy as the mucosal normalization was observed.

The follow up was done up to one year, at the end of one year the nasal obstruction symptom was completely relieved in 92 patients and in 8 patients the symptom was not relieved. In the Objective parameters Diagnostic Nasal Endoscopy was taken into consideration and it came to normal in 92 patients and grade was significantly not reduced in remaining 8 patients. Epistaxis, Atrophy of turbinate, Nasal dryness, persistent crusting are the common complications mentioned after Radiofrequency ablation therapy but these were absolutely not occurred in our study.

Post-operative follow up	1 st month	3 rd month	6 th month	12 th month
No. of patients relieved Of Nasal obstruction	92	92	92	92
No. of patients not relieved Of Nasal obstruction	8	8	8	8

Table 3: Post-operative follow up results

DISCUSSION: Inferior turbinate hypertrophy is the commonest cause for chronic nasal obstruction.⁽⁴⁾ The surgical management of enlarged inferior turbinates has been debated for more than 100 years. Various techniques are currently performed to reduce the volume of inferior turbinate, which indicates there is lack of consensus regarding the optimal surgical technique. An ideal turbinate reduction procedure should preserve the physiological function of turbinate such as regulation of humidification and temperature of inspired air.

Radiofrequency causes a reduction in sub mucosal tissue volume using ablation by high frequency current. This technique is based on local sub mucosal delivery of energy by means of a specifically adapted electrode. This energy induces ion agitation within the tissue, which increases the local temperature and causes a thermal lesion without damaging the surface mucosa. Healing of mucosa, apparently preserving the nasal mucociliary function.⁽⁵⁾

There are many studies which demonstrated the effectiveness of radiofrequency in reducing the nasal obstruction in patients with inferior turbinate hypertrophy.^(6,7,8,12) In first 2 -3 days following surgery, nasal obstruction worsened in most of the patients due to postoperative edema and crusting.⁽⁵⁾ By the end of 4th week there is significant improvement in nasal obstruction. Cavaliere et al.⁽⁹⁾ and Cingi et al.⁽¹⁰⁾ mentioned that significant improvement in nasal obstruction occurred at one month after treatment which correlates with our present study. Apart from nasal obstruction we also noticed that severity of other symptoms like nasal itching, excessive sneezing, rhinorrhoea, headache, snoring, sense of smell are improved to certain extent as mentioned in other studies.^(5,10,11)

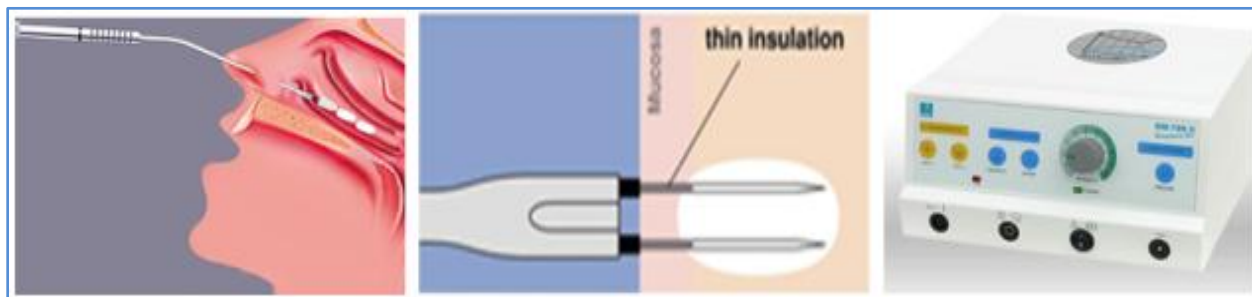
CONCLUSION: our one year experience of surgical management of the inferior turbinate with radio frequency enables us to state that in our opinion the procedure is relatively simple, fast-it lasts for a few minutes, practically no intra and post-operative complications, well tolerated by the patient, carried out as a day care surgery with satisfactory results.

REFERENCES:

1. Akdaga M, Dasdagb S, Ozkurta F E, Celikc M Y, Degirmencid A, Demird H & Merica F. Long-term effect of radiofrequency turbinoplasty in nasal obstruction. *Biotechnology & Biotechnological Equipment*, 28: 2,285-294.
2. Salzano FA, Mora R, Dellepiane M, ZannisI, SalzanoG, Moran E, Salami A. Radiofrequency, highfrequency, and electrocautery treatments vs partial inferior turbinotomy: Microscopic and macroscopic effects on nasalmucosa. *ARCH OTOLARYNGOL HEAD NECK SURG.* 2009Aug; 135(8): 752-8.
3. Bhandarkar ND, Smith TL. Outcomes of surgery for inferior turbinate hypertrophy. *Curropin otolaryngol headneck surg.* 2010; 18: 49-53.
4. Passali D, passali FM, Damiani V, etal. Treatment of Inferior Turbinate Hypertrophy: A Randomized Clinical Trail. *Ann Otol Rhinol Laryngol* 2003; 112 (8): 683-8.
5. Parida P K, Santosh K, Ganesan S, Surianarayanan G, Saxena S K. The efficacy of radiofrequency volumetric tissue reduction of hypertrophied inferior turbinate in allergic rhinitis. *Indian journal of medical sciences.* July2011; 65: 269-77.
6. Special R, Rustivo S, Gallina S, Cupido G, Giammanco AM. Surgery of the inferior turbinates by radiofrequency. *Otorhinolaryngologia*2000; 50: 95-8.
7. Coste A, Yona L, Blumen M, Louis B, Zerah F, Rugina Metal. Radiofrequency is a safe and effective treatment of turbinate hypertrophy. *Laryngoscope*2001; 111: 894-9.
8. Nease CJ, krempl GA. Radiofrequency treatment of turbinate hypertrophy: a randomized, blinded, placebo-controlled clinical trail. *Otolaryngol head neck surg* 2004; 130: 291-9.
9. Cavaliere M, mottola G, lemmaM, comparison of the effectiveness and safety of radiofrequency turbinoplasty and traditional surgical technique in treatment of inferior turbinate hypertrophy. *Otolaryngolheadnecksurg*2005; 133: 972-8.
10. Cingi C, ure B, Cakli H, Ozudogru E. Microdebrider assisted versus radiofrequency assisted inferior turbinoplasty: A prospective study with objective and subjective outcome measures. *Actaotolaryngolital*2010; 30: 138-43.
11. Paraya Assanasen, M. D., Panyalak Choochurn, M. D., Wish Banhiran, M. D., and ChaweewanBunnag, M. D. Radiofrequency inferior turbinate reduction improves smell ability of patients with chronic rhinitis and inferior turbinate hypertrophy. *Allergyrhinol*2014;5:e12-16.
12. Batra PS, Seiden AM, Smith TL. Surgical management of adult inferior turbinate hypertrophy: A systematic review of the evidence. *LARYNGOSCOPE.*2009sep; 119 (9):1819-27.
13. Friedman M, Tanyeri H, LimJ, etal. A safe, alternative technique for inferior turbinate reduction. *Laryngoscope*109:1834–1837, 1999.

ORIGINAL ARTICLE

Image showing the radiofrequency generator BM-780 II unit and the way of application of bipolar electrode in the volumetric reduction of the Inferior Turbinates.



AUTHORS:

1. S. B. Amarnath
2. Arfin Aloor

PARTICULARS OF CONTRIBUTORS:

1. Assistant Professor, Department of ENT Head & Neck, Narayana Medical College.
2. Ayurvedic Practitioner, MS Shalya.

NAME ADDRESS EMAIL ID OF THE CORRESPONDING AUTHOR:

Dr. S. B. Amarnath,
C/o Dr. B. Vijayalakshmi,
Das, APVVP,
Area Hospital Staff Quarters,
Rayachoty, Kadapa Dist,
Andhra Pradesh 516269.
Email: doc_amarnath@yahoo.co.in

Date of Submission: 15/10/2014.
Date of Peer Review: 16/10/2014.
Date of Acceptance: 27/10/2014.
Date of Publishing: 29/10/2014.