

**CORNEAL HAZE FOLLOWING PHOTO REFRACTIVE KERATECTOMY**Atul Gupta<sup>1</sup>, Superna Mahendra<sup>2</sup>, Pervaiz Hussian<sup>3</sup>**HOW TO CITE THIS ARTICLE:**

Atul Gupta, Superna Mahendra, Pervaiz Hussian. "Corneal Haze following Photo Refractive Keratectomy". Journal of Evolution of Medical and Dental Sciences 2015; Vol. 4, Issue 15, February 19; Page: 2568-2576, DOI: 10.14260/jemds/2015/369

**ABSTRACT:** To assess the incidence of corneal haze following surface ablation in (PRK) in high myopic patients ( $\geq 6D$ ). **METHODS:** In this prospective clinical study, 25 patients with high myopia ( $\geq 6D$ ) that is 50 eyes in total, underwent photorefractive keratectomy by Schwind Amaris 500E laser machine. At the initial presentation, each patient underwent a detailed clinical evaluation that included recording of medical history, detailed ocular history, Snellen visual acuity testing, and thorough anterior segment by slit-lamp bio-microscopy and posterior segment examination with indirect ophthalmoscopy were done. Corneal topography and pachymetry were also done. The patient is followed up at 1 week to observe for re-epithelialization and then at 1, 3 and 6 months for observation of haze under slit-lamp examination. **RESULTS:** In our study of 25 patients, that is 50 eyes in total were divided into 3 groups depending upon the spherical equivalence. Group 1 between 6.00-7.00D, group 2 between 7.00-8.00D, and in group 3 more than 8D ( $\geq 8.00D$ ). Over 6 months period of follow up a significant haze was noted as the patient's refractive error increased. Out of 50 eyes, 11 eyes (84.6%) with spherical equivalence of 6.00-7.00D (group 1) had grade 0, 8 eyes (66.6%) with spherical equivalence of 7.00-8.00D (group 2) had grade 0, and 6 eyes (24%) with spherical equivalence  $\geq 8.00D$  (group 3) had grade 0. Thus, the results show that there has been a significant decrease in the eyes with no corneal haze as the refractive error increased. Eyes with grade 1 haze in group 1 were 2 (15.3%), group 2 were 3 (25%), and group 3 were 7 (28%). These results showed that the incidence of grade 1 haze increased with increase in spherical equivalence. Eyes with grade 2 haze in group 1 were 0 (0%), group 2 were 1 (8.3%), group 3 were 10 (40%). Thus, it is seen that grade 2 haze was not noted in eyes with spherical equivalence between 6.00-7.00D, but were noted with increase in the refractive error. Eyes with grade 3 haze in group 1 and 2 were 0, and group 3 were 2 (8%). Thus, the results show that as the refractive error of increases the incidence of haze and the degree of haze increases. The p value  $< 0.001$ , was statistically highly significant supporting that the incidence of haze increased with increase in the refractive error. The mean pre-operative visual acuity was (6/9) that is 0.2 log MAR value and mean post-operative visual acuity was (6/12) that is 0.3 log MAR value. The p value was  $< 0.001$  which is statistically highly significant. Thus, concluding that there was a significant drop in post-operative visual acuity in high myopic patients ( $\geq 6D$ ) following PRK. **CONCLUSIONS:** 1. From the above study it is concluded that post photorefractive keratectomy (PRK) as the refractive error increases, the incidence of haze increases in high myopic patients ( $> 6D$ ), thus compromising the post-operative visual acuity. 2. With the use of intra-operative 0.02% Mitomycin-C (MMC) and post-operative topical corticosteroids, thus modifying the healing process and decreasing the incidence of haze in high myopic patients. 3. Thus, concluding that PRK can be an effective procedure in treating high myopic patient.

**KEYWORDS:** Spherical Equivalent, photorefractive keratectomy, corneal haze, wound healing process in high myopic eyes, excimer laser, mitomycin-C, topical corticosteroids.

## ORIGINAL ARTICLE

---

**INTRODUCTION:** Myopia is a type of refractive error in which parallel rays of light coming from infinity are focussed in front of retina with accommodation at rest. Simple myopia is the most common variant with a good prognosis. It is graded as low myopia (<2D), moderate myopia (2-6 D), and high myopia (>6D). Surgical correction of myopia has become quite popular now a days. Several Kerato-refractive surgical procedures<sup>1-4</sup> have been developed to permanently alter the curvature of cornea thereby reducing refractive error.<sup>5-6</sup> The procedures most commonly performed today use 193 nm Argon – Fluoride Excimer Laser present in UV 8-11 range is used in surface ablation, that is Photo refractive keratectomy (PRK), Laser assisted sub epithelial keratectomy (LASEK) and also in Laser in situ keratomileusis (LASIK). The Excimer Laser reshapes the curvature and contour of anterior corneal surface by removing anterior corneal stroma in a microscopically precise process known as ablative photo decompensation. This results in non-thermal photo chemical breakage of carbon- carbon covalent molecular bonds in corneal tissue. Photo refractive keratectomy is the only procedure that with proper healing one cannot tell that a refractive procedure has occurred eve with slit lamp examination.<sup>7</sup>

**MATERIALS AND METHOD:** This a prospective observational study conducted on 25 patients that is 50 eyes in total who underwent PRK from December 2012 – July 2014 at Nanovision Laser eye centre at Hyderabad. Inclusion criteria for patients was more than > 6 D of myopia, more than 18 years of age and healthy eyes with no disease or abnormality. Patients who had less than 6D of myopia, corneal scars, dry eyes pre-existing scars uncontrolled Diabetes Mellitus and Collagen vascular diseases were excluded. In this prospective study, 25 patients with high myopia (>6D) that is 50 eyes in total, underwent Photo refractive keratectomy by Schwind Amaris 500 E Laser machine. At the initial presentation, each patient underwent a detailed clinical evaluation that included recording of medical history, detailed ocular history, Snellens visual acuity, refraction dry and cycloplegic by two observers and thorough slit lamp examination. Corneal topography and pachymetry was also done for all patients. Procedure is done after instillation of topical anaesthetic and antibiotic drops. Lid speculum is applied and the patient is asked to fixate on light which is coaxial with the incoming laser beam. The patient is explained about the snapping sounds and effluent smell that he or she might experience during procedure.

The surgeon uses an optical zone marker 1 mm larger (approximately 7mm in diameter to accommodate a 6mm laser optical zone) than the desired optical PRK zone. The epithelium removal and stromal ablation were done using Excimer laser (Trans epithelial PRK). The patients were advised to use topical antibiotics and steroids post operatively to prevent risk of infection and haze formation respectively. The patients were also advised to use oral or topical NSAIDS to alleviate post-operative pain. The patients were followed up at 1 week to observe for re – epithelisation and then at 1, 3, and 6 months for observation of haze under slit lamp examination. Visual acuity was also recorded with Snellen's chart with each follow up. The eyes which developed haze were collected by slit lamp photography. The Excimer laser which has scanning laser beams has become the most refractive surgeries. It is the contraction of 2 words "excited dimer".

It overcomes the intermolecular bond C-C and peptide bond at corneal surface, this allows accurate layer by layer removal of tissue at molecular level. The penetration depth of each pulse laser is also minimal thus minimising tissue damage. Vision is initially blurry after surgery but starts to improve once the surface epithelium grows back which usually takes 3-5 days. Stable vision is usually

achieved within 1-3 months. Durrie et al 1 have described three wound healing types which can be helpful in following the PRK patients post-operatively. Type 1 healers comprise the majority of patients, following the trace to mild haze formation that begins at 1 month, peaks at 3-6 months and gradually dissipates. Type 2 healers are known as under healers, and clear corneas to trace haze is often seen during 3-6 month period. These patients are at a risk for overcorrection. Type 3 healers are the more aggressive healers, who are at the risk for moderate to severe haze formation.

**Major histo-pathologic findings following PRK are:**

**Epithelial Resurfacing:** It's a rapid process requiring migration of the epithelium to resurface the cornea over the first 2-7 days, depending on the size.

Re-establishment of corneal epithelial surface, however, requires formation of both a new epithelial basement membrane and reformation of epithelial hemi-desmosomes. Failure to re-establish a normal epithelial basement membrane to promote firm epithelial re-attachment through specific basement membrane matrix attachment components contributes to epithelial breakdown, which may occur in as many as 3% of eyes after PRK.

More recent studies suggest that the incidents of clinically detectable epithelial breakdown is rare, but patient satisfaction studies suggest that almost 50% of PRK patients have symptoms of dryness and foreign body sensation and 20% have intermittent eye and lid pain suggestive of sub-clinical corneal erosions.

In addition to photo-ablation of epithelial basement membrane, most clinically relevant refractive corrections also remove the underlying Bowman's layer. This acellular, fibrotic collagen layer does not regenerate once ablated. The exact physiologic role of Bowman's layer is thought to provide an important contribution to the biomechanical stability of the cornea.

An alternate function of Bowman's is separation of corneal epithelium from the underlying stromal keratocytes. The interaction between these types of cells plays a critical role in maintenance of normal corneal function through release of cytokines and other growth factors that act in paracrine or autocrine fashion.

As Bowman's layer acts as both physical barrier and a biochemical filter to the cytokine-dependent cross-talk between epithelial cells and keratocytes, the loss of this region after PRK may impact significantly on the re-establishment of appropriate levels of these factors necessary to regain normal corneal function.

**Keratocyte Apoptosis:** Histologic studies of primate corneas have shown that immediately after surgery there is marked reduction in the number of keratocytes in the anterior 40 microns of the stroma, suggesting keratocyte cell death.

Keratocyte death may be attributed to thermal or mechanical damage since photo-ablation increases the local corneal temperature by 10-20 degree Celsius and generates an acoustic shock wave of about 80 atm.

However, death of stromal Keratocytes can also be induced by epithelial scrape injury, first recognized biochemically by Hermann and LeBeau in 1962 and later histologically verified by Dohlman in 1968. Apoptosis is thought to be mediated by injury to the Keratocytes or induced by cytokines released from the damaged epithelium, particularly interleukin-1alpha or FAS ligand.

## ORIGINAL ARTICLE

---

Some investigators suggest that activation of stromal cells and the development of stromal fibrosis may be initiated by keratocyte apoptosis and that effective management of corneal scarring may involve modulation of the apoptotic response. In support of this approach is the observation that LASIK surgery produces markedly less apoptosis than PRK and does not generally develop haze or wound fibrosis.

**Stromal Repair:** Based on general studies of corneal wound healing it is presumed that, after PRK, stromal cells become activated and then proliferate and migrate towards the wound during the first week after injury. At 7 days there is an increase in the number of keratocytes adjacent to the wound, and the number dramatically increases over the next 3 weeks.

It is at this phase of wound healing response that the greatest degree of clinically observable corneal haze is detected suggesting association with either the dramatic increase in the number of fibroblastic cells or the deposition of new extracellular matrix. In most patients the level of stromal opacity is not clinically significant, but in some, especially with higher levels of correction, the opacity can be severe.

Sub-epithelial corneal haze typically appears several weeks after surface ablation, peaks in intensity at 1–2 months, and gradually diminishes or disappears over the following 6–12 months. Late-onset corneal haze may occur several months or even a year or more postoperatively after a period in which the patient had a relatively clear cornea.

According to subjective measurement criteria of Seiler and Fantes, corneal haze can be graded as:

Grade 0	Clear cornea.
Grade 0.5	Barely detectable or trace haze.
Grade 1.0	Mild haze with normal vision.
Grade 2.0	Moderate haze that interferes with refraction.
Grade 3.0	Marked haze that obscures iris.
Grade 4.0	Severe haze.

Up to mild grade corneal haze is clinically insignificant and most of the times not associated with symptoms. Haze more than grade 2 is referred to as a scar.

### **Other complications following PRK include:**

- Decentration of ablation zone due to poor alignment with the patient fixation or due to eye movements during the surgery.
- Night glare and halos seen with ablation zone of 3.5 mm.
- Delayed epithelial healing due to keratoconjunctivitis sicca, topical anti-inflammatory drugs, and prophylactic antibiotic therapy.
- Recurrent corneal erosions, corneal infiltration and ulceration.
- Decreased corneal sensations in patients with high myopia who undergo larger and deeper ablation.
- Central islands occur due to shock wave formation and ejection of a plume of gaseous and particulate debris which interfere with the subsequent delivery of the laser.
- Sub retinal hemorrhages occur due to the mechanical stress waves which might cause disruption of fragile sub retinal vessels.

## ORIGINAL ARTICLE

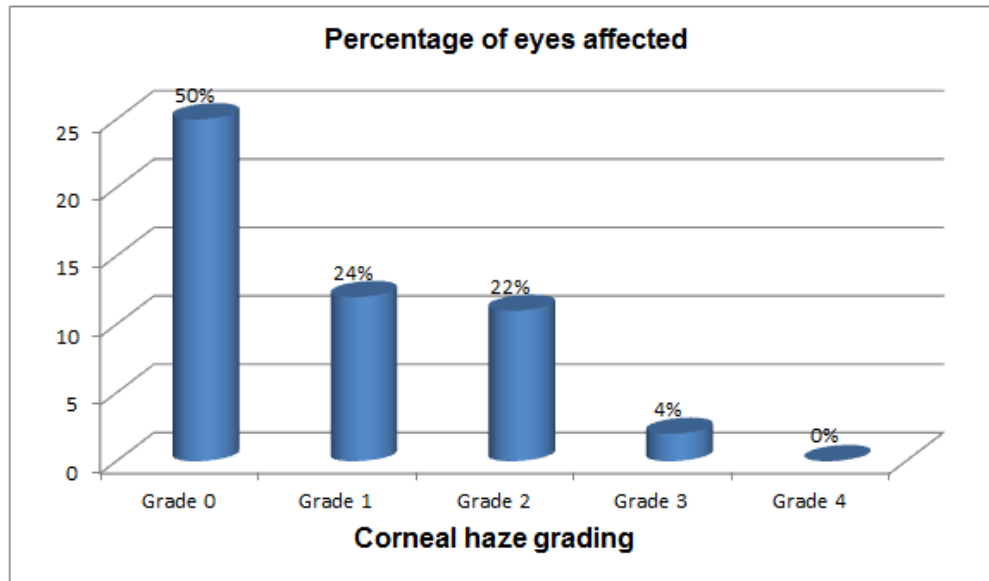
- Under-correction or over-correction- If the desired correction is not achieved, glasses may still be necessary for good vision. In some, but not all cases, significant under-corrections or over-corrections can be retreated.
- Raised IOP is thought to be a result of topical use of postoperative corticosteroids.

### OBSERVATION AND STATISTICS:

**Age Distribution:** Majority, that is 10 of the cases belong to age group of 19-22 (40%), 10 patients were present in the age group of 23-26 (40%), and 5 patients in 27-30 years.

**Gender Distribution:** Among the 25 patients 10 (40%) were males and 15 (60%) were females.

**Number of Eyes affected according to the corneal haze Grading:** Out of 25 patients who were operated for both eyes, that is 50 eyes in total. Of these 25 eyes developed no haze (50%), 12 eyes had grade 1 (24%), 11 eyes had grade 2 (22%), 2 eyes were found to have grade 3 (4%) and grade 4 was not found in any of the patient (0%).



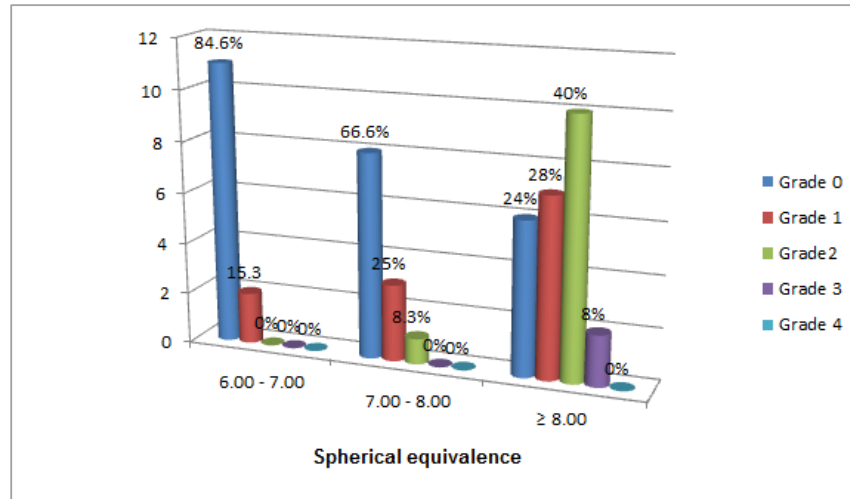
**Graph 1: Percentage of haze distribution**

Corneal haze	Number of eyes affected	Percentage of eyes affected
Grade 0	25	50%
Grade 1	12	24%
Grade 2	11	22%
Grade 3	2	4%
Grade 4	0	0%

**Table 1: Percentage of haze distribution**

## ORIGINAL ARTICLE

### Haze grading and the number of eyes affected according to the spherical equivalence.



**Graph 2: Percentage of haze distribution**

Corneal haze grading	Spherical equivalence 6.00-7.00	Spherical equivalence 7.00-8.00	Spherical equivalence ≥ 8.00
Grade 0	11 eyes (84.6%)	8 eyes (66.6%)	6 eyes (24%)
Grade 1	2 eyes (15.3%)	3 eyes (25%)	7 eyes (28%)
Grade 2	0 (0%)	1 eye (8.3%)	10 eyes (40%)
Grade 3	0 (0%)	0 (0%)	2 eyes (8%)
Grade 4	0 (0%)	0 (0%)	0 (0%)

**Table 2: Percentage of haze distribution**

**DISCUSSION:** The excimer laser has developed rapidly from the laboratory to its current clinical use for refractive surgery, in a procedure known as photorefractive keratectomy (PRK). The excimer laser is able to meticulously sculpt the corneal surface, altering the surface optical architecture to correct refractive errors.<sup>8</sup> Such surgery is achieved with minimal mechanical and thermal effects upon the remaining corneal tissue.

Pre-operative preparation is of paramount importance to the outcome of PRK. Computer controlled application of laser energy removes a corneal tissue to achieve the desired refractive correction. The advantage of this procedure is that it is flap free unlike LASIK where flap related complications occur.<sup>9</sup> In PRK only the epithelium is removed and laser is applied to reshape the corneal surface, thus correcting the refractive error. Results to date have been encouraging.

The complication of concern in PRK is post-operative haze which usually develops at 1m and peaks at 2-3 months, especially those with refractive error of more than 6D. This is due to the stromal wound healing process which may result in a fine stromal haze or significant scarring in rare cases.

## ORIGINAL ARTICLE

---

In our study of 25 patients, that is 50 eyes in total were divided into 3 groups depending upon the spherical equivalence. Group 1 between 6.00-7.00D, group 2 between 7.00-8.00D, and in group 3 more than 8D ( $\geq 8.00D$ ).

Over 6 months period of follow up a significant haze was noted as the patient's refractive error increased. Out of 50 eyes, 11 eyes (84.6%) with spherical equivalence of 6.00-7.00D (group 1) had grade 0, 8 eyes (66.6%) with spherical equivalence of 7.00-8.00D (group 2) had grade 0, and 6 eyes (24%) with spherical equivalence  $\geq 8.00D$  (group 3) had grade 0. Thus, the results show that there has been a significant decrease in the eyes with no corneal haze as the refractive error increased. Eyes with grade 1 haze in group 1 were 2 (15.3%), group 2 were 3 (25%), and group 3 were 7 (28%). These results showed that the incidence of grade 1 haze increased with increase in spherical equivalence.

Eyes with grade 2 haze in group 1 were 0 (0%), group 2 were 1 (8.3%), group 3 were 10 (40%). Thus, it is seen that grade 2 haze was not noted in eyes with spherical equivalence between 6.00-7.00D, but were noted with increase in the refractive error.

Eyes with grade 3 haze in group 1 and 2 were 0, and group 3 were 2 (8%). Thus, the results show that as the refractive error of increases the incidence of haze and the degree of haze increases. The p value  $< 0.001$ , was statistically highly significant supporting that the incidence of haze increased with increase in the refractive error.

The mean pre-operative visual acuity was (6/9) that is 0.2 log MAR value and mean post-operative visual acuity was (6/12) that is 0.3 log MAR value. The p value was  $< 0.001$  which is statistically highly significant. Thus, concluding that there was a significant drop in post-operative visual acuity in high myopic patients ( $\geq 6D$ ) following PRK.

### CONCLUSIONS AND SUMMARY:

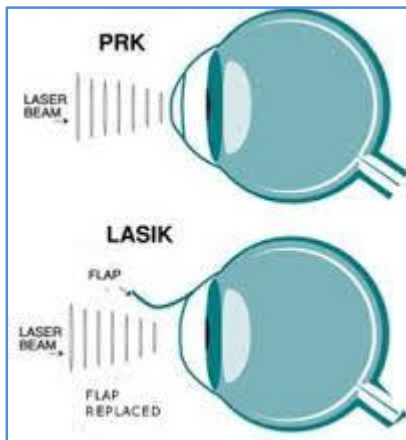
- From the above study it is concluded that post photorefractive keratectomy (PRK) as the refractive error increases, the incidence of haze increases in high myopic patients ( $> 6D$ ), thus compromising the post-operative visual acuity.
- With the use of intra-operative 0.02% Mitomycin-C (MMC) and post-operative topical corticosteroids, thus modifying the healing process and decreasing the incidence of haze in high myopic patients.<sup>10</sup>
- Thus, concluding that PRK can be an effective procedure in treating high myopic patients as one does not have the risk of flap creation and because of the accuracy of its correction when proper patient selection, surgical technique and quality of post-operative care occur.

### REFERENCES:

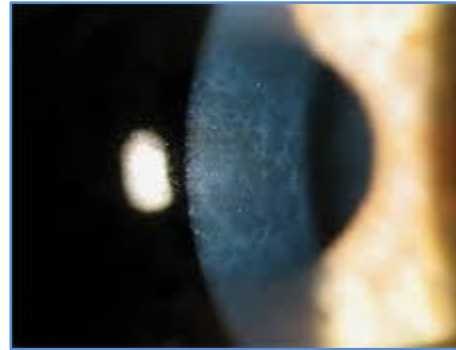1. Durries Ds, Leshner MP, Cavanaugh T>B> classification of variable response after photo refractive keratectomy for myopia, *Refractive surgery* 1995; 11: 341-347.
2. Koren G, Yeh JT Emission spectra, surface quality, and mechanism of excimer laser radiation. *Appl Phys Lett* 1984; 44: 1112-1118.
3. Srinivasan R, Leigh WJ. Ablative photodecomposition on polyethylene terephthalate films. *J Am Chem Soc* 1982; 104: 6784-6788.
4. Srinivasan R, Mayyne-Bayton V Self-developing photo-etching of poly (Ethylene terephthalate) films by far ultraviolet excimer laser radiation. *Appl Phys Lett* 1983; 41: 576-578.

## ORIGINAL ARTICLE

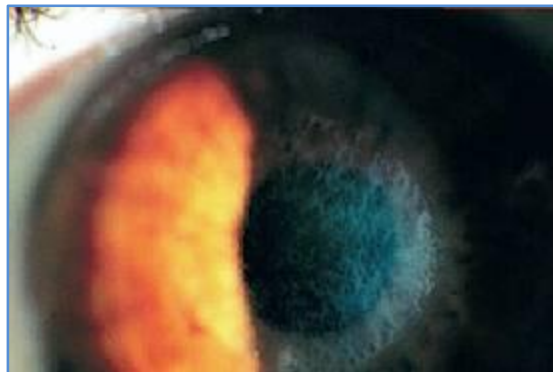
5. Trokel SL, Srinivasan R, Baren B. Excimer laser surgery of the cornea. *Am J Ophthalmol* 1983; 96:710-715.
6. U.S. Food and Drug Administration, Department of Health and Human Services, health Cfdar. LASIK. 2008.
7. Weiss JS. Basic and Clinical Science Course (BCSC): Refractive Surgery. San Francisco: American Academy of Ophthalmology, 2006.
8. Ewing JJ. In *Laser Pioneer Interviews*, 1st ed. Torrance, CA: High Tech Publications; 1985 243-256.
9. Trokel SL. Evolution of excimer laser corneal surgery. *J Cataract refract surg* 1989; 15:373-383.
10. Velasco JE, Setser DW. Bound-free spectra of diatomic xenon halides. *J Chem Phys* 1975; 621: 990-991.



**Fig. 1**



**Fig. 2**



**Fig. 3**



## ORIGINAL ARTICLE

---

### **AUTHORS:**

1. Atul Gupta
2. Superna Mahendra
3. Pervaiz Hussian

### **PARTICULARS OF CONTRIBUTORS:**

1. Assistant Professor, Department of Ophthalmology, Osmania Medical College, Hyderabad.
2. Assistant Professor, Department of Ophthalmology, Osmania Medical College, Hyderabad.
3. Assistant Professor, Department of Ophthalmology, Osmania Medical College, Hyderabad.

### **FINANCIAL OR OTHER**

**COMPETING INTERESTS:** None

### **NAME ADDRESS EMAIL ID OF THE CORRESPONDING AUTHOR:**

Dr. Atul Gupta,  
H. No. 564, Rd. No. 12,  
Banjara Hills,  
Hyderabad-34.  
E-mail: dratulguptaeye@gmail.com

Date of Submission: 22/12/2014.  
Date of Peer Review: 23/12/2014.  
Date of Acceptance: 11/02/2015.  
Date of Publishing: 18/02/2015.