

ROLE OF ADENOIDECTOMY IN THE MANAGEMENT OF OTITIS MEDIA WITH EFFUSION

Avinash Kumar¹, Rupanjita Sangma²

HOW TO CITE THIS ARTICLE:

Avinash Kumar, Rupanjita Sangma. "Role of Adenoideotomy in the Management of Otitis Media with Effusion". Journal of Evolution of Medical and Dental Sciences 2014; Vol. 3, Issue 24, June 16; Page: 6752-6761, DOI: 10.14260/jemds/2014/2815

ABSTRACT: OBJECTIVE: To study the role of adenoideotomy in the management of otitis media with effusion. **TYPE OF STUDY:** A prospective clinical study. **MATERIALS AND METHODS:** 20 cases studied in department of ENT, GMCH. The duration of study was from February 2011 to December 2011. Hearing loss assessment in the form of PTA & TYMPANOMETRY before and after adenoideotomy was done. **OBSERVATIONS AND RESULTS:** Children <14 years were included in the study. Sex wise distribution was observed. Patients categorized according to the symptoms, gender and degree of hearing loss. Satisfactory results observed after adenoideotomy in relation to the improvement in hearing loss. There can be some complications after adenoideotomy but in our studies proper precautions were taken and no complications seen. **CONCLUSION:** Adenoideotomy is a very effective surgical modality of treatment in patients who are having otitis media with effusion due to adenoid hypertrophy. Conservative management has no role and grommet insertion is not of much value. Adenoideotomy alone has been shown to produce otoscopic clearance of middle ear effusion, alteration of tympanometric status and improvement of hearing loss.

KEYWORDS: Hearing loss, audiometry, tympanometry, myringotomy, spontaneous resolution.

INTRODUCTION:

OTITIS MEDIA WITH EFFUSION [OME]: Is the chronic accumulation of mucus within the middle ear and sometimes the mastoid air cell system. The time that the fluid has to be present for the condition to be chronic is usually taken as 12 weeks. In many children OME is usually preceded by an episode of acute otitis media with otalgia and fever particularly so in younger children because of their greater propensity to upper respiratory tract infections. This damages the Eustachian tube epithelium with resultant retention of middle ear fluid.

AETIOPATHOLOGY & CAUSATION: The ciliated, pseudo-stratified columnar epithelium of respiratory tract extends up the Eustachian tube as far as anterior part of middle ear cavity. These cells are capable of producing mucus. In addition there are goblet cells and mucus secreting glands. OME is primarily caused by inflammation of this epithelium in the Eustachian tube and hypotympanum.

Wide variety of risk factors, indicate that there is no single cause for glue ear. However in approximately one half of cases, there appear to be an initial upper respiratory tract infection of viral origin. Secondary bacterial colonization of middle ear cleft occurs possibly in relation to nasopharyngeal infection. Long standing inflammation results in a proliferation of goblet cells and formation of mucus glands and mucus cysts.

The metaplastic changes that bring about an increase in mucus secretion may result in entire middle ear being filled with mucus and large amounts of mucus are not cleared swiftly from middle

ear by ciliary action. This failure to clear mucus could be secondary to an obstruction of Eustachian tube opening by large adenoids. Since large adenoids are frequently found in children with chronic secretory otitis media and their removal seemed to help the resolution of the condition, this seemed logical.

EX VACUO: Ex Vacuo theory implicates tubal obstruction and dysfunction as a principal primary cause for chronic secretory otitis media. Tubal component is likely to be involved and this is supported by the universality of chronic secretory otitis media in children with a cleft palate. There is increasing evidence of involvement of nasopharyngeal component. The adenoid tissue and other lymphoid tissue in upper airway may act as a source of infection but factors in nasopharynx, including pressure change and partial pressure of carbon dioxide may be linked with tubal dysfunction.

SNIFF THEORY: Sniff Theory would explain the role of enlarged adenoids in the causation of secretory otitis media. As the volume of nasopharynx decreases with increasing adenoid size, airflow speeds up during inspiration, thus the Eustachian tube which lies obliquely to the direction of airflow, is exposed to a greater negative pressure in children with enlarged adenoids than in those with small ones.

EUSTACHIAN TUBE DYSFUNCTION: Inevitably if the epithelium of the Eustachian tube is inflamed, becomes oedematous and loses its cilia, then it will dysfunction as an aerator of the middle ear. Viral upper respiratory tract infections and smoking are common causes of damage to the Eustachian tube epithelium. It may be secondary to chronic nasopharyngeal infection in the adenoidal tissue or gastroesophageal reflux.

DIAGNOSIS AND SCREENING: Involves assessment of hearing, aspects of cochlear function. Otoscopy is required visually to confirm the presence of an effusion. Pneumatic otoscopy is performed, preferably using an instrument with halogen light source. Examination under microscope with magnification may further improve diagnostic accuracy.

Tympanometry provides an objective assessment of middle ear status. Tympanometry is unreliable in children under 6 months old. The reliability improves with age. Type B traces are highly sensitive in detecting effusions with greater than 25 dB hearing loss but are only 75 % specific. Myringotomy and aspiration of middle ear fluid is the gold standard for diagnosis of chronic secretory otitis media. Audiometry is not of diagnostic value but allows assessment of severity of the condition and may be used to monitor progress.

TREATMENT: Any treatment regimen needs to take note not only of severity of disease but also of persistence of constant or intermittent disease, and whether the condition is symptomatic. Such symptoms may concern hearing loss or its secondary effects on speech, language, cognition and behavior or they may be a consequence of secondary infection within the middle ear.

Spontaneous resolution of severe persistent chronic secretory otitis media occurs in 95% of patients by the age of 10 years.

ORIGINAL ARTICLE

Treatment should aim to relieve the symptoms caused by middle ear condition. It should resolve the underlying pathophysiological changes and it should prevent recurrence and development of sequelae. There may also be a need to treat co-existent conditions such as infection in nose, sinuses and allergy.

MEDICAL TREATMENT: Decongestants and mucolytics are not very helpful. Antibiotics of penicillin group and cephalosporins are very commonly used. Steroid treatment alone offers a short term cure rate of 18–21%. Steroid treatment with antibiotics has shown a cure rate of 25–31%. Non-steroidal anti-inflammatory drugs have no long term benefits. Auto-inflation has a short term benefit for up to 3 months with a 2 to 5 fold improvement in otoscopic and tympanometric outcome.

SURGICAL TREATMENT: Myringotomy and ventilation tubes – myringotomy alone with aspiration of middle ear effusion has only a short lived beneficial effect. It's not recommended for persistent effusions. There seems to be a need for retreatment with tubes in approximately 30 % of patients. Acceptable indications would be persistence of bilateral chronic secretory otitis media confirmed by tympanometry showing type B or C2 curve rather than A or C1 curve. Tube insertion does not prevent development of attic retraction, outer attic wall erosion or atelectasis.

Adenoidectomy – alone has been shown to produce otoscopic clearance of middle ear effusion, alteration of tympanometric status and improvement of hearing loss.

There may be significant complications like reactionary and secondary hemorrhage. velopharyngeal insufficiency may also develop but these can be avoided if proper precautions are taken.

SEQUELAE OF GLUE EAR: Can be structural in middle or inner ear, or functional due to hearing loss.

STRUCTURAL: In middle ear there can be tympanic membrane scarring, segmental atrophy, tympanosclerosis or perforation. Atelectasis may also develop. There is possibility of cholesteatoma formation as well. Very severe myringosclerosis may occur with fixation of malleus handle and in these few patients, hearing loss may be greater. Atelectasis may lead to myringo-incudostapedopexy, erosion of long process of incus and significant conductive hearing loss.

In inner ear recent studies have shown ultra high frequency hearing loss with glue ear. Inflammatory mediators and neurotoxins have been found in middle ear effusions.

FUNCTIONAL: Long standing effects of hearing loss associated with middle ear effusions may impair subsequent development of speech, language, cognition and behavior. Impairment of task orientation, distractibility, short term attention spans and goal orientation together with restlessness, fidgetiness, destructive behavior and disobedience may result.

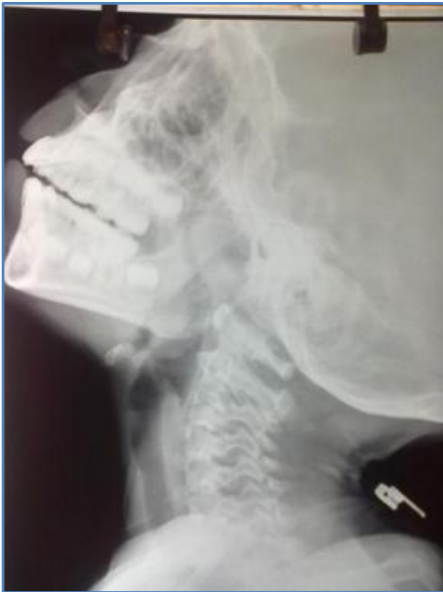OBJECTIVE OF STUDY: To study the role of adenoidectomy in the management of otitis media with effusions.

TYPE OF STUDY – A prospective clinical study.

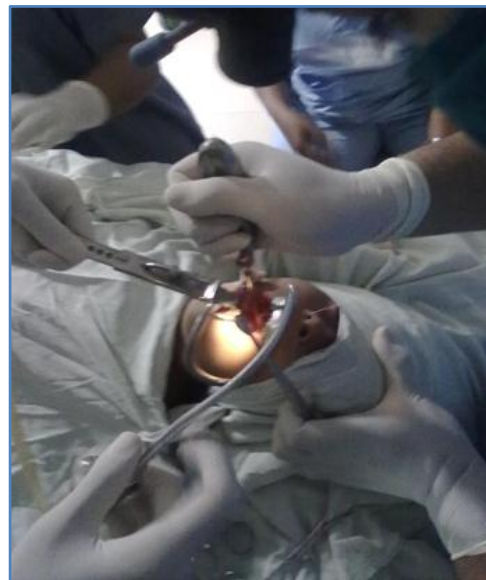
ORIGINAL ARTICLE

MATERIALS AND METHODS: Study conducted in department of ENT, GMCH. Study period is from Feb 2011 to December 2011. Total number of cases studied is 20. Hearing loss assessment in these patients in the form of PTA and TYMPANOMETRY before and after adenoidectomy assessed. Age range of our patients was from 3 to 14 years of age.

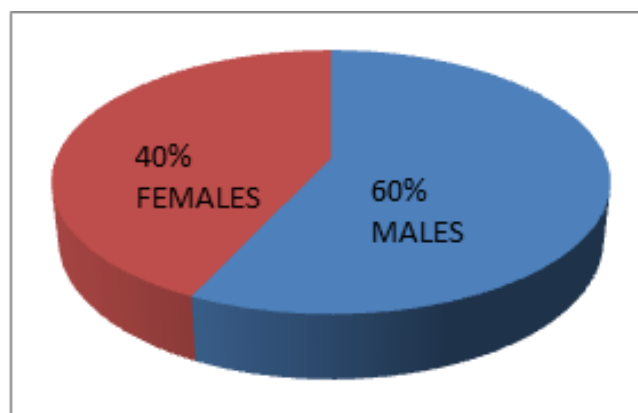
PROCEDURE: Always under general anesthesia, with oral endotracheal intubation. The patient is put in supine position. Hyperextension of neck is avoided. Boyle Davis mouth gag is inserted. The nasopharynx is examined by retracting the soft palate with palatal retractor and by digital palpation adenoid mass is confirmed. Proper size of "adenoid curette with cage" is introduced into the nasopharynx till its free edge touches the posterior border of nasal septum and is then pressed backwards to engage the adenoids. At this level head is slightly flexed to avoid injury to the atlanto-occipital joint. With gentle sweeping movement, adenoids are shaved off. Lateral masses are similarly removed with smaller curettes. Hemostasis is achieved by packing the area for sometime.



X ray nasopharynx showing adenoid hypertrophy



Procedure of adenoidectomy



ORIGINAL ARTICLE

OBSERVATIONS IN MY STUDY: Age range in my study was from 3 to 14 years of age.

SEXWISE DISTRIBUTION:

Total no. of cases studied – 20

No. of males – 12 60 %

No. of females – 840 %

DISTRIBUTION ACCORDING TO HEARING LOSS:

Mild conductive hearing loss 14 cases

Moderate conductive hearing loss 4 cases

Severe hearing loss 2 cases.

SMALL (if it occupies 25% of nasopharynx)	MODERATE (if it occupies 50% of nasopharynx)	LARGE (if it occupies >75 % of nasopharynx)
14 CASES	4 CASES	2 CASES
DISTRIBUTION ACCORDING TO SIZE OF ADENOIDS BASED ON PLAIN X RAY NASOPHARYNX (LATERAL VIEW)		

RESULTS AND FOLLOW UP: Out of 14 cases that came with mild conductive hearing loss, showed improvement to normal hearing after 2 months of follow up. Tympanogram preoperatively showed TYPE B and postoperatively showed TYPE A.

Out of 4 cases that came with moderate hearing loss, 2 of them improved to normal hearing and the other 2 to mild conductive hearing loss after 2 months of follow up. Tympanometry here too was of TYPE B preoperatively and post operatively showed TYPE A.


1 case that came with profound mixed hearing loss in the left ear and moderately severe mixed hearing loss in the right ear showed improvement to normal hearing after 2 months of follow up but at 1 year of follow up the patient showed moderate sensorineural hearing loss.

1 case that came with bilateral severe hearing loss showed improvement to bilateral mild hearing loss after 2 months of follow up. FLAT tympanogram preoperatively and TYPE A postoperatively noted.

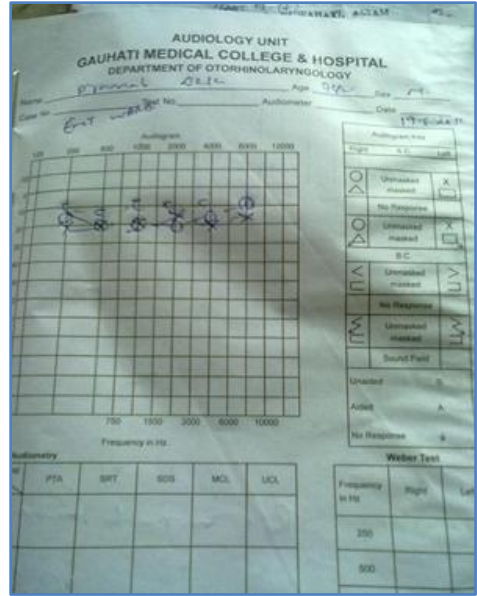OUT OF 14 CASES THAT PRESENTED WITH MILD CONDUCTIVE HEARING LOSS

Pre operative and post operative audiometry findings:

ORIGINAL ARTICLE



Preoperatively - bilateral mild conductive hearing loss.



Postoperatively - normal hearing

OUT OF 4 CASES THAT PRESENTED WITH MODERATE CONDUCTIVE HEARING LOSS

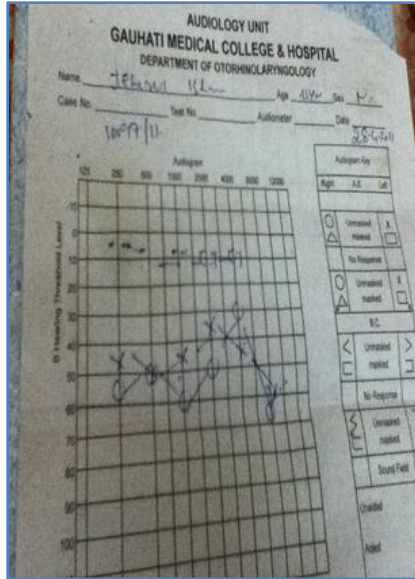


Preoperatively - right ear (moderate conductive hearing loss) Left ear - (mild conductive hearing loss)

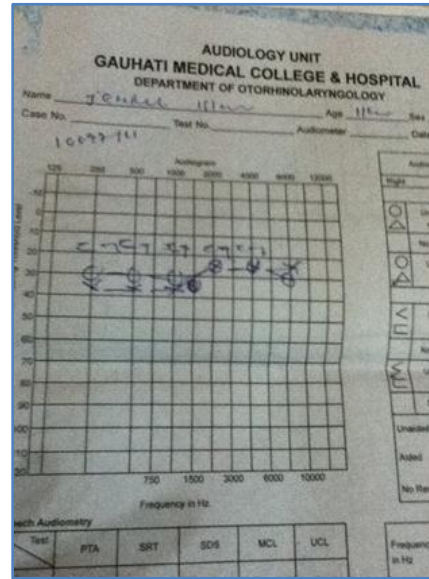

Postoperatively - bilateral normal hearing.

ORIGINAL ARTICLE

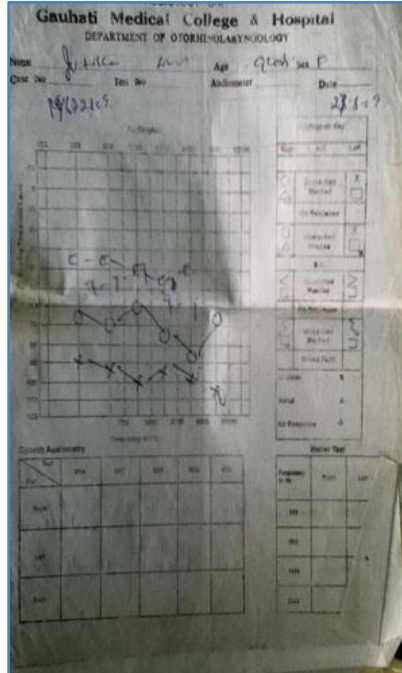


**Preoperatively – right ear (moderate severe conductive hearing loss)
Left ear (moderate conductive hearing loss)**

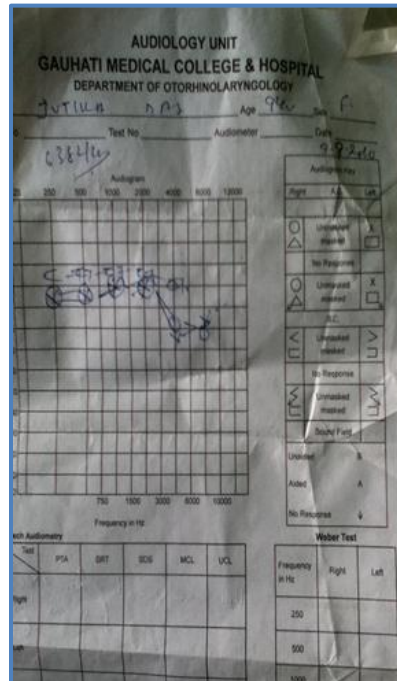

Postoperatively – bilateral mild conductive hearing loss.

1Case presented with profound mixed hearing loss in left ear and moderate severe mixed hearing loss in right ear.



**Preoperatively – right ear (moderate severe mixed hearing loss)
Left ear (profound mixed hearing loss)**



Postoperatively – bilateral normal hearing

ORIGINAL ARTICLE

REVIEW OF LITERATURE: In 1973, SHAMBAUGH & QUIE stated that prophylaxis for recurrent otitis media in children should first be the removal of adenoids.

In 1990, Paradise and colleagues, conducted a study on 42 children (5 - 14 years) suffering from recurrent cases of OME following insertion of tympanostomy tubes. He adenoidectomized these patients with/ without use of grommets and finally concluded that adenoidectomy was of value for those children who developed recurrent OME following extrusion of tympanostomy tubes.

In a study conducted by MAW& BAWDEN in 1993, he concluded that upto 50% of children who have had grommets will have a further episode of OME (after grommets are removed) requiring additional surgery and adenoidectomy reduces future operations by 50%.

Van damne et al (1999) found that OME proven children were significantly more likely to harbor typical middle ear pathogens such as strept pneumonia, moraxella, H influenza in their adenoids than were those children who were not prone to OME. In addition, this nasopharyngeal colonization was reduced after adenoidectomy. He concluded from his study that adenoidectomy, as a surgical modality of treatment in patients of OME is quite promising.

MARE et al (2000), in several studies in children with OME, demonstrated that adjuvant adenoidectomy in combination with tympanostomy tube insertion decreased the need for subsequent tube insertion and that adenoidectomy alone was as effective as tympanostomy tube insertion.

Peter c coyte (2001)⁴, Medline institute, ontario; Canada, did a retrospective study from 1995-1997 in around 37,000 children and he concluded that performing adenoidectomy or adenotonsillectomy at the time of initial insertion of tympanostomy tubes substantially reduces the likelihood of additional hospitalization and operations related to otitis media among children 2 years of age or older.

In a study by Chia der lin et al, China medical college, Taiwan(2002), they studied 44 patients of otitis media with effusion in the age group 3-14 years of age; all patients received transoral endoscopic adenoidectomy and insertion of tympanostomy tubes. Core adenoid tissue and middle ear fluid were cultured. Microorganisms were isolated in adenoid tissue in 84% (37/44) patients. He then concluded that adenoidal reservoir of bacteria may be associated with OME and the clinical benefits of adenoidectomy in the health management of children with OME should not be overlooked.

In a study conducted over a period of 10 years from Jan 1996 - Dec 2006 by Hale wittenberg, university ENT hospital, Germany, a total of 7495 surgical procedures related to OME in children were conducted. 2150 myringotomies, 921 laser assisted myringotomies, 1134 tympanostomy tube insertion, 2969 adenoidectomies and 321 re-adenoidectomies were done. They performed adenoidectomy with tube insertion in cases of mucous secretion in middle ear and laser myringotomy with adenoidectomy in serous secretion in middle ear. They concluded that in children 4yrs and above adenoid with myringotomy has better efficacy than tympanostomy tubes alone. In healthy children with persistent OME, prompt insertion of tympanostomy tube does not improve developmental outcome. Adenoidectomy with/ without tubes has better results.

In a study by Ramya (2006), RGUHS, children aged 5-12 years and presenting with OME and persistent hearing impairment were taken up for study. 50 eligible children were recruited and studied prospectively for 13months. 41(84%) patients had symptoms suggestive of adenoid hypertrophy at presentation. They concluded that in cases of persistent OME, tympanostomy and adenoidectomy should be done in same sitting.

ORIGINAL ARTICLE

In a study by Margareth A et al⁵ (2010) children aged 2–3 years were taken up for study. 98 subjects were treated with myringotomy & tympanostomy tube insertion / adenoidectomy with myringotomy and tympanostomy tube / adenoidectomy with myringotomy. They concluded that adenoidectomy with/without tube insertion had less recurrence than those with tube insertion alone, on follow up.

DISCUSSION AND CONCLUSION: For otitis media with effusion due to adenoid hypertrophy, adenoidectomy alone has been shown to produce significant improvement in hearing loss.

Regression of adenoid occurs rapidly after 15 years of age in most children. The adenoid produce 'B cells' which gives rise to IgG and IgA plasma cells. The adenoid appears to have an important role in the development of an 'immunological memory' in younger children. The removal of this tissue at a younger age may be immunologically undesirable.

Still, adenoidectomy is recommended if it is responsible for OME and subsequent hearing loss because long standing effects of hearing loss includes impairment of development of speech, language, cognition and behavior. Adverse effects have also been reported on expressive verbal vocabulary, speech perception and language cognition tests. Persistence of disease will lead to complications like atelectasis and attic retraction.

In one of our cases who presented with profound mixed hearing loss, had earlier been operated with grommet insertion 5 years back. The patient came back with profound mixed hearing loss but after adenoidectomy showed normal hearing. At 1 year of follow up though, the patient showed moderate sensorineural hearing loss.

Previously myringotomy and ventilation tube insertion have been recommended in OME. But myringotomy has a short lived beneficial effect and there seems to be a need for retreatment with tubes in most of the patients.

Hence adenoidectomy may be considered as a part of the surgical management of children over the age of 3 years with OME.

REFERENCES:

1. Michael Gleeson, Nicholas Jones; Scott brown's otorhinolaryngology and head and neck surgery, Hodder Arnold publication, year 2008, 7th edition: volume 3, chapter 34 pages 418 – 454.
2. Harold Ludman and Tony Wright "ABC of otorhinolaryngology" by, BMJ books publication, year 1993, 3rd edition, chapter 7, pages 105 – 155.
3. T Phelps, W M Abuzeid "Cummings book of otorhinolaryngology and head and neck surgery", Benjamin cummings publications; 2002, 4th edition, volume 3, pages 759 – 781.
4. Peter C. Coyte, Ph.D., Ruth Croxford, M.Sc., Warren McIsaac, M.D "The Role of Adjuvant Adenoidectomy and Tonsillectomy in the Outcome of the Insertion of Tympanostomy Tubes." (J Med 2001; issue 34: pages 1188-1193).
5. Margareth A Casselbrant, MD, PhD. Ellen Mander MD. Charles Bluestone. "Adenoidectomy for Otitis Media with Effusion in 2 to 3 years old Children". (Pubmed 1997, issue 21, pages 215-219).

ORIGINAL ARTICLE

6. Gates G.A., Avery C.A., Prihoda T.J., Cooper J.C N; "Effectiveness of adenoideotomy and tympanostomy tubes in the treatment of chronic otitis media with effusion" by. Engl.(J. Med. Issue 25, pages 322 – 327.)
7. Paradise J.L, Feldman H.M, Campbell T.F, Dollaghan C.A. et al. Tympanostomy tubes and developmental outcome at 9 to 11 years of age. N. Engl. 2007: J.Med. issue 18; page 356 - 360)
8. Bluestone C.D. "Management of otitis media in infants and children: current role of old and new antimicrobial agents". (Pediatr. Infect Dis. J.med, 7(Suppl. 1), pages 129 - 132, 1988.)
9. Conticello S, Ferlito S, Ciccia R; "Recurrent otitis media: a rational therapeutic approach".In: J. Sadè: (Elsiever Science 72-78, 1994.)

AUTHORS:

1. Avinash Kumar
2. Rupanjita Sangma

PARTICULARS OF CONTRIBUTORS:

1. Post Graduate Trainee, Department of ENT and Head and Neck Surgery, Gauhati Medical College and Hospital.
2. Assistant Professor, Department of ENT and Head and Neck Surgery, Gauhati Medical College and Hospital.

NAME ADDRESS EMAIL ID OF THE CORRESPONDING AUTHOR:

Dr. Avinash Kumar,
House No. 3/3, Sharada Apartments,
154, Dhalbhum Road, Aambagan,
Sakchi, Jamshedpur, Jharkhand – 831001.
E-mail: invincibleavinash@yahoo.co.in

Date of Submission: 22/05/2014.
Date of Peer Review: 23/05/2014.
Date of Acceptance: 03/06/2014.
Date of Publishing: 16/06/2014.