

RADIOLOGICAL PATTERN OF LUNG CANCER – A PROSPECTIVE OBSERVATIONAL STUDY

Allena Prem Kumar¹, B. M. S. Pathrudu², D. Anuradha³, Banavath Durgaprasad Naik⁴, L. Haritha Kumari⁵, B. Sravani Lakshmi⁶, V. Swetha⁷, K. Ram Kumar⁸

HOW TO CITE THIS ARTICLE:

Allena Prem Kumar, B. M. S. Pathrudu, D. Anuradha, Banavath Durgaprasad Naik, L. Haritha Kumari, B. Sravani Lakshmi, V. Swetha, K. Ram Kumar. "Radiological Pattern of Lung Cancer- A Prospective Observational Study". Journal of Evolution of Medical and Dental Sciences 2015; Vol. 4, Issue 86, October 26; Page: 14917-14925, DOI: 10.14260/jemds/2015/2119

ABSTRACT: This was performed to observe various radiological presentations of lung cancer at the initial evaluation and to elicit correlation to histopathological diagnosis in all patients to a tertiary chest care hospital. **AIM:** To study various radiological presentations among lung cancer patients Method: we included all the patients with lung cancer reviewed during a 12mth period between March 2012 to November 2014 who had a definite tissue diagnosis and whose staging based on CT thorax were available. **RESULTS:** 65 patients were evaluated. Right sided lesions predominated with 60% and on left side being 40%. On either side put together, upper lobe 46.15% & middle lobe 36.9% and lower lobe 16.9%. Based on location of tumor 26% of the lesions are peripherally located, 24.5% are central localization, 13.8% are located intermedially. Radiological pattern of presentation: 67% of the cases presented as mass lesions, 9% as obstructive pneumonitis and 23% as combined mass with collapse and 23.07% as pleural effusion. Histological pattern of presentation: squamous cell carcinoma is most common type with 49.23%, adeno 33%, small cell 15%, others 1.5% Most of the cases presented to the hospital in stage IV with 56.36% and stage IIIA 16.36% and stage IIIB as 18.18%. **CONCLUSION:** we observed most of the lung cancers presented as mass lesion with peripherally located tumor and the most common histological type is squamous cell carcinoma, presented at advanced stages.

KEYWORDS: lung cancer, obstructive pneumonitis, mass with collapse, squamous cell carcinoma, adenocarcinoma.

INTRODUCTION: Lung cancer was considered to be rare in the beginning of the century.¹ but has now reached almost epidemic proportions. It is the leading cause of cancer deaths in developed countries and is also rising at alarming rates in developing countries. ² Deaths due to lung cancer are more than those due to colorectal, breast and Prostate cancers put together.³ Incidence and mortality from lung cancer in females is rising while it is declining in males in developed countries.³ This is the single most devastating cause of cancer-related deaths.² with approximately 1.5 million cases worldwide and more than 1.3 million cancer-related deaths in 2001. There is a great variation in the prevalence of lung cancer in different geographical areas.

Previously Lung cancer was considered to be infrequent in India, but in the recent past a trend of increase in its incidence has been noticed Lung cancer has been estimated to be the most frequent among all the new cases of cancers in male in this country.⁴ Compared to western population, epidemiological study shows that there is increased prevalence of lung cancer in Indian population

Despite advances in imaging techniques and treatment modalities, the prognosis of lung cancer remains poor, with a five-year survival of 14% in early stages and less than 5% in locally advanced stages.^{5,6} Unfortunately only 20-30% of patients present with an operable disease, while most of the

ORIGINAL ARTICLE

patients present in an advanced stage III and IV. The main reason for late presentation in our country is the poor health awareness, delayed diagnosis and the low rate referral of patients to the specialized centers.

This study was undertaken to analyze the different radiological presentation, based on histopathology of lung cancer in patients presented to our hospital.

AIMS & OBJECTIVES OF THE STUDY:

This study was undertaken to analyze:

- Radiological presentation.
- Histopathological pattern of lung cancer.

PATIENTS AND METHODS: The present study comprises of 65 patients who are admitted in the Department of Tuberculosis and Chest Diseases, Andhra Medical College, Visakhapatnam, from March 2012 to November 2014.

STUDY DESIGN: It is a prospective observational study consisting of 65 Lung cancer patients with radiological and Histopathological Profile.

INCLUSION CRITERIA:

- 1) Patients with Age >18 years who were diagnosed as lung cancer based on histopathology.
- 2) Patients with any radiological features like space occupying lesion, hilar prominence, mediastinal widening, and collapse with consolidation, attending to GHCCD, Visakhapatnam were included in the study.

EXCLUSION CRITERIA:

- Sputum positive for AFB.
- Patients with poor general condition who are not amenable to any procedure.
- Pulmonary hypertension.
- Suspected vascular lesion.
- Bleeding disorders.

STUDY PROTOCOL: Every consecutive patient with lung cancer was included in the study. Based on demographic and clinical, histopathological parameters Baseline Chest X-ray both PA (Posteroanterior view and lateral views were taken in all patients. Radiological assessment was done in all patients. But CT scans of abdomen, brain or other parts of body were done in limited cases if suggestive symptoms of involvement were there as appropriate due to economic constrains. After the histopathological diagnosis was made and staged according to American Joint Commission on Cancer (AJCC), revised staging system 7th edition based on the available radiological findings. After histopathological diagnosis of lung cancer all the patients with different radiological presentation were assessed.

ORIGINAL ARTICLE

RESULTS AND OBSERVATIONS: This was a prospective observational based study done in Department of Pulmonary Medicine, Government Hospital for Chest & Communicable Diseases/Andhra Medical College, Visakhapatnam from March 2012 to November 2014. Total number of patients in the study was 65.

DEMOGRAPHIC DATA: The different radiological presentations in chest x ray and computed topography scan were assessed and tabulated in all cancer patients.

Side of the lesion	No. of patients	Percentage
Right Lung	39	60.00%
Left Lung	26	40.00%

Table 1: Distribution of localization of lesion – Side wise

Most of the lesions were present on right side (60%).

	No. of patients	Percentage
Upper lobe	30	46.15%
Middle lobe	24	36.9%
Lower lobe	11	16.9%

Table 2: Lobar distribution of lung cancer

Lung cancer was seen predominantly in upper lobe

Radiological presentation	No. of patients (n=65)	Percentage
Mass	44	67.69%
Obstructive pneumonitis	6	9.23%
Combined (Mass with collapse)	15	23.08%

Table 3: Radiological presentation of Lung cancer based on ct scan

In present study, space occupying lesion (Mass) was the commonest radiological presentation (67.69%). (Fig. 1)

	No. of patients	Percentage (%)
Hilar adenopathy	21	32.31%
Mediastinal lymphadenopathy	14	21.54%
Rib erosion	5	7.69%
Lymphangitis carcinomatosis	4	6.15%
Cavitating Mass	3	4.62%
PLEF	15	23.07%

Table 4: Other Radiological features:

In present study, 32.31% of patients presented with hilar adenopathy, 21.54% were with mediastinal lymphadenopathy, PLEF was seen in 23.08% patients (Fig. 2), rib erosion in 7.69% patients, and cavitating carcinoma was seen in 4.62% of patients.

ORIGINAL ARTICLE

Location	Number of patients and percentage	Size of tumor
Peripheral	17 (26.9%)	132mm
Central	11 (16%)	112mm
Mediastinal	5 (7.6%)	28mm
Intermediate	9 (13.8%)	25mm

Table 5: based on tumor location and size:

In the present study, most of the cases were located at the peripheral part of lung (26.9%) among 17 patients (Fig. 3).

	No. of patients	Percentage
Adrenal gland	6	17.14%
Liver	10	28.57%
Contra lateral lung	8	22.85%
Brain	2	5.71%
Bone	9	25.71%

Table 6: Distribution of Metastasis - location wise

Most common site of metastasis (Fig. 4) is liver among 10 patients (28.5%).

Histopathological Type	No. of patients	Percentage
Squamous cell Ca	32	49.23%
Adeno Ca	22	33.85%
Small cell Ca	10	15.38%
Others	1	1.54%

Table 7: Histopathological presentation:

Squamous cell carcinoma was the commonest histopathological type noted accounting for 49.23% followed by adenocarcinoma 33%, small cell carcinoma 15%, others 1.5%.

Single case of 'others' is a case of undifferentiated carcinoma.

Histological type	Stage IIA	Stage IIB	Stage IIIA	Stage IIIB	Stage IV
Squamous cell carcinoma (n= 32)	0	3 (9.37%)	6 (18.75%)	6 (18.75%)	17(53.12%)
Adeno carcinoma (n=22)	0	2 (9.09%)	3 (13.63%)	3 (13.63%)	14(63.63%)
Others (n=1)	0	0	0	1 (1.81%)	0

Table 8: Stage at presentation in various Histopathological Types:

In both squamous and adenocarcinoma, most of the patients presented with stage IV 56.36% and stage IIIA 16.36%, stage IIIB 18.18%..

Histopathological Type	Mass	Obstructive Pneumonitis	Combined (Mass and collapse)	Pleural Effusion
Adenocarcinoma (22)	16(72.7%)	--	7(31.8%)	10(45.4%)
Squamous cell carcinoma(32)	22(68.7%)	4(12%)	6(18%)	5(15%)
Small cell lung carcinoma(10)	3 (30%)	2(20%)	2(20%)	--
Others	1			

Table - 9: Comparision with Histopathology and Radiological Parameters:

ORIGINAL ARTICLE

In the present study mass lesions, obstructive pneumonitis, combined (Mass and Collapse) are more common in squamous cell, and pleural effusion is more common in adeno carcinoma.

DISCUSSION: Lung cancer is one of the common malignant diseases and the most common cause of cancer death in the world. Lung cancer is the most common fatal malignancy among men and women in most countries of the world and the gender difference is narrowing.⁷ In India, the incidence of lung cancer is increasing rapidly, mainly due to progressive change in life style. Further, squamous cell carcinoma continues to be commonest histopathological type in India, whereas adenocarcinoma is gradually becoming the prominent variant in the western world.

Most of the older and some recent Indian series have described squamous cell carcinoma as the commonest histology.^{8,9} In the present study radiological profile of lung cancer in patients attending to Government Hospital for Chest and Communicable Diseases were analyzed after histopathological diagnosis. The study consisted of 65 patients all of them have met inclusion criteria.

RADIOLOGICAL PRESENTATION: Radiological assessment was done in all patients. The most common radiological presentation seen in present study was mass followed by combined presentation of mass with collapse. (Fig. 1).

RADIOLOGICAL DISTRIBUTION: Lobe Wise: In the present study, the space occupying lesion was most commonly seen in Upper lobe (46.15%).

OTHER RADIOLOGICAL FEATURES: Hilar adenopathy was found in most of the patients (32.31%), and 21.54% of patients were shown with mediastinal lymphadenopathy. 4.62% patients were cavitating carcinoma. lymphangitis carcinomatosa was seen in 6.15% of the cases, rib erosion in 7.69%, and pleural effusion in 23.08% of patients.

LOCATION OF TUMOR: In the present study, most of the lung cancers were presented as mass lesions located at peripheral part of lung on right side.

HISTOPATHOLOGICAL PRESENTATION: In recent years, there has been a great interest in the histological characterization of lung cancer in view of newer histology guided therapeutic modalities and genomic classification of lung carcinoma.^{10,11}

The relative frequency and clinicopathological profile of different histological subtypes of lung cancer have been changing in recent years, probably due to changes in the smoking habit, growing popularity of low-tar/filter cigarettes and exposure to other Occupational and environmental agents.^{3,12}

In present study, the most common histopathological type was squamous cell carcinoma (49.23%), followed by adenocarcinoma (33.84%), small cell carcinoma (15.38%). And one single case was diagnosed as undifferentiated Carcinoma. (1.54%).

There is a variation in histological diagnosis, however squamous cell cancer has been the most common histological type of lung cancer in India as shown by these studies.

In the recent past, a relative increase in the incidence of adenocarcinoma has been witnessed. In most of the developed countries, it has become the dominant histological type of lung cancer.

ORIGINAL ARTICLE

It has also overtaken squamous cell carcinoma as the most common form of lung cancer among males in some countries while it has continued to be the commonest type among females.

In present study the most common histological diagnosis came out to be squamous cell carcinoma but Adenocarcinoma was a close second.

STAGE AT PRESENTATION: The TNM (Tumor-node-metastasis) classification system for lung cancer is a vital guide for determining treatment and prognosis. Despite the importance of accuracy in lung cancer staging, however, correct staging remains a challenging task for many radiologists. Radiologically cavitation, consolidation and mass like lesion are common to both tuberculosis and lung cancer and in India, since tuberculosis is very prevalent and it is not uncommon to find a lung cancer being treated as tuberculosis initially. This is another reason for the lung cancer presenting with advanced stages of disease.

In the present study, none of the patients presented with stage I and IIA, and 9.09% presented with stage IIB. Among stage III, 16.36% patients were presented with stage IIIA and 18.18% were with stage IIIB. Most of the patients presented with stage IV i.e. 56.36%. However, nodal station involvement could not be assessed accurately in all patients due to several constraints. Hence, the actual number of patients with non-resectable carcinoma stage III B/IV disease may actually be under reported in this study.

DISTANT METASTASIS: Distant metastasis is almost always encountered in the course of lung cancer. Initial staging evaluations have determined that 40–60% of patients present with metastatic disease.^{13,14} The most common sites of metastasis encountered in pretreatment evaluations are the contra lateral lung, bone, brain, liver and adrenal gland.¹⁵⁻¹⁷

In present study, liver was the most common site of distant metastasis followed by bone, adrenal glands. (Fig. 4).

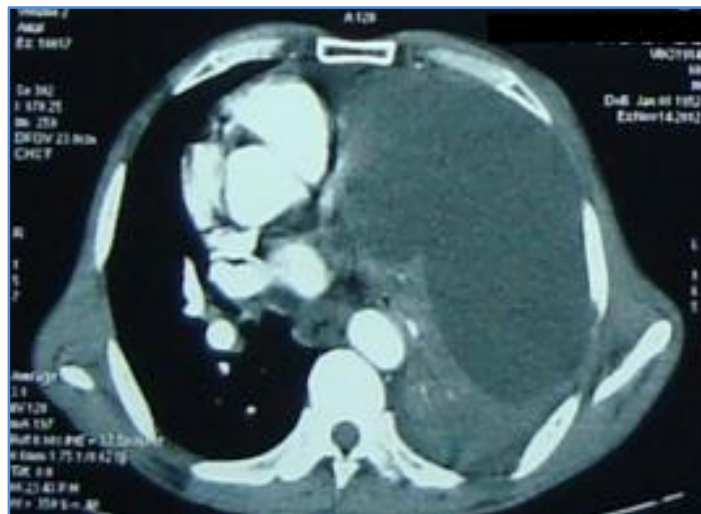


Fig. 1: Mass with collapsed lung on right

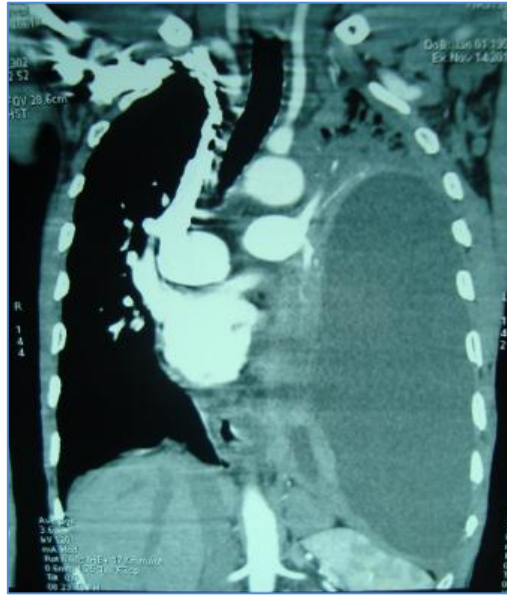

Fig. 2: Mass with massive pleural effusion on left side of lung

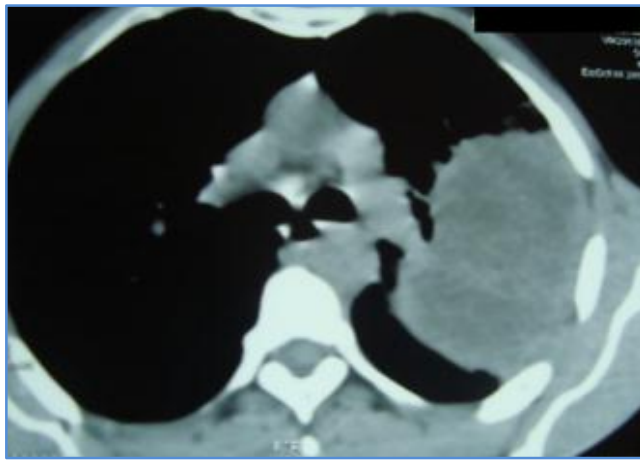


Fig. 3: Peripheral based lung mass on right side with mediastinal invasion and chest wall

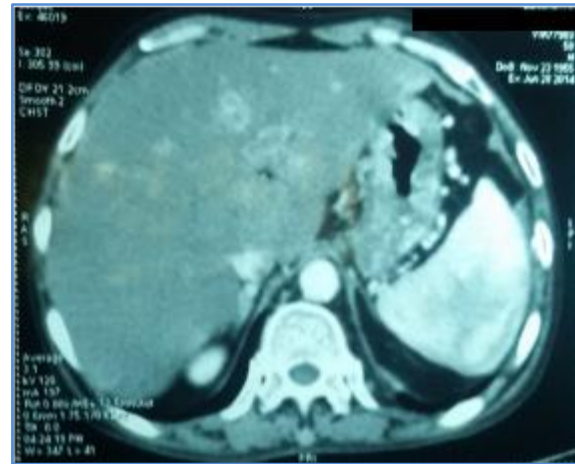


Fig. 4: liver and bone metastasis secondary to lung carcinoma

CONCLUSION: This study we observed that most of the lung cancers were presented as peripherally located mass lesions, histopathologically most of them were squamous cell carcinoma Majority of the cases were misdiagnosed at peripheral health institutions as tuberculosis and treated, causing delay in diagnosis. This emphasized the need for more effective methods like FOB, CT for early detection of lung cancer. The main reason for late and advanced stage presentation in our country is the poor health awareness, delayed diagnosis and the low rate referral of patients to the specialized centers.

REFERENCES:

1. Parkin DM, Muir CS, Cancer incidence in five continents: Comparability and quality of data: IARC Sci Publ; 1992: 120, 45-173.
2. Khuri FR, Herbst RS, Fossella FV: Emerging therapies in non-small cell lung cancer.: Ann Oncol; 2001: 12, 739-44.
3. D. Behera, T. Balamugesh: Lung cancer in India. Indian Journal of Chest Diseases & Allied Sciences; 2004: Vol. 46.
4. Haque, AK pathology of carcinoma of lung: an update on current concepts. J Thorasic imaging; 1991: 7, 22-25.
5. International Agency for Research on Cancer. GLOBOCAN 2008-Cancer Incidence and Mortality Worldwide in 2008. Available from: <http://www.globocan.iarc.fr/>.
6. N.A. Khan, F. Afroz, M. M. Lone, M. A. Teli, M. Muzaffar and N. Jan: Profile of Lung Cancer in Kashmir, India: A Five year study. The Indian Journal of Chest Diseases & Allied Sciences; 2006: Vol.48.
7. Mghfoor I, Michael C Perry: Lung cancer. Ann Saudi Med; 2005: 25: 1-12.
8. Montain CF: A new international staging system for lung cancer. Chest;1986:89 (suppl.): 225-33.
9. Overholt RH, Neptune WB, Ashraf MM: Primary cancer of lung: a 42-year-experience. Ann Thorac Surg; 1975: 20: 511-9.
10. Magarth I, Litak J. Cancer in developing countries: opportunity and challenge. J Natl Cancer Inst 1993; 85: 862-74.
11. Jemal A, Thomas A, Murray T, Thun M. Cancer statistics, 2002. CA Cancer J Clin; 2002:52: 23-47.
12. Singh N, Aggarwal AN, Gupta D: Unchanging clinico-epidemiological profile of lung cancer in north India over three decades. Cancer Epidemiol; 2010: Vol 34, 101-4.
13. Jindal SK, Behra D: Clinical Spectrum of primary lung cancer: Review of Chandigarh experience of 10 years. Lung India; 1990: 8:94-98.
14. Satoh H, Kurishima K, Nakamura R, et al: Lung cancer in patients aged 80 years and over. Lung Cancer; 2009: 65:112-118.
15. Kobrinsky NL, Klug MG, Hokanson PJ, et al: Impact of smoking on cancer stage at diagnosis. J Clin Oncol; 2003:21:907-913
16. Satoh H, Ishikawa H, Kamma H, et al: Serum sialyl Lewis X-i antigen levels in non-small cell lung cancer: correlation with distant metastasis and survival. Clin Cancer Res; 1997: 3:495-499.
17. Olak J: Surgical strategies for metastatic lung cancer. Surg Oncol Clin N Am; 1999: 8:245-257.

ORIGINAL ARTICLE

AUTHORS:

1. Allena Prem Kumar
2. B. M. S. Pathrudu
3. D. Anuradha
4. Banavath Durgaprasad Naik
5. L. Haritha Kumari
6. B. Sravani Lakshmi,
7. V. Swetha
8. K. Ram Kumar

PARTICULARS OF CONTRIBUTORS:

1. Professor, Department of Pulmonary Medicine, Andhra Medical College.
2. Assistant Professor, Department of Pulmonary Medicine, Andhra Medical College.
3. Postgraduate, Department of Pulmonary Medicine, Andhra Medical College.

FINANCIAL OR OTHER

COMPETING INTERESTS: None

4. Postgraduate, Department of Pulmonary Medicine, Andhra Medical College.
5. Postgraduate, Department of Pulmonary Medicine, Andhra Medical College.
6. Postgraduate, Department of Pulmonary Medicine, Andhra Medical College.
7. Postgraduate, Department of Pulmonary Medicine, Andhra Medical College.
8. Postgraduate, Department of Pulmonary Medicine, Andhra Medical College.

NAME ADDRESS EMAIL ID OF THE CORRESPONDING AUTHOR:

Banavath Durgaprasad Naik,
No. 88, KGH PG Men's Hostel,
Visakhapatnam-530002.
E-mail: durgaprasad900@gmail.com

Date of Submission: 05/10/2015.
Date of Peer Review: 06/10/2015.
Date of Acceptance: 16/10/2015.
Date of Publishing: 23/10/2015.