

ENDOSCOPIC SCLEROTHERAPY IN ESOPHAGEAL VARICES: AN EFFECTIVE TREATMENT MODALITYS. S. Karbhari¹, Veeresh Hosamani², R. B. Dhaded³**HOW TO CITE THIS ARTICLE:**

S. S. Karbhari, Veeresh Hosamani, R. B. Dhaded. "Endoscopic Sclerotherapy in Esophageal Varices: An Effective Treatment Modality". Journal of Evolution of Medical and Dental Sciences 2014; Vol. 3, Issue 68, December 08; Page: 14601-14606, DOI: 10.14260/jemds/2014/3961

ABSTRACT: BACKGROUND: Varices are expanded blood vessels that develop most commonly in the esophagus. Esophageal varices is responsible for 5-11% of all cases of upper GI bleeding. Endoscopic injection sclerotherapy (EST) is a valuable therapeutic modality for the management of variceal bleeding. Other options for treatment such as variceal band ligation are either expensive or unavailable. **AIM:** To study the common causes for development of portal hypertension to present as esophageal varices and its different clinical mode of presentation and to know the effect of endoscopic sclerotherapy with absolute alcohol particularly in acute bleeding varices of different grades. **MATERIALS AND METHODS:** A clinical study of esophageal varices who presented to casualty in Basaveshwar Teaching and General Hospital, Gulbarga; from May 2012 to May 2014. Etiology, presentation, outcome from EST was evaluated. **RESULTS:** Common affected age group was 30-50yrs, common presentation is haematemesis (90%), melena (55%), distension of abdomen (70%), haemorrhoids (20%) and all cases of esophageal varices were due to portal hypertension, the common pathological condition was cirrhosis (alcoholic, cryptogenic, posthepatitis cirrhosis) and next common was portal vein thrombosis followed by splenic vein thrombosis. 70% cases of bleeding varices were very well controlled with EST alone and some needed initial sengstaken balloon tamponade treatment to control the bleeding followed by EST (30%). Recurrence of bleeding and complications of EST is less. **CONCLUSION:** This study provides evidence that endoscopic injection sclerotherapy is an important component in the management of bleeding oesophageal varices caused by portal hypertension. It is a safe and effective procedure.

KEYWORDS: portal hypertension, sclerotherapy, oesophageal varices, endoscopy.

INTRODUCTION: Bleeding from gastro-oesophageal varices is the most serious and life-threatening complication of portal hypertension and accounts for 5-11% of all cases of bleeding from the upper GI tract. When the HVPG rises above 10 mm of Hg, complications of portal hypertension can arise. Therefore, this value represents the threshold for defining portal hypertension as being clinically significant and plays a crucial role in the transition from the preclinical to the clinical phase of the disease.¹⁻³

The importance of this syndrome is characterized by the frequency and severity of complications, such as massive upper GI bleeding from ruptured gastroesophageal varices and portal hypertensive gastropathy, ascites, hepatorenal syndrome and hepatic encephalopathy.⁴ These complications are major causes of death and the main indications for liver transplantation in patients with cirrhosis. Prospective studies have shown that more than 90% of cirrhotic patients develop esophageal varices sometime in their lifetime and 30% of these will bleed. Variceal bleeding is the most severe complication of cirrhosis and is the second most common cause of mortality among the patients.⁷ In patients with cirrhosis, ruptured esophageal varices cause approximately 70% of all

ORIGINAL ARTICLE

upper digestive bleeding. Mortality from variceal bleeding has greatly decreased in the few decades from 42% in the Graham and Smith study⁸ to actual rates that range 6-12%.⁹ This decrease results from the implementation of effective treatment options, such as endoscopic and pharmacological therapies and transjugular intrahepatic portosystemic shunt (TIPS), as well as improved general medical care.¹⁰

Endoscopic injection sclerotherapy has been used to treat variceal hemorrhage for about 50 years. EST consists of the injection of a sclerosing agent into the variceal lumen or adjacent to the varix, with flexible catheter with a needle tip, inducing thrombosis of the vessel and inflammation of the surrounding tissues.^{11,12}

AIMS AND OBJECTIVES:

- To study the common causes for development of portal hypertension to present as esophageal varices and its different clinical mode of presentation.
- To know the effect of endoscopic sclerotherapy with absolute alcohol particularly in acute bleeding varices of different grades.

MATERIALS AND METHODS: This study includes 20 patients of esophageal varices who presented to casualty in Basaveshwar Teaching and General Hospital, Gulbarga; from May 2012 to May 2014.

After a careful history and thorough general and physical examination, stabilize the patients, if haemodynamically stable then subjected to upper GI endoscopy, along with relevant laboratory investigations. Ultrasound abdomen done to know the patency of collaterals, size of portal vein and splenomegaly.

On endoscopy if it is found to be esophageal varices then endoscopic sclerotherapy(EST) with absolute alcohol 2cc at each injection site(para or intra variceal) is given, if EST is not possible due to bad view because of bleeding patient is taken for EST electively once bleeding stopped. If patient is haemodynamically unstable, in shock, then sengstaken tube is passed through the nose and different bulbs are inflated with specific pressure. Blood transfusion is given. After 24 hrs sengstaken tube is removed and once bleeding stopped patient is subjected for EST. No patient undergone surgery for bleeding varices among 20 cases. Patient advised to review after 4-6 months endoscopy is repeated and if necessary EST is also repeated.

These 20 patients were followed up for any complications of sclerotherapy and recurrence of varices after treatment were noted. Informed consent was taken from the patients and the study had been approved by the ethical committee.

RESULTS:

Age group	No. of cases
1-10yrs	0
11- 20yrs	5
21-30yrs	2
31- 40yrs	6
41- 50yrs	6
51- 60yrs	1
Total	20

Table 1: Age wise distribution

ORIGINAL ARTICLE

Symptoms	Present in NO. Of Cases (%)	Absent in NO. Of Cases (%)	Total cases
Haematemesis	18 (90%)	2 (10%)	20
Malena	11 (55%)	9 (45%)	20
Distension of abdomen	14 (70%)	6 (30%)	20
Bleeding PR (Haemorrhoids)	04 (20%)	16 (80%)	20

Table 2: Symptomwise distribution

Esophageal varices	No. of cases	Percentage (%)
1 st degree	04	20%
2 nd degree	12	60%
3 rd degree	04	20%
Total	20	100%

Table3: Severity of esophageal varices

Child's criteria	A (%)	B (%)	C (%)
Bilirubin	35%	45%	20%
Albumin	30%	45%	25%
Ascitis	15%	60%	25%
Nutrition	55%	15%	30%
Average	34%	41%	25%

Table 4: Child's criteria

Treatment	No. of cases	Percentage (%)
EST alone	14	70%
EST + BalloneTamponade	06	30%
Surgery	00	00%
Blood Transfusion	17	85%

Table 5: Distribution of patients according to management

20 cases follow-up for 2 yrs	No. of cases (%)
Recurrence	2 (10%)
Complication of sclerotherapy (Stricture, Dysphagia)	2 (10%)

Table 6: Follow up of cases

ORIGINAL ARTICLE

DISCUSSION: Of the 20 cases included in the study, age incidence ranges from 10-50 yrs, maximum patients fall in 30- 50 yrs age group. All 20 patients were males.

The common clinical presentation is haematemesis (90%), melena (55%), distension of abdomen (70%), haemorrhoids (20%) and all cases of esophageal varices were due to portal hypertension, the common pathological condition was cirrhosis (alcoholic, cryptogenic, posthepatitis cirrhosis) and next common condition was portal vein thrombosis followed by splenic vein thrombosis.

All suspected cases of portal hypertension with haematemesis patients were subjected to emergency upper GI endoscopy. The degree, number of varices and bleeding spot noted. It was found that about 60% were having 2nd degree varices and 20% cases were having 1st and 3rd degree each respectively.

Treatment given to these patients consists of general measures like IV fluids, ranitidine, vitamin k, haemostatic (streptochrome), blood transfusion, ryle's tube ice cold water gastric lavage, with these conservative measures if bleeding does not stop then sengstaken balloon tube was tried and kept for 24 hrs and removed after 24 hrs.

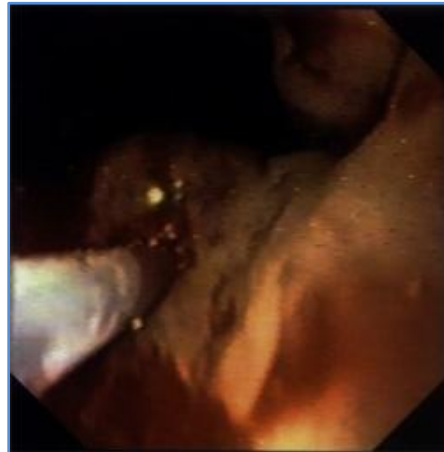
Once bleeding controlled and if all vitals are stable, then these patients are subjected to early endoscopic sclerotherapy. EST is given with absolute alcohol even at first diagnostic endoscopy. It was found that 1 or 2 sittings are required to stop bleeding and 3-4 sittings to obliterate the varices and interval between two sittings is one week.

In this study about 70% cases of bleeding varices were very well controlled with EST alone and some needed initial sengstaken balloon tamponade treatment to control the bleeding followed by EST (30%). No surgical treatment given to any of these cases. About 85% cases needed blood transfusion.

Siqueira et al performed a prospective randomized study in forty patients to compare the efficacy of both sclerotherapy and band ligation in eradicating oesophageal varices as well as the complications. They concluded that both treatments were equally effective in the eradication of oesophageal varices, although banding ligation is better tolerated by the patients and probably faster.¹³

For all cases in this study follow up was done, it was found about 10% cases had recurrence of bleeding. These cases were treated with EST again and about 10% cases developed dysphagia due to esophageal stricture.

Prognosis of these 20 cases is based upon to which group of child criteria they belongs. It is found among these cases about 34% cases fall in child criteria A, 41% cases fall in child criteria B, 25% cases fall in child criteria C.

**Figure 1**

CONCLUSION: Most cases oesophageal varices presents with haematemesis, melena, jaundice and less commonly bleeding per rectum. The common etiology for the disease (portal hypertension) is cirrhosis, occurs usually in middle age group (30-50yrs) people.

Majority of cases have 2nd to 3rd degree varices in this study, endoscopic sclerotherapy with absolute alcohol is a very effective mode of treatment to control bleeding varices and to obliterate the varices. Recurrence of bleeding and complications of EST is less. No case was subjected to surgical treatment as with initial EST bleeding was very well controlled hence cases were saved from grave complication- Hepatic Encephalopathy with surgical treatment.

This study provides evidence that endoscopic injection sclerotherapy is an important component in the management of bleeding oesophageal varices caused by portal hypertension. It is a safe and effective procedure.

REFERENCES:

1. Rigau J, Bosch J, Bordas JM, Navasa M, Mastai R, Kravetz D, Bruix J, Feu F, Rodés J. Endoscopic measurement of variceal pressure in cirrhosis: correlation with portal pressure and variceal hemorrhage. *Gastroenterology*. 1989; 96: 873–880.
2. Garcia-Tsao G, Groszmann RJ, Fisher RL, Conn HO, Atterbury CE, Glickman M. Portal pressure, presence of gastroesophageal varices and variceal bleeding. *Hepatology*. 1985;5:419–424
3. Ter Borg PC, Van Donselaar M, Van Buuren HR. Clinical events after TIPS: correlation with hemodynamic findings. *Gastroenterology*. 1998; 115: 1607.
4. Bosch J, García-Pagán JC. Complications of cirrhosis. I. Portal hypertension. *J Hepatol*. 2000; 32: 141–156.
5. D'Amico G. Esophageal varices: from appearance to rupture; natural history and prognosis indicators. In: Groszmann RJ BJ, ed, editors. *Portal Hypertension in the 21 st Century*. Dordrecht: kluwer Academic Publishers; 2004. pp. 147–154.
6. Calès P, Pascal JP. [Natural history of esophageal varices in cirrhosis (from origin to rupture)] *GastroenterolClin Biol*. 1988; 12: 245–254.
7. Graham DY, Smith JL. The course of patients after variceal haemorrhage. *Gastroenterology*. 1981; 80: 800–809.

ORIGINAL ARTICLE

8. Carbonell N, Pauwels A, Serfaty L, Fourdan O, Lévy VG, Poupon R. Improved survival after variceal bleeding in patients with cirrhosis over the past two decades. *Hepatology*. 2004; 40: 652–659.
9. De Franchis R. Revising consensus in portal hypertension: report of the Baveno V consensus workshop on methodology of diagnosis and therapy in portal hypertension. *J Hepatol*. 2010; 53: 762–768.
10. De Franchis R, Primignani M. Endoscopic treatments for portal hypertension. *Semin Liver Dis*. 1999; 19: 439–455.
11. Westaby D. Emergency and elective endoscopic therapy for variceal haemorrhage. *BaillieresClinGastroenterol*. 1992; 6: 465–480.
12. SiqueiraEduardoSampaio, Da sileria Rohr Maria Rachel, Dell LiberaErmelindo, et al. Band Ligation or Sclerotherapy as Endoscopic Treatment for Oesophageal Varices in Schistosomic Patients: Results of a Randomized Study. *HPB Surgery*. 1998; 11: 27–32.

AUTHORS:

1. S. S. Karbhari
2. Veeresh Hosamani
3. R. B. Dhaded

PARTICULARS OF CONTRIBUTORS:

1. Associate Professor, Department of Surgery, MRMC, Gulbarga.
2. Post Graduate, Department of Surgery, MRMC, Gulbarga.
3. Professor & HOD, Department of Surgery, MRMC, Gulbarga.

NAME ADDRESS EMAIL ID OF THE CORRESPONDING AUTHOR:

Dr. S. S. Karbhari,
Associate Professor,
Department of Surgery,
M. R. Medical College,
Gulbarga.

Email: sharankarbhari@gmail.com

Date of Submission: 25/11/2014.

Date of Peer Review: 26/11/2014.

Date of Acceptance: 02/12/2014.

Date of Publishing: 05/12/2014.