

## SURGICAL MANAGEMENT OF FRACTURE SHAFT HUMERUS WITH INTERLOCKING NAIL - A PROSPECTIVE STUDY

Muralidhar B.M<sup>1</sup>, Mahendranath Reddy D<sup>2</sup>

### HOW TO CITE THIS ARTICLE:

Muralidhar BM, Mahendranath Reddy D. "Surgical management of fracture shaft humerus with interlocking nail - a prospective study". Journal of Evolution of Medical and Dental Sciences 2013; Vol. 2, Issue 41, October 14; Page: 7863-7872.

**ABSTRACT: INTRODUCTION:** Conservative treatment of fracture humerus has resulted in malunion, nonunion, and ultimately poor functional outcome. Internal fixation of fracture shaft of humerus allows ready access for nursing care in patients with multiple injuries and associated comorbid conditions. And also restrictive bandages and splints are avoided, early mobilization of the patients and his limbs helps to prevent fracture disease. Hence the present study was undertaken to provide satisfactory functional outcome and to know the advantage and complications of the interlocking nail in treating humerus fracture. **MATERIALS AND METHODS:** A prospective study of 32 patients with closed diaphyseal fracture humerus aged above 18 years who were medically fit were included in study. They were managed surgically by using interlocking nail. Average follow up period was 38 weeks. Functions results were scored using Naiman, PT Schein, A.J. et al criterion. **RESULTS:** Male preponderance (62.5%) was observed in the study with right humerus predominance (56.25%). Road traffic injury accounted for 87.5% of fractures. Majority were middle third fractures (62.5%) with type A3 being the most common (53.125%). 2 patients had radial nerve palsy and they were recovered post operatively. 26 patients had sound union in less than 4 months and 3 patients at 6 months, with 29 (90.625%) cases having excellent result according Naiman, PT Schein, A.J. et al criterion system. Post operative complications in the form of nonunion in 3 cases (9.375%) underwent reoperation and were united. and shoulder pain noted in 3 patients (9.375%). **CONCLUSION:** The interlocking nail properly applied, is an excellent method for internal fixation of fractures of the shaft of the humerus alternative to plating. Most of the fracture united within 4 months with minimal complication.

**INTRODUCTION:** A fracture of the humeral shaft is a common event, and representing between 3% of all fractures. Most will heal with appropriate conservative care, although a small but consistent number will require surgery for optimal outcome. <sup>1</sup>

In the words of Sir John Charnely it is perhaps the easiest of the major long bones to treat by conservative methods.<sup>2</sup>

Most of the fractures of the shaft of the humerus treated conservatively are clinically united by about six weeks which was known as far back as the time of Hippocrates. Unfortunately not all the fractures of shaft of humerus behave in this way. Union may not be clinically firm at six weeks and if not given appropriate treatment the fracture can go into a state of established non union. The need for other methods of fracture treatment may also arise when there are compound injuries and the use of external fixator may be valuable if the soft tissue damage is extensive.

Internal fixation may be required for patients with more than one fracture in the same limb, for double fractures or where there are multiple fractures of humerus or multiple fractures elsewhere in the body and associated neuro vascular injuries.

# ORIGINAL ARTICLE

---

Internal fixation of fracture shaft of humerus allows ready access for nursing care in patients with multiple injuries and associated co morbid conditions. And also restrictive bandages and splints are avoided, early mobilization of the patients and his limbs helps to prevent fracture disease.

Intramedullary interlocking nailing has become the standard method of management for closed diaphyseal fracture of long bones. The intramedullary nailing can be inserted in reamed or unreamed fashion with its own merits and demerits. The initial unlocked design was modified to allow proximal and distal interlocking. This further improved stability and expanded the indication for the nailing to include comminuted fractures and more proximal and distal fractures. The technique is now well established in the management of fractures of long bones of the lower limb.

Intra medullary nailing offers the benefits of anatomical alignment, rigid fixation with limited soft tissue dissection, and early rehabilitation of injured limb. However, the indications for the intramedullary nailing in humeral fracture should be viewed with caution. The anatomy and function the humerus are quite different from those of the long bones of the lower extremity<sup>3</sup>

In a recent study by Changulani M, et al comparing DC plating and reamed nailing for fracture shaft humerus shows union rates were similar between the groups. Although the healing time was shorter in the intra medullary group. Shortening of the arm and restriction of shoulder movement was less in the plated group.<sup>4</sup>

**AIM OF THE STUDY:** Aim of this study is to evaluate the results of closed interlocking intramedullary nail in the fractures of shaft of humerus which is advantages to the patient and surgeons.

**MATERIALS AND METHODS:** The present study was conducted in the Department of Orthopaedic Sri Siddhartha medical college and Hospital, Tumkur during the period May 2010 to Dec 2011. In this prospective study of fracture fixation of humerus by closed interlocking nail 32 cases of fracture shaft of humerus belonging to various age groups were selected. In all the cases thorough history was taken to assess the mechanism and nature of injury and quality radiographs were taken to know the geometry of fracture. After the thorough preoperative assessment the cases were taken up for surgery after a valid written consent and consent for participating in study. The duration between the occurrence of injury and internal fixation is within two to three days in 25 cases and seven days in 7 cases.

**INCLUSION CRITERION:** Those were medically fit and willing for the study, Age more than 18 years, Cases of poly trauma, Segmental fractures, Morbid obesity, Bad soft tissue condition not allowing for plating, Osteoporosis.

**EXCLUSION CRITERION:** Those were not medically fit, Preexisting shoulder pathology, Narrow medullary canal (less than 6 mm) Permanent upper extremity weight bearer. Pathological fracture.

**INSTRUMENTS USED:**

1. General instruments for orthopaedic surgery (like surgical blades with handles, haemostatic forceps, dissection forceps, Retractors, Scissors etc.)
2. Special instruments like bone awl, jig with sleeves, guide wire, reamers 6, 7, 8 sizes, drill bit 4 mm size, mallet.

# ORIGINAL ARTICLE

---

3. Interlocking nails 6, 7, 8 sizes with locking screws.
4. Depth gauge
5. Power drill with power source
6. Screw drivers
7. Suture materials etc.

## **ANAESTHESIA:**

1. General anaesthesia or
2. Interscalene block supplemented with short general anaesthesia

## **PRE-OPERATIVE PLAN:**

1. General condition of the patient is stabilized.
2. Preoperative investigations like Hb, BT, CT, Urine - alb, Sugar, blood grouping & typing, blood sugar, blood urea, serum creatinine, ECG were done.
3. X-rays were carefully examined for fracture pattern, degree of comminution and approximate estimation of diameter and length of nail.
4. Fractures classified as per A.O classification.

**POSITION OF THE PATIENT:** We positioned the patient supine with pillow below the shoulder girdle with patient head turned to opposite side to maximize exposure of shoulder under image intensifier.

We obtained reduction of fracture by closed manipulation of fracture under image intensifier & checked both in anteroposterior & lateral views.

**APPROACH:** In all 32 cases, we used a longitudinal skin incision starting from the most lateral point of the acromion and extending distally, centered over the tip of the greater tuberosity. We are cautious not to extend the incision more than 4-5 cm in deltoid muscle in order to avoid damage to axillary nerve.

**PROCEDURE:** In all 32 cases procedure carried out by antegrade technique. Entry point was made with bone awl medial to the tip of greater tuberosity.

The position of bone awl was confirmed by image intensifier by taking anteroposterior & lateral views.

Then 2.4mm ball tipped guide wire was advanced through the entry point into the medullary cavity. Fracture site was held reduced & guide wire was advanced from proximal to distal fragment & confirmed by image intensifier by anteroposterior & lateral views. We advanced the guide wire into distal fragment until tip is 1 to 2 cm proximal to the olecranon fossa.

**MEASURING THE REQUIRED NAIL LENGTH:** For measuring required nail length we used guide wire method. In this method with distal end of guide wire 1 to 2 cm proximal to olecranon fossa, overlapped with a second guide wire under image intensifier. Extending proximally towards the humeral entry point. Nail length was obtained by subtracting overlapped length in millimeters from 500 mm.

# ORIGINAL ARTICLE

---

**REAMED TECHNIQUE:** In the present study reaming was done in ten cases. We reamed the entire humerus over the 2.4mm, ball tipped guide wire in 0.5mm increments until the desired diameter is achieved.

We used a medullary exchange tube over the 2.4mm ball tipped guide wire & exchanged with a 2.4 mm guide wire without ball tip.

**NAIL INSERTION:** We attached the selected nail to the proximal jig with conical bolt without trigger handle pointing away from the patient and proximal curvature of nail pointed laterally.

Nail was driven over the guide wire by gentle movements of the jig upto fracture site, fracture reduction was confirmed in both anteroposterior & lateral views by image intensifier & advanced gently over the fracture site to the distal fragment to avoid comminution at fracture site.

Guide wire was removed & humeral driver was attached to the jig & nail was advanced by gentle tapping until it is 1 to 2 cm proximal to olecranon fossa.

**PROXIMAL LOCKING:** Proximal locking was done with the help of jig and desired length of 4 mm fully threaded screw was inserted.

**DISTAL LOCKING:** Distal locking was done by free hand technique. We used anterior approach where small skin incision was given & biceps muscle was split by blunt dissection. Distal hole drilled anteroposterior direction and desired 4mm screw was inserted.

Both incisions were thoroughly irrigated with saline and closed in layers.

**POST-OPERATIVE MANAGEMENT:** Patients were given IV antibiotics for 3 days followed by oral antibiotics. Wound inspection was done on second post operative day. Patients were encouraged to do active movements of ipsilateral shoulder, elbow & hand from 2<sup>nd</sup> post operative day. Arm sling pouch was given to support the limb. Suture removal was done on 10<sup>th</sup> post operative day. Patients were thoroughly educated about role of physiotherapy in post operative period.

**Follow Up:** The cases were followed at regular intervals and the following details were noted.

**CLINICAL ASSESSMENT:**

- SKIN
- SWELLING
- TENDERNESS AT FRACTURE SITE
- DEFORMITY AND DISABILITY
- NEUROLOGICAL EXAMINATION

**SHOULDER:**

- ABDUCTION
- FLEXION
- EXTENSION
- INTERNAL ROTATION
- EXTERNAL ROTATION

# ORIGINAL ARTICLE

---

## ELBOW:

- FLEXION

## RADIOLOGICAL ASSESSMENT:

- FRACTURE REDUCTION
- FRACTURE UNION

In the present study 32 cases of fracture shaft humerus treated by closed reduction and fixation with the interlocking nail, the anatomical and functional results are evaluated based on the Naiman, PT Schein, A.J et al 1970 criteria.<sup>5</sup>

**RESULTS:** In our prospective study 32 cases with fracture shaft humerus were treated with intramedullary interlocking nail technique.

In this series there were 20(62.5 %) male and 12 (37.5 %) female patients. Age incidence varied from 20 years to 65 years with 15 (46.87%) cases belongs to group of 20 to 30 years, 12(37.5%) cases belongs to 30 to 50 years, 5 cases (15.625%) belongs to 50 to 65 years.

The left humerus was involved in 14 (43.75 %) cases and remaining 18 (56.25 %) cases were on the right side.

In this study 30 cases were closed fractures and 2 were type 1 compound fracture. Out of which 20 (62.5%) were located in Middle 1/3<sup>rd</sup> & followed by 6 (18.25%) at the junction of middle and distal 1/3, 3 cases (9.375%) at junction of proximal and middle 1/3, 3 were segmental fracture of humerus.

Fracture classified according to AO classification system.

Type A3 fractures were common representing 17 cases (53.125%) followed by B2 in 7cases (21.875%), B3 in 5 cases (15.625%) and 3 were C2 type.

The cause of fracture was RTA in 28 (87.5 %) cases and fall from tree in 4(12.5 %) cases.

Two patients had associated radial nerve palsy (6.25%)

Closed nailing was done and in both cases radial nerve palsy recovered.

None had intra operative complications.

Mean duration between occurrences of fracture to surgery was 2.8 days.

Mean duration of surgery was 50 minutes.

Mean follow up period was 38 weeks ranging from 16 weeks to 18 months.

Good union occurred at the end of 16 weeks in 26 cases (81.25 %), 3 (9.37 %) cases united by 24 weeks, 3 cases (9.37%) remained ununited by 24 weeks and declared non union. Then later treated them with reoperation with plate and screws with bone graft.

Most common complication being the decreased range of movement of shoulder 17 (53.125%) for that aggressive physiotherapy was given and everybody recovered except 2 cases where the proximal tip was outside the bone impinging the rotator cuff. Next complication is the delayed union and non union occurred in 3 cases constituting 9.37 %.

For delayed union bone marrow aspiration was injected at 16 week and was united. For nonunion failed with bone marrow injection implant were removed and replaced with plate and screw with bone grafting.

## ORIGINAL ARTICLE

---

**DISCUSSION:** Fractures of the shaft of humerus account for 3% of all fractures treated. Historically humeral shaft fractures have been classified by fracture location, fracture pattern, associated soft tissue injuries and quality of bone. In this study AO classification was taken to classify the fractures.

Many authors have documented the general good outcome that occurs after compression plate fixation, which is still considered the gold standard for operative treatment of acute humeral shaft fractures. Though plate fixation has given high rates of union, it involves extensive soft tissue stripping, potential injury to radial nerve and poor fixation in osteoporotic bone. Later flexible nails of many varieties were used. The advantages of intramedullary interlocking nailing are minimal surgical exposure, better biomechanical fixation, minimal disturbances of soft tissues and early mobilization of neighboring joints.

The technique of interlocking nailing represents the newer approach of the treatment of humeral fractures. Interlocking nailing also avoids complications like lack of rotational control, migration of nail and requirement of supplementary bracing. The Seidel nail was the first nail to be tested clinically.

In our study there is a male preponderance of the fracture representing 20 patients and 12 female cases which work out to a ration of almost 2:1 and the occurrence of the fracture in productive and active age group (20 to 30 years) is very high representing 15 cases constitute 46.875%. Road traffic accident being the most common cause in 28 cases constitutes 87.5 %. Most of the fractures occurred on the right side 18 cases representing 56.25%. Majority of the fractures occurred in the middle 1/3 that is 20 cases records 62.5% and 3 cases were segmental fractures.

Majority belongs to A 3 type of fracture 17 cases record 53.125%.

Pre operative radial nerve palsy was noted in 2 cases constitute 6.25% compared to study by connolly et al<sup>6</sup> which records 26 %, both cases recovered completely.

In our study we were not encountered any post operative radial nerve injury in compare to study by M.J.G Blyth et al reporting radial nerve injury in 3 of 51 cases of antegrade nailing.<sup>7</sup>

All these fractures were fixed using a humeral nail of sizes 6, 7, 8 mm diameter and of appropriate length calculated intraoperatively.

In 7 patients the operated limb was immobilized for two days and active assisted shoulder mobilization was started from 3<sup>rd</sup> postoperative day. In 3 patients mobilization of the shoulder was delayed due to associated injuries. We followed up 30 patients for a minimum of 7 months postoperatively and maximum upto 18 months and two cases followed up for only 16 weeks.

Radiological union was defined as the presence of bridging callus of the cortices in two orthogonal views. Delayed union was defined as failure of fracture union to occur by 4 months. Non union was defined as failure of fracture union by six months.

Out of 32 cases 26 cases were united 3 to 4 months constitute 81.25% comparable to M. Ajmal et al<sup>8</sup> and Cox M.A., et al<sup>9</sup> studies.

Three cases were delayed union records 9.37%. Overall union achieved in 29 cases records 90.625% compared to M. Ajmal et al<sup>8</sup> and Cox M.A., et al<sup>9</sup> studies which shows 81% and 87.9% respectively.

Non union occurred in 3 cases constitute 9.37% comparable to M. Ajmal et al<sup>8</sup> and Cox M.A., et al<sup>9</sup> study which shows 19% and 12.1% respectively.

Non unions in our study also can be compared with standard et al<sup>10</sup> study shows non union in 2 out of 42 cases of humerus nailing.



# ORIGINAL ARTICLE

---

Non union in our study also comparable to study by Bhandari M et al <sup>11</sup> which shows 11% of non union (8/73). None of the cases had splintering of at the fracture site during nail insertion into distal fragment.

In our study 3 cases undergone reoperation constitute 9.125% comparable with Bhandari et al <sup>11</sup> study which shows 18%. Shoulder pain occurred in 3(9.125%) cases were compared with study by Bhandari M et al <sup>11</sup> record 21%.

**Functional outcome:** The main concerns in antegrade intramedullary interlocking nailing of humeral shaft fractures are with shoulder stiffness. Previous reports have implicated injury to the rotator cuff, disruption of the articular cartilage or adhesive capsulitis as a result of antegrade entry. In the antegrade approach, it is essential to ensure that both the nail and proximal locking screws are deep to the cortex to reduce impingement.

All of the 29 cases had good to excellent functional rating. In 3 non union cases there was mild restriction of range of movements of shoulder because nail was protruding into the rotator cuff.

**Complications:** None in this series had intra-operative splintering at the fracture site while passing the nail into the distal fragment.

In our study we were not encountered any post op radial nerve injury in compare to study by M.J.G.Blyth et al reporting radial nerve injury in 3 of 51cases of antegrade nailing. <sup>7</sup>

Bell<sup>2</sup> and Vander Griend reported 2.9% radial nerve palsy following plating of humeral shaft fractures.<sup>12</sup>

Two patients had associated injuries in the form of radial nerve palsy which were treated by interlocking nail. Patients recovered after 6 months of follow-up.

None of the cases faced post operative infection.

So our study shows that early fixation of fracture by closed reduction and internal fixation with intramedullary interlocking nail had resulted in early fracture union and early return to the functional and occupational activities. The study also coincides with results of M. Ajmal et al study and Cox M.A.et al study that interlocking nail is beneficial to the patients with fracture shaft of humerus as it results in early return to functionability with near normal union.

**SUMMARY:** In our prospective study 32 cases with fracture shaft humerus were treated with intramedullary interlocking nail technique.

Follow up was possible for the above all 32 cases, 29 patients showed good clinical and radiological fracture union. Post-operatively 3 cases have shown Non union.

This study proves beyond doubt that closed reduction and internal fixation of fracture shaft of humerus by interlocking nail has distinct advantages of early perfect fracture stabilization and early post-operative mobilization of shoulder and elbow joints leading to early normal function of the upper limbs, provided the correct technique and principles of internal fixation are followed.

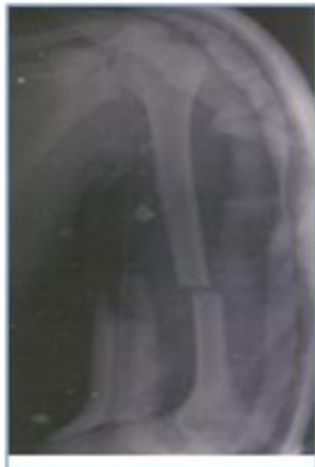## BABILIOGRAPHY:

1. Rockwood. C.A. & Green O.P.: Fractures in Adults 6<sup>th</sup> edition.2006 PP.1117-1160/-
2. Campbell, Textbook of operative Orthopaedics 12<sup>th</sup> edition. 2004. Pp.2852.
3. D D Tanna: interlocking Nailing, 2 edition.2004.pp.135

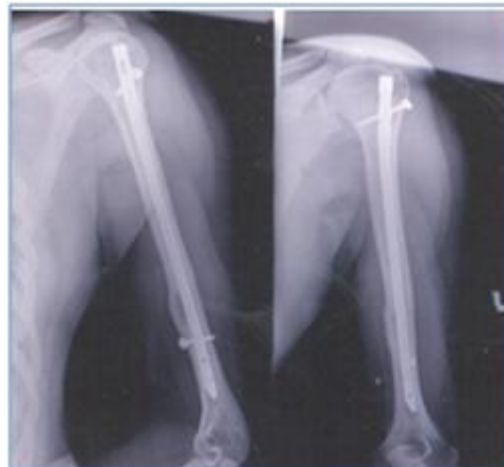## ORIGINAL ARTICLE

---

4. Changulani M, Jain UK, Keswani T. Comparison of use of humerus intramedullary nail and dynamic compression plate for the management of displaced fracture of the humerus: a randomized control study, *Int Ortjop.* 2007; 31 (3): 391-395.
5. Naiman. P.T., Schein.A. J. and Siffert R.S: Use of ASIF Compression plates in selected shaft fractures of the upper extremity A preliminary report. *Clin. Orthop.* 71:7-216-1970.
6. Connolly S, Nair R, Waddell JP, et al. Immediate plate osteosynthesis of open fractures of the humeral shaft. Proceedings of the 55th Canadian Orthopaedic Association Annual Meeting. Edmonton, Alberta; June 3-6, 2000.
7. M.J.G.Blyth, C.M.B, Macleod, D.K.Asante, A.W.G.Kinninmonth, Iatrogenic nerve injury with the Russel – Taylor humeral nail. *Injury, Int. J. care Injured* 34 (2003) 227-228.
8. M.Ajmal, M.O Sullivan, J.McCabe, W.Curtin, Antegrade locked intramedullary nailing in humeral shaft fractures: *international Journal of the Care of the injured*: May 2001.
9. Cox M.A: Dolan, M; synnott, K; McElwain, J.P.; closed interlocking nailing of humeral shaft fractures with the Russell-Taylor Nail: *JBJS*: June/July 2000.
10. Stannard JP, Harris HW, McGwin G Jr, et al ; retrograde nailing of humeral shaft fracture: a biomechanical study of its effect on the strength of the distal humerus, *J Orthop Trauma* 14:101, 2000.
11. Bhandari M, Devereaux PJ, McKnee MD, et al: compressive plating versus intramedullary nailing of humeral shaft fracture- a meta-analysis, *Acta Orthop* 77; 279, 2006.
12. Bell MJ, Beauchamp CG, Kellam JK, McMurthy Ry. The results of plating Humeral shaft Fractures in Patients with Multiple Injuries. *JBJS Br.*1985; 67; 293-296.

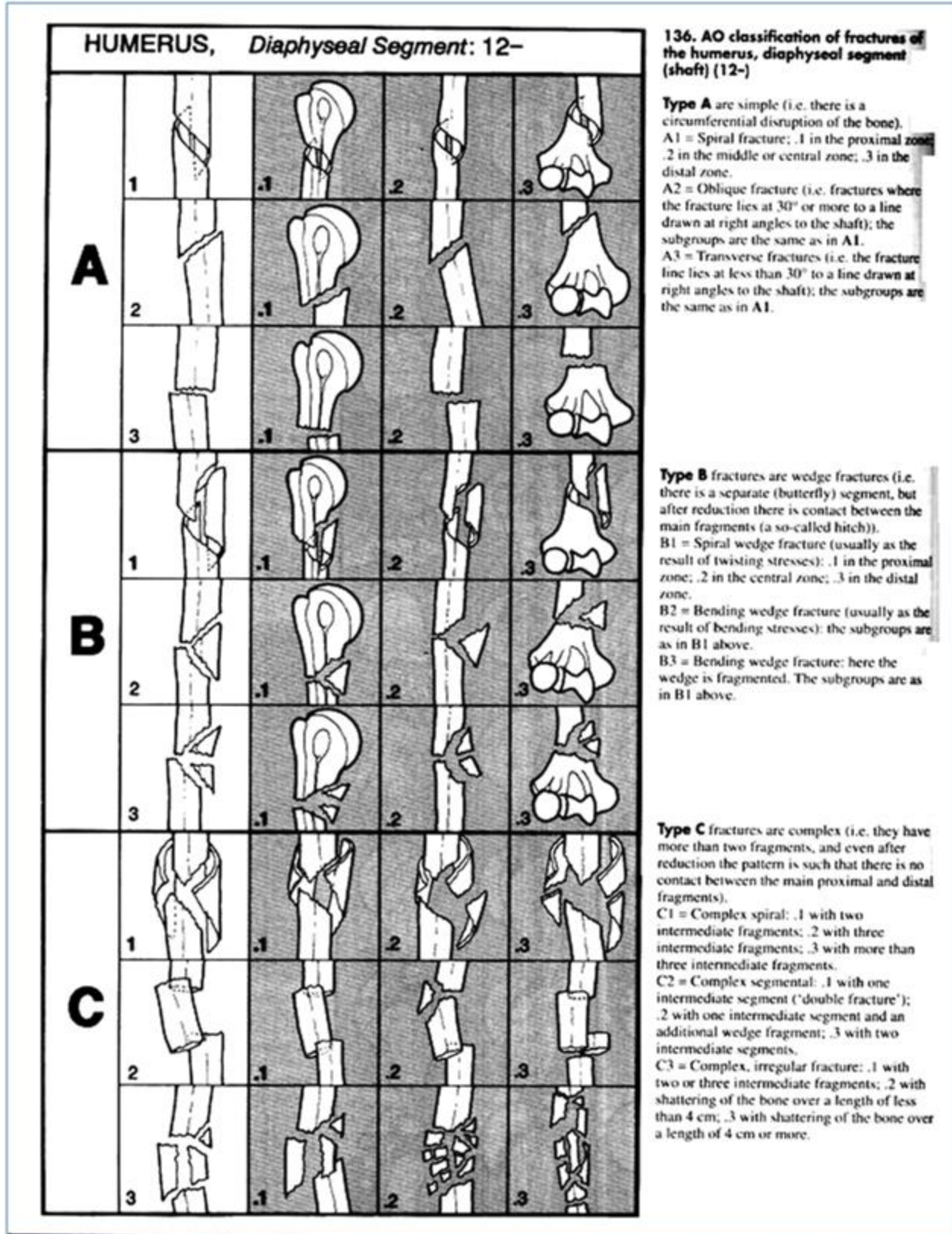


PRE OP FRACTURE SHAFT HUMERUS



5 MONTHS AFTER THE SURGERY





AO CLASSIFICATION OF FRACTURE SHAFT HUMERUS

# ORIGINAL ARTICLE

---

**AUTHORS:**

1. Muralidhar B.M.
2. Mahendranath Reddy D.

**PARTICULARS OF CONTRIBUTORS:**

1. Assistant Professor, Department of Orthopaedics, Konaseema Institute of Medical Science, Amalapuram, East Godavari District, Andhra Pradesh, India.
2. Senior Resident, Department of Orthopaedics, Konaseema Institute of Medical Science, Amalapuram, East Godavari District, Andhra Pradesh, India.

**NAME ADDRESS EMAIL ID OF THE CORRESPONDING AUTHOR:**

Dr. Muralidhar B.M.,  
Assistant Professor,  
Department of Orthopaedics,  
Konaseema Institute of Medical Science,  
Amalapuram, East Godavari District,  
Andhra Pradesh, India – 533201.  
Email – itsmemrmurali@gmail.com

Date of Submission: 28/09/2013.  
Date of Peer Review: 29/09/2013.  
Date of Acceptance: 04/10/2013.  
Date of Publishing: 08/10/2013