

## MANAGEMENT OF HUGE ENCEPHALOCELE

Rajeev Kumar<sup>1</sup>, Amit Gupta<sup>2</sup>, Mohd. Ehsan Rashidi<sup>3</sup>

<sup>1</sup>Associate Professor, Department of Anesthesiology, Rama Medical College.

<sup>2</sup>Assistant Professor, Department of Neurosurgery, GSVM Medical College.

<sup>3</sup>Assistant Professor, Department of Plastic Surgery, Rama Medical College.

---

### ABSTRACT

Among all neural tube defects, encephalocele incidents are 1 in 5000 live births.<sup>(1)</sup> Newborn with encephalocele may be associated with other congenital malformations. Encephalocele patient's management pose many challenge to neurosurgeon due to other associated anomalies that may present like ventriculocele, Dandy Walker and Arnold-Chiari malformation, and difficult positioning airway management to anaesthesiologist. We discuss a case of huge encephalocele and its management.

### KEYWORDS

Encephalocele, Difficult Intubation, Posterior Cranial Fossa.

---

**HOW TO CITE THIS ARTICLE:** Rajeev Kumar, Amit Gupta, Mohd. Ehsan Rashidi. "Management of Huge Encephalocele." Journal of Evolution of Medical and Dental Sciences 2015; Vol. 4, Issue 96, November 30; Page: 16195-16198, DOI: 10.14260/jemds/2015/2379

---

### INTRODUCTION

Neural tube defects constitute a major public health problem in terms of mortality, morbidity, social cost and human suffering. Most infants are stillborn and live born infants survive for a short period of time, usually a few days.<sup>(2)</sup>

Encephalocele is a herniation of intracranial contents through a skull defects. Encephalocele are classified by their contents and location. If it contains only leptomeninges it is called meningoceles, whereas encephaloceles also contain small part of brain and a ventriculocele is an encephalocele in which the herniated brain contents also contain portion of ventricle.<sup>(3)</sup>

Occipital encephalocele are usually more common (75%) than frontal (25%).<sup>(4)</sup>

### CASE REPORT

A male infant of 3 months old was admitted in Neurosurgery Outpatient Department referred from Paediatric Department. The baby was born through Lower Segment Caesarean Section (LSCS). There was a history of obstructed labor during birth was observed. He was the product of an uneventful 39-week pregnancy in a 27-year-old primipara (Figure 1 at birth). The baby had no prenatal diagnosis and cried immediately after birth. There is no history of any congenital anomaly in the family of mother and father, no history of consanguinity.

There was a huge mass at the occipital region since birth, which was covered by normal pink-purple skin. Local examination revealed that swelling is consisting of three cysts like structure joined together. Total circumference of the total swelling is about 69cm. The consistency of the swelling was soft. Transillumination test was positive. No bruit or murmur heard over the surface of the swelling. Anterior and posterior fontanelle were opened.

The infant used to lie in lateral position, because of the swelling. Neck remains in flexion and extension is not possible in supine position.

No facial, maxillary and mandibular defects were present. No other congenital anomaly was present. Weight of infant was 5.9kg.

On neurological examination, the patient was conscious and accepting breast feeding normally. There was no limb weakness. Pupils were normal and reacting to light.

Magnetic Resonance Imaging (MRI) of brain showed a giant encephalocele at the occipital region (Figure 2), other investigation was within normal limits and no other congenital anomaly was detected in the infant.

Infant was posted for excision of encephalocele sac under general anesthesia.

Because of large sac on occipital region, difficult ventilation and difficult intubation situation was anticipated. Intubation was done by placing the baby on piles of drape to make height of the baby trunk similar to the head level. Encephalocele sac was supported by towel under the head. During operation patient was positioned in prone position (Figure 3). The lesion was painted and draped as usual. Transverse eclipse incision was made near the base of lesion, so as to enable closing it without undue tension; then incision was deepened until dura is seen which is traced up to the bony defect.

Sac was then opened, CSF was drained and a sample was sent for microbiological examination and culture. Neural tissue was preserved and the sac was reduced in size sufficient enough to accommodate the healthy looking brain tissue. Dura was repaired meticulously to get water tight closer by continuous monofilament absorbable suture. Meticulous hemostasis was achieved carefully; a small suction drain was put; subcutaneous tissue was approximated with interrupted absorbable suture and the skin was closed with interrupted sutures. In the postoperative periods, patient was monitored for rise in intracranial pressure and CSF fistula. There was evidence of persistent small cystic collection in the occipital region with mild dilatation of ventricles. Child remained well in followup and monitored for fluid collection and the requirement for a VP shunt. (Figure 4).

---

*Financial or Other, Competing Interest: None.*

*Submission 06-11-2015, Peer Review 07-11-2015,*

*Acceptance 23-11-2015, Published 30-11-2015.*

*Corresponding Author:*

*Dr. Rajeev Kumar,*

*C 17, New Azad Nagar,*

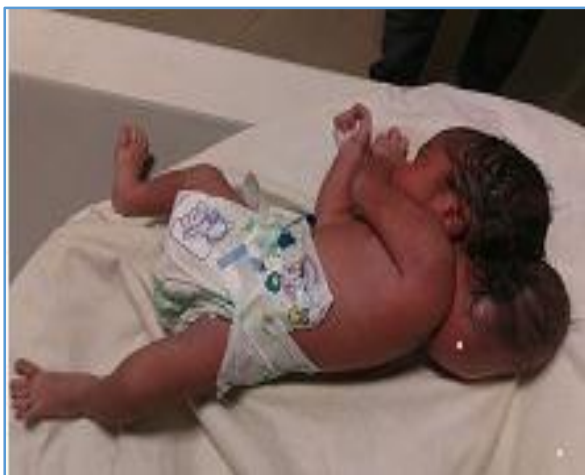*Kalyanpur, Kanpur,*

*Uttar Pradesh.*

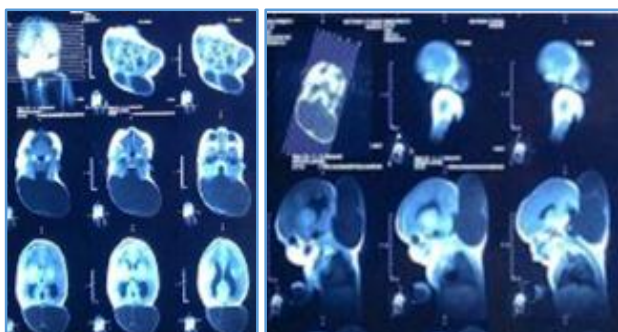
*E-mail: rajeevgoley@gmail.com*

*DOI: 10.14260/jemds/2015/2379*

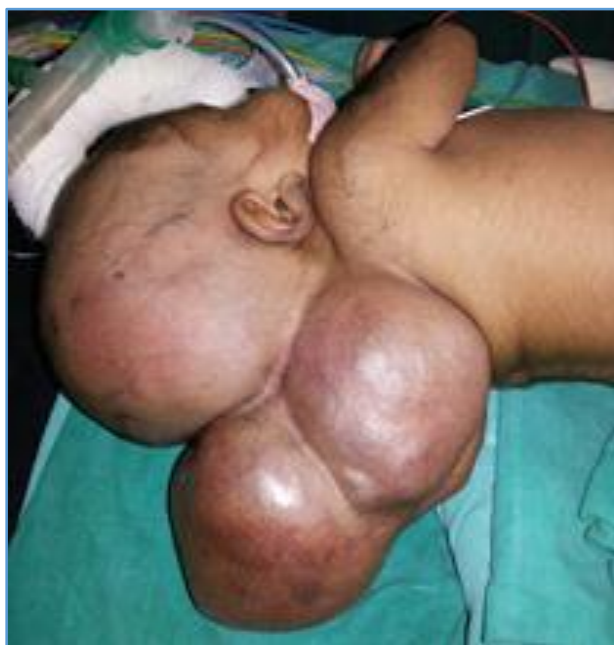---



**Fig. 1: (Infant at Birth)**



**Fig. 2: MRI**



**Fig. 3: After Intubation**



**Fig. 4: Followup**

**DISCUSSION**

Encephalocele are the result of a congenital cranial defect that allows intracranial contents to herniate. Primary arrest of bone development and adhesions from developing brain dura and skin further reduces bone development. Then increased intracranial pressure pushes the brain through the developing cranial base. Encephaloceles account for 10% to 20% of all craniospinal dysraphisms. Encephaloceles are classified by their anatomical location, vast majority (75%) located in the posterior cranial fossa. There is no known genetic mutation present to explain the lesion and higher incidence is in Southeast Asia (1:6000 live births), of that about 70% occur in females.<sup>(5)</sup> Prenatal diagnosis of encephaloceles is possible through ultrasonography, Maternal Serum Alfa-Fetoprotein (MSAFP) and amniocentesis.<sup>(6)</sup>

In the presence of an encephalocele, there is a 60%-80% risk of associated structural abnormality both intra- and extracranially in prenatal series and a 50% risk in postnatal studies. Large occipital encephaloceles have been found associated with optical, choroidal and retinal dysplasia; severe ocular alterations; central nervous system anomalies; epilepsy; dermoid cyst; tectocerebellar dysraphia and necrosis.<sup>(7)</sup> More than 60% of these patients may also develop hydrocephalus requiring a ventriculoperitoneal shunt.<sup>(8)</sup> Survival rates and morbidity of encephaloceles vary most strongly with anatomical sites being 100% and 50% respectively in the case of anterior defects and 55% and 83% respectively in the case of posterior defects.<sup>(9)</sup>

These lesions are usually covered either with normal skin, dysplastic skin or a thin distorted meningeal membrane. The large sized swellings may have significant brain herniation, abnormality of the underlying brain, microcephaly and ventriculomegaly. Such patients usually have poor prognosis.<sup>(10)</sup> Encephaloceles with a small amount of dysfunctional tissue are conventionally treated by excision of the herniated brain tissue and repair of the dural defect. The surgical management of children with large defect along with herniation of a considerable proportion of brain matter into the sac at times can be extremely difficult. In such cases, preservation of the herniated brain parenchyma can be accompanied by expansile cranioplasty.<sup>(11)</sup>

Patients with giant encephalocele and large amount of brain tissue in the sac usually die either shortly after birth or as a result of operation. A microcephalic child with neurological deficit and a sac containing cerebrum, cerebellum and brain stem structures carry a poor prognosis. In such patients it is generally impossible to foretell whether the infant will die quickly or will continue to live for many months or years, as size of the encephalocele itself is not a guide to prognosis. Ultimate result depends on the amount of normal brain tissue left inside the skull after the operation.

**REFERENCES**

1. Nevin NC, Weatherall JAC (1983) Illustrated guide to malformation of the central nervous system at birth. Edinburgh: Commission of the European Communities. Churchill Livingstone.
2. Shokunbi T, Adeloje A, Olumide A. Occipital encephaloceles in 57 Nigerian children: a retrospective analysis. *Childs Nerv Syst* 1990;6:99-102.
3. Agrawal D, Mahapatra AK. Giant occipital encephalocele with microcephaly and micrognathia. *Pediatr Neurosurg* 2004;40:205-6.
4. Morika M, Marabayashi T, Massamitsu T. Basal encephaloceles with morning glory syndrome and progressive hormonal and visual disturbances. Case report and review of literature. *Brain Dev.* 1995;17:196-201.
5. Sargent LA, Seyfer AT, Gunby En. Nasal encephalocele. Definite one stage reconstruction. *J Neurosurg* 1988;68:571-5.
6. Simpson DA, David DJ, White J. Cephaloceles: Treatment, outcome and antenatal diagnosis. *Neurosurgery* 1984;15:14-21.
7. Chatterjee MS, Bondoc B, Adhate A. Prenatal diagnosis of occipital encephalocele. *Am J Obstet Gynecol* 1985;153:646-7.
8. Mayer U, Klinger M, Rott HD. A rare form of optical, choroidal and retinal dysplasia combined with an occipital encephalocele. *Graefes Arch Clin Exp Ophthalmol* 1982;219:72-5.
9. Caviness VS, Jr., Evarard P. Occipital encephalocele: A pathologic and anatomic analysis. *Acta Neuropathol.* 1975;32:245-55.
10. Hoving E, Blaser S, Kelly E, Rutka JT. Anatomical and embryological considerations in the repair of a large vertex cephalocele. *J Neurosurg* 1999;90:537-41.
11. Lorber J, Schofield JK. The prognosis of occipital encephalocele. *Z Kinderchir Grenzgeb* 1979;28:347-51.