

**TERATOGENIC EFFECTS OF SILVER NANOPARTICLES: GROSS ANOMALIES**Jyoti Prakash Pani<sup>1</sup>, Rajniti Prasad<sup>2</sup>, Deepika Joshi<sup>3</sup>, Royana Singh<sup>4</sup>**HOW TO CITE THIS ARTICLE:**

Jyoti Prakash Pani, Rajniti Prasad, Deepika Joshi, Royana Singh. "Teratogenic Effects of Silver Nanoparticles: Gross Anomalies". Journal of Evolution of Medical and Dental Sciences 2015; Vol. 4, Issue 62, August 03; Page: 10778-10789, DOI: 10.14260/jemds/2015/1556

**ABSTRACT: BACKGROUND:** Prenatal exposure of AgNPs can induces devastative and detrimental effect in the organogenesis period of the developing embryos and fetuses. Organogenesis period is highly condemnatory and persuadable. Any injury to embryo during this period leads to dysmorphogenesis or even death **AIM:** The present study means to evaluate the gross anomalies on developing foetus subsequent to silver nanoparticle ingestion during the gestational period. **MATERIAL & METHOD:** Random selections of pregnant Swiss albino mice were selected. AgNPs, of 20-100nm size range, were administered to pregnant mice by repeated oral gavages at concentrations of 0.5, 1, 5, 10, 15 & 20mg/kg/day during 4-17 gestational day. All dams were subjected to exteriorization on GD 18. The fetuses were evaluated for body malformation effects. **RESULTS:** Repeated oral gavages treatment with AgNPs at a concentration of 0.5mg/kg/day caused resorption (4.61%) and intra uterine growth retardation (7.69%) with no gross morphology alteration. 1 mg/kg/day caused resorption (9.23%) and intra uterine growth retardation (10.76%) with a rare case of haemorrhagic conception (1.53%), 5mg/kg/day caused limb malformation (7.01%) resorption (17.54%) and intra uterine growth retardation (17.54%), closed type Neural tube deformity (5.26%), 10mg/kg/day caused 20% of limb malformation including Amelia, foot and tail vein hemorrhages and simple tail vein haemorrhage (3.50% each), resorption (22.80%), intra uterine growth retardation (29.82%), 15mg/kg/day caused severe hemorrhage within the entire body (22.80%), limb anomaly including syndactyly and oligodactyly (8.77%), resorption (42.10%), intra uterine growth retardation (45.61%), 20mg/kg/day caused Omphalocele (3.27%), Bidiscoidal placental anomaly (9.83%), resorption (29.50%) and intra uterine growth retardation (62.29%). **CONCLUSION:** The results show that a repeated oral dose of AgNPs during pregnancy caused fetal body dysmorphogenesis which is dose dependant.

**KEYWORDS:** Silver nanoparticle colloidal solution, Fetus body malformation, Dynamic light scattering.

**INTRODUCTION:** Nanosilver toxicity on embryo fetus development is growing as a vital sub stream of nanotechnology and this area of research study is dividing and redividing into multiple growing branches without any end of further process.<sup>(1)</sup> Silver nanoparticles are not safe, but silver nanoparticles are not dangerous, they only act as a dangerous agent in higher dose and high concentration when injected repeatedly through various routes especially through oral exposure.<sup>(2)</sup> Nanosilver toxicity is defined as the study of deleterious relation of silver nanoparticles with embryo-fetus developmental systems. Near about 10% of human anatomical congenital anomalies result from the troublesome actions of drugs, viruses and environmental factors.<sup>(3)</sup> Dysmorphic defects traceable by any drug calculated about 1% of known cause.<sup>(4)</sup> Nanosilver has been used since ancient times for jewelry, utensils, monetary currency, dental alloy, photography, explosives etc.<sup>(5)</sup> Many of the industrial silver compounds, including nitrate, chloride, bromide, acetate, oxide, sulfate and cyanide <sup>(6)</sup>released into the environment from various sources and interfere with embryo-fetus development

in pregnant mother.<sup>(7)</sup> Nanosilver has been reported to be among the most toxic agents in some studies which induced congenital malformation in fetuses.<sup>(8-10)</sup> The environmental contamination due to industrial use and exposure allows this element absorbed into the body through the lungs, gastrointestinal tract, mucus membranes of the urinogenital tract, and through the skin;<sup>(11)</sup> it is also found in myocardium, mucous membrane, kidney, liver, and many areas of the brain,<sup>(12)</sup> and produces deficits in learning and memory. Silver also binds itself to high-molecular-weight proteins and the metallothionein in fractions,<sup>(13)</sup> the silver penetrates the blood-brain barrier and accumulates into large neurons in the brain stem and spinal cord.<sup>(14)</sup>

The present study was undertaken to determine the dysmorphogenesis effects of AgNPs on fetal development after maternal exposure on gestational days (GD) 4–15 in mice.

**MATERIAL& METHODS:** Male and female Swiss albino mice with an average weight of 20-35gms and average age of 45days from different breeding colony were chosen randomly for conduction of this study from animal house, Department of Anatomy, Institute of Medical Sciences, Banaras Hindu University. Animals were housed individually in plastic cages with steel toppings (1:1 male female ratio) with early maintenance of 12hrs day and night cycle in the air conditioned animal house, the temperature was maintained around 20-25°C with a minimum range of relative humidity of 55±5%. Mice were fed on Hindustan liver diet pellets and tap water libitum with appropriate bedding made up of dry husk inside the plastic cage. Vaginal plugged female dams were considered as day “zero” of pregnancy. The pregnant female mice were weighted from day 0 to day 18 of gestational age and were kept individually in separate cages till day 18<sup>th</sup> of G.A for exteriorization by deep ether/chloroform anesthesia and collection of fetuses. Silver nanoparticle colloidal solution prepared by using (magnetic stirring and cooling method).<sup>(15)</sup> The mothers were administered with silver nanoparticle colloidal solution with adding 1.5 M NaCl solution as vehicle, 1 drop of 0.33% poly vinyl pyrrolidone solution as a deaggregator agent and 0.002M Sodium Borohydride solution as a stabilizer agent, by oral gavages. The study was carried out in strict conformity with laws and regulation for animal experiment after getting approval from central animal ethical committee of the institute (No. Dean/ 2014/ CAEC/ 6). All Animals were treated with utmost humane care.

Characterization of silver nanoparticles.

Freshly prepared bigger size AgNPs colloidal solution was characterized by Dynamic Light Scattering.<sup>(16)</sup>

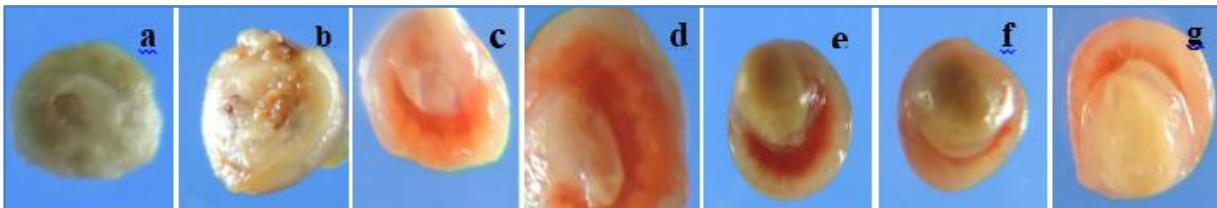
Dissection schedule, body malformation observation, photography and percentage evaluation All dams were subjected to exteriorization on GD 18. The fetuses were evaluated for signs of body malformation effects under dissecting microscope. 6 dams were taken to conduct experiment from each group. Each dam delivered almost 7 to 13 fetuses and all the fetuses were evaluated. Optical zoom 18.1 Mega pixel CMOS 3.2 vary-angle camera was used for photography. At the end percentage evaluated from each group with overall percentages compared between the groups. Overall percentage of live fetuses, overall percentage of dead fetuses and overall mean weight of live fetuses were calculated from each group.

**RESULT: OBSERVATION:** All foetuses exposed to 0.5, 1, 5, 10, 15 & 20mg/kg/day AgNPs group were evaluated for signs of body malformation and were compared with all foetuses of anionic double distilled water treated sham control group. Out of 65foetuses from 0.5mg/kg/day AgNPs treated group 3 foetuses were observed resorption, 5 were observed IUGR. Out of 65foetuses from

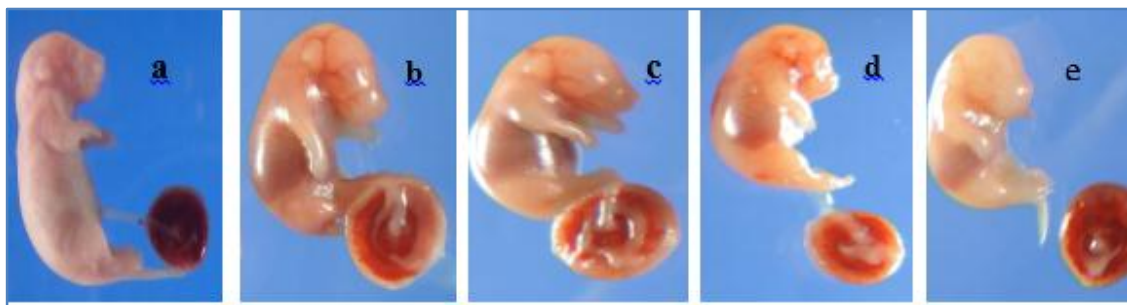
## ORIGINAL ARTICLE

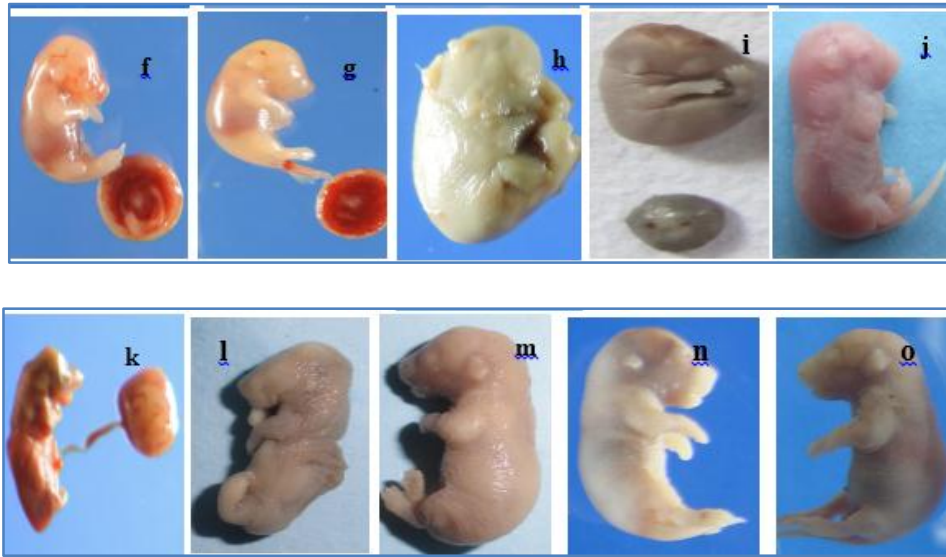
1mg/kg/day AgNPs treated group 6 fetuses were observed resorption, 7 were observed I.U.G.R., 1 undeveloped foetus with full product of conception including amniotic membrane and placenta observed severe haemorrhage within the body. (Fig. 3a & b) Out of 57 fetuses from 5mg/kg/day AgNPs treated group 4 fetuses were observed limb malformation, proboscis with phocomelia. (Fig.3c,d&e), 3 were observed closed type neural tube defect (Fig. 3h), 10 were observed resorption and 10 were observed IUGR, Out 57 fetuses from 10mg/kg/day AgNPs treated group 2 fetuses were observed Amelia (Fig. 3f), 2 were observed foot and tail vein haemorrhage (Fig. 3i), 2 were observed simple tail vein haemorrhage (Fig. 3j), 13 were observed resorption and 17 were observed I.U.G.R. Out of 57 fetuses from 15mg/kg/day AgNPs treated group 5 fetuses were observed limb anomaly like syndactyly, oligodactyly with extended limb anomaly (Fig. 3g), 13 fetuses were observed severe IUGR and external haemorrhages. (Fig. 3k), 24 fetuses were observed resorption, 26 fetuses were observed IUGR. Out of 61 fetuses from 20mg/kg/day AgNPs treated group 2 fetuses were observed Omphalocele anomaly (Fig. 3l), 6 were observed Bidiscoidal placental anomaly. (Fig. 3m). 8 were observed resorption and 38 were observed I.U.G.R. Common sign and symptoms of body malformations of fetuses like resorption, IUGR and haemorrhagic consequences were seen in all treated dams fetuses consistently but the intensity of such was found increased as the dose increases.

**Fig. 1:** showing a-resorption from control group, b-resorption from 0.5mg AgNPs treated group, c-resorption from 1mg AgNPs treated group, d-resorption from 5mg AgNPs treated group, e-resorption from 10mg AgNPs treated group, f-resorption from 15mg AgNPs treated group, g-resorption from 20mg AgNPs treated group.

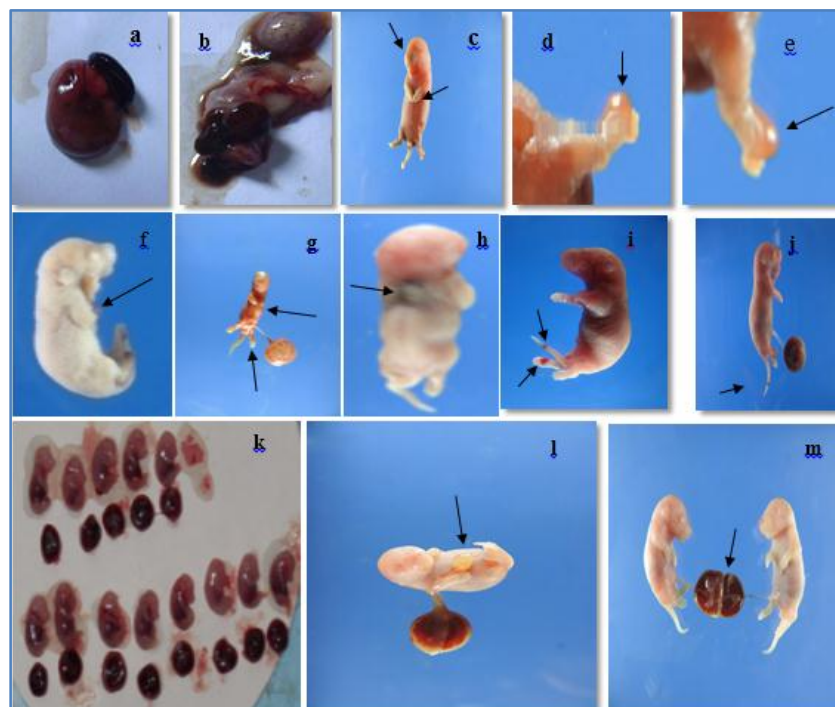


**Fig. 2:** Showing a- I.U.G.R from control group, b- I.U.G.R from 0.5mg AgNPs treated group, c- I.U.G.R from 1mg AgNPs treated group, d-I.U.G.R from 5mg AgNPs treated group, e- I.U.G.R from 10mg AgNPs treated group, f- I.U.G.R from 15mg AgNPs treated group, g- I.U.G.R from 20mg AgNPs treated group, h, l, j, k, l, m, n, o- I.U.G.R from 20mg AgNPs treated group.





**Fig. 3:** Showing a- Haemorrhagic conception from 1 mg AgNPs treated group, b- Haemorrhagic conception from 1mg AgNPs treated group, c- Phocomelia and proboscis foetus from 5mg AgNPs treated group, d, e – Dissected lower limb showing syndactyly limb anomaly of phocomelia fetus, f- Amelia foetus from 10mg AgNPs treated group, g- I.U.G.R with syndactyly, oligodactyly with extended limb anomaly from 10mg AgNPs treated group, h-Close type neural tube deformity from 5 mg AgNPs treated group, i- Foot and tail vein haemorrhages from 10mg AgNPs treated group, j- Simple tail vein haemorrhages from 10mg AgNPs treated group k- Severe I.U.G.R with external haemorrhages within the body from 15 mg AgNPs treated group, l- Omphalocele foetus from 20 mg AgNPs treated group, m-Bidiscoidal placental anomaly from 20mg AgNPs treated group.





## ORIGINAL ARTICLE

Summary of calculated percentages of fetuses individual body malformations from control and treated groups.

Groups	Type of fetus body malformations (Total no. of fetuses)	Percentages
Control group	a) Resorption (2)	3.70%
	b) I.U.G.R. (3)	5.55%
0.5mg/kg/day AgNPs Tr. Gr.	a) Resorption (3)	4.61%
	b) I.U.G.R. (5)	7.69%
1mg/kg/day AgNPs Tr. Gr.	a) Resorption (6)	9.23%
	b) I.U.G.R. (7)	10.76%
	c) Severe hemorrhage within body (1)	1.53%
5mg/kg/day AgNPs Tr. Gr.	a) Limb malformation& proboscis with IUGR (4)	7.01%
	b) Closed type NTD with IUGR (3)	5.26%
	c) Resorption (10)	17.54%
	d) IUGR (10)	17.54%
10mg/kg/day AgNPs Tr. Gr.	a) a)Amelia with I.U.G.R. (2)	3.50%
	b) b)Foot and tail vein hemorrhages with I.U.G.R. (2)	3.50%
	c) c)Simple tail vein hemorrhages with I.U.G.R. (2)	3.50%
	d) Resorption (13)	22.80%
	e) I.U.G.R. (17)	29.82%
15mg/kg/day AgNPs Tr. Gr.	a) Severe IUGR with external hemorrhages (13)	22.80%
	b) Syndactyly, oligodactyly, extended limb anomalies with IUGR (5)	8.77%
	c) Resorption (24)	42.10%
	d) I.U.G.R. (26)	45.61%
20mg/kg/day AgNPs Tr. Gr.	a) Omphalocele with IUGR (2)	3.27%
	b) Bidiscoidal placental anomalies with IUGR(6)	9.83%
	c) Resorption (18)	29.50%
	d) I.U.G.R. (38)	62.29%

Table 1

**Table 1:** Summarizes total number of dams, total number of fetuses, type of fetus body malformations and their percentages from different groups.

Individual calculated percentages of fetal body malformations summarize in Table 2 showed that the intensity of such malformations increased with increase in dose of silver nanoparticles through repeated maternal oral gavages exposure whereas the percentage of normal decrease.

## ORIGINAL ARTICLE

Sl. No.	Dose	No. of mother	Total no. of fetuses	No. of live fetuses
1	Control	6	54	52 (96.29%)
2	0.5mg tr.gr.	6	65	62 (95.38%)
3	1mg tr.gr.	6	65	59 (90.76%)
4	5mg tr.gr.	6	57	47 (82.45%)
5	10mg tr.gr.	6	57	44 (77.19%)
6	15mg tr.gr.	6	57	33 (57.89%)
7	20mg tr.gr.	6	61	43 (70.49%)

**Table 2**

**Table 2:** Summarizes dose, total number of mothers, total number of foetuses, number of absorption, number of live foetuses.

Malformations											
Resorption	IU GR	Severe Haemo. Within body	L.M. with phocomelia	CN TD	Ame lia	FT VH	TVH	S.D. O.D. E.A	S.E.H. W.B	Omp ha.	B.D. P.A.
2	3	-	-	-	-	-	-	-	-	-	-
3	5	-	-	-	-	-	-	-	-	-	-
6	7	1	-	-	-	-	-	-	-	-	-
10	10	-	4	3	-	-	-	-	-	-	-
13	17	-	-	-	2	2	2	-	-	-	-
24	26	-	-	-	-	-	-	5	13	-	-
18	38	-	-	-	-	-	-	-	-	2	6

**Table 3**

**Table 3:** Summarizes the numbers of malformations from different groups.

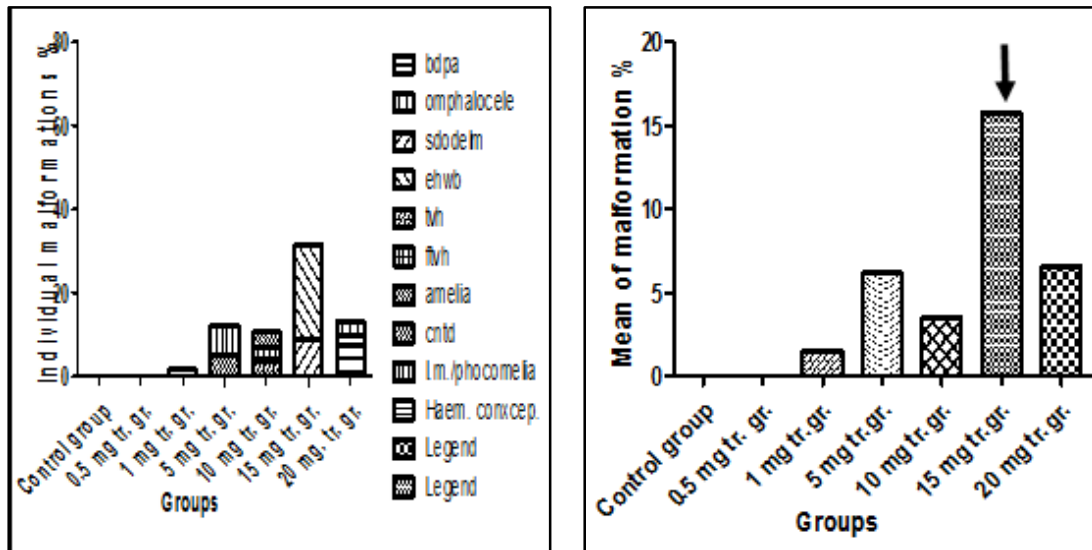
F.N.-\*IUGR-Intra Uterine Growth Retardation/\*L. M.-Limb malformation/\*CNTD-Close type neural tube defect/\*FTVH-Foot and tail vein haemorrhage/\*TVH- Tail vein haemorrhage/ \*S. D. O. D. E. L. A. Syndactyly, oligodactyly, extended limb anomaly/\*S. E. H. W. B-Severe external haemorrhages within body/\*Omp ha.-Omphalocele/\*B. D. P. A.-Bidiscoidal placental anomaly.

Number of live fetuses and number of dead fetuses of control and treated group from table 2 analysis shows the number of live fetuses' percentages decreases from control group to 20mg/kg/day treated group. Whereas the number of dead fetuses percentages increases from control group towards 20mg/kg/day group with an exceptional case of increase of percentages of dead fetuses seen in 15mg/kg/day group.

Mean percentages of various malformations.

## ORIGINAL ARTICLE

**Graph 1:** Showing mean and individual of percentages of various malformations from control and treated group fetuses.

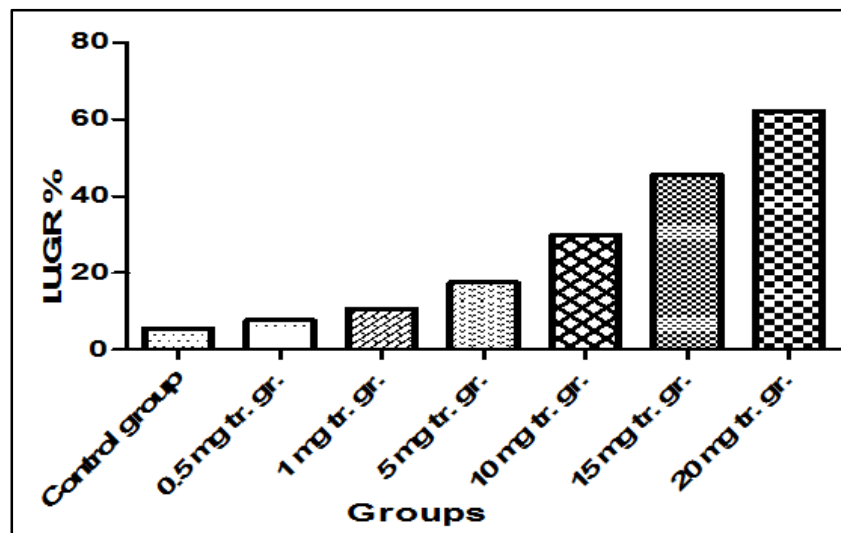


**Graph 1**

Analysis of figure 2 shows the mean percentages of various malformations progressively increases from control towards 20 mg/kg/day group with an exceptional increase in 15mg/kg/day AgNPs treated group.

Overall percentages of IUGR.

**Graph 2:** Showing percentages of IUGR from control and treated groups.



**Graph 2**

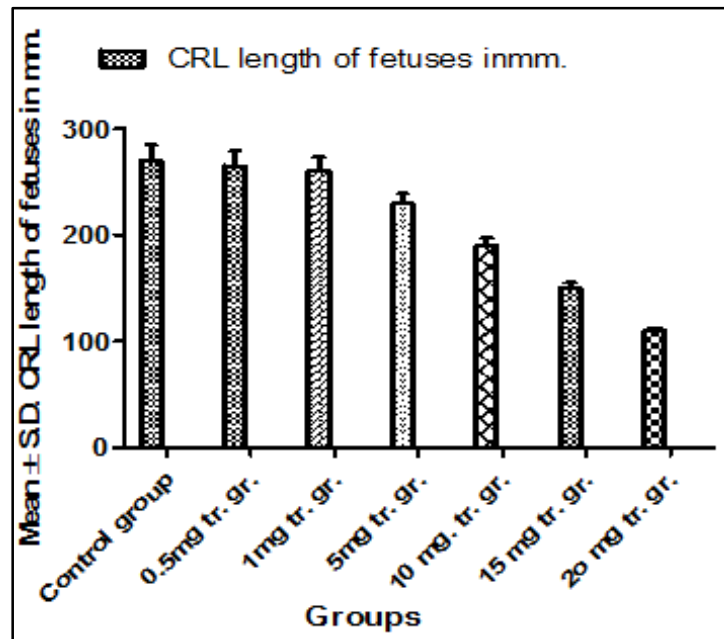
The figure 3 analysis shows percentages of IUGR progressively increases from control toward 20mg/kg/day treated group.

## ORIGINAL ARTICLE

Sl. No.	Dose	Mean±S.D. of CRL (Crown rump length in mm.)	Mean±S.D. of weight of live fetuses in gm.
1	Control	270±15.15	1.253±0.002
2	0.5mg/kg/day	265±14.12	1.203±0.002
3	1 mg/kg/day	260±13.02	1.153±0.002
4	5 mg/kg/day	230±9.02	0.792±0.001
5	10 mg/kg/day	190±7.22	0.784±0.001
6	15 mg/kg/day	150±5.02	0.732±0.001
7	20 mg/kg/day	110±3.22	0.701±0.001

Table 4

**Table 4:** Summarizes dose, mean± s.d. of crown rump length in fetuses and mean± s.d. of weight of live fetuses in gm.

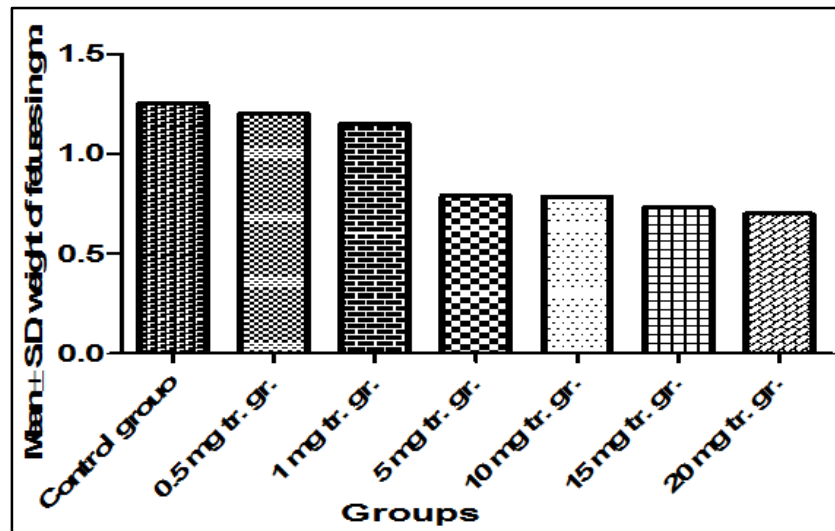


Graph 3

**Graph 3:** Showing mean± s.d. of crown rump length of fetuses from control and treated groups.

Table 3 data Figure 4 and 5 analyses shows the mean±s.d. of crown rump length and weight of live fetuses decreases progressively from control towards 20mg/kg/day group and with increase in dose.

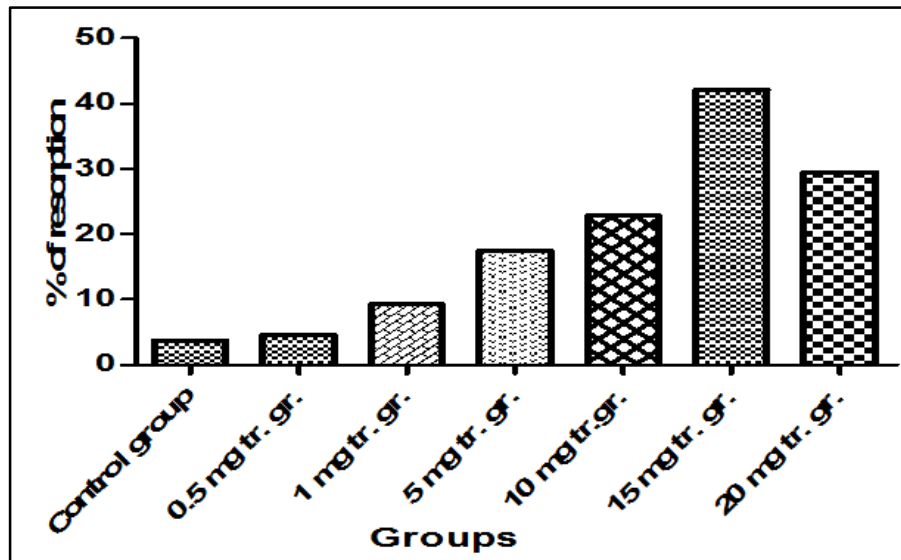




Graph 4

**Graph 4:** Showing mean  $\pm$  s.d. of weight of live fetuses from control and treated groups.

The figure 6 analysis shows percentages of resorption progressively increases from control toward 20mg/kg/day treated group.



Graph 5

**Graph. 5:** Showing percentages of Resorption from control and treated groups.

**DISCUSSION:** Silver nanoparticle ingestion causes detrimental effect on embryo fetus development. It also causes various malformations in fetuses when they grow in womb. The deleterious effects visualizes when they born after maternal exposure of AgNPs in prenatal stage. The various malformations fetus met with are limb malformations, snot mal development, virulent hemorrhages within the body, mid gut loop herniation like omphalocele, bidiscoidal placental anomaly, close type

## ORIGINAL ARTICLE

---

neural tube defect, resorption, intra uterine growth retardation, syndactyly, oligodactyly, foot and tail vein hemorrhages. These malformations hamper fetal weight, nutrition and crown rump length of fetuses. Various animal tests are done till today for sorting out the cause of malformations in fetus after silver nanoparticle ingestion through various routes. Maternal repeated oral exposure of AgNPs in pregnant Swiss albino micedams also causes various malformations in fetuses which are for the first time reported in our experiment. The oral ingestion tests of silver nanoparticles on maternal body cause's arousal of various malformations in exteriorized fetuses which increases in percentages with increase in dose. The data of present study says when 0.5, 1, 5, 10, 15 & 20 mg/kg/day silver nanoparticle colloidal solution is injected to pregnant Swiss albino mice it causes arousal of culminative toxicity in fetuses with various malformations. The percentages of such malformations increase with increase in dose of silver nanoparticles. Resorption is a common form of gross anomaly which increases with increase in dose of AgNPs and the increased percentages was evaluated in our study with the increase in dose though control group showed minimal percentage of resorption (3.70%). (Table 1 & 2; Fig. 1).

Intra uterine growth retardation also a common form of gross anomaly which visualized in fetuses while conducting the present study. The calculated percentages are seen progressively increasing with increase in dose of AgNPs as a consequence of this mean $\pm$ s.d. of fetal crown rump length and weight of live fetuses also increased progressively with increase in dose where control group also showed minimal percentages of IUGR (5.55%). (Table 1, 2 and Fig.2). Rest of the gross malformations like limb malformations, snot mal development, proboscis, phocomelia, virulent hemorrhages within the body, mid gut loop herniation like omphalocele, bidiscoidal placental anomaly, close type neural tube defect, syndactyly, oligodactyly, foot and tail vein hemorrhages and simple tail vein hemorrhages also seen increases in terms of percentages with increase in dose of silver nanoparticles. (Table 1& 2; Fig. 3)An exceptional growth of percentages of malformations like severe IUGR and hemorrhages within the body was met in the fetuses of 15mg/kg/day treated group during the course of experiment. (Table 1& 2; Fig. 3 with data underlined and bar diagram with arrow marked). Number and percentages of live fetuses seen decreasing with increase in dose of AgNPs. (Table 2).

Though there is hardly any data available regarding assessment of gross teratogenic anomalies of fetuses by silver nanoparticle colloidal solution after repeated maternal exposure testing our study confirms a strong evidence that silver nanoparticles certainly shows deleterious effects in fetuses after maternal oral exposure. For researcher benefit and public awareness over ignorancethe potential adverse effects of nanosilveradministration has been reported that, inovoof 50 particles per million hydrocolloids of nanoparticles of silver did not influence mortality, growth and development within 48 hrin 20 days old chicken embryos, <sup>(17,18)</sup> but present study“AgNPs effects on fetus gross anomalies”tries to convince 0.5, 1, 5, 10, 15 & 20 mg/kg/day bigger silver nanoparticles of 20 to 100 nm size range in silver nanoparticle colloidal solution repeated oral administration and testing definitely have deleterious effects on embryo-fetus development which cause gross anomalies in fetuses of Swiss albino dams. It confirms repeated oral gavages silver nanoparticle colloidal solution testing on animals in pregnancy cause hampers of fetus natural growth in womb and fetus body morphology is insulted by this, and resulted in abnormal development.

**CONCLUSION:** The present study highly suggests the deleterious effects of nanosilveron embryo-fetus development and thus a teratogen which is dose dependent.

**ACKNOWLEDGEMENT:** The author sincerely acknowledges University Grant Commission.

**REFERENCES:**

1. Kagan VE, Bahir H, Shvedova AA. Nanomedicine and nanotoxicology: two sides of the same coin. *Nanomedicine*. 2005; 1: 313-6.
2. Colvin V. Potential risks of nanomaterials. Environment, Health and Safety Office 617-452-EHSS. 2007; 4: 112.
3. Moore KL, Persaud TVN. *The Developing Human Clinically Oriented Embryology*. 8th Ed, Saunders Elsevier. 2008: pp 458.
4. De santis M, Straface J, Carducci B, Cavaliere AF, De santis L, Luechese A, Merola AM, Caruso A. Risk of drug-induced congenital defects. *Eur J Obstet Gynecol Reprod Biol*. 2004; 10 (117 (1)): 9-10.
5. Chen X, Schluesener HJ. Nanosilver: a nanoproduct in medical application. *ToxicolLett*. 2008 (176 (1)):1 -12.
6. Weast R. C, Spadaro J. A, Becker RO. *Handbook of Chemistry and Physics*. 69th ed Boca Raton, FL: CRC Press, Inc. 1988 pp: 127-8.
7. Rosenman KD, Moss A, Argyria KS. Clinical implications of exposure to silver nitrate and silver oxide. *J Occup Med*. 1979; 21 (430-435).
8. Hussain M Hess KL, Gearhart JM, Geiss KT, Schlager JJ. In vitro toxicity of nanoparticles in BRL 3A rat liver cells. *ToxicolIn Vitro*. 2005; 19: 975-83.
9. Soto K Garza LE, Murr LE. Cytotoxic effects of aggregated nanomaterials. *ActaBiomater*. 2007; 3: 351-8.
10. Bar-Ilan O Albrecht RM, Fako VE, Furgeson DY. Toxicity Assessments of Multi-sized Gold and Silver Nanoparticles in Zebra fish Embryos. *Small*. 2009; 5:1895-1910.
11. Lansdown AB. Critical observations on the neurotoxicity of silver. *Crit Rev Toxicol*. 2007. 37 (3):237-50.
12. Dietl HW Anzil AP, Mehraein P. Brain involvement in generalized argyria. *ClinNeuropathol*. 1984; 3 (1):32-6.
13. Holler JS, Nordberg GF, Fowler BA. Silver. In: Nordberg GF, Fowler BA, Nordberg M, editors. *Handbook on the Toxicology of Metals*. Third edn Academic Press. 2007:pp. 809-14
14. Rungby J Danscher G. Localization of exogenous silver in brain and spinal cord of silver exposed rats. *ActaNeuropathol*. 1983; 60 (1-2):92-8.
15. Solomon S D Bahadory M, Jeyarajasingam A V, Rutkowsky S A, Boritz C, Mulfinger L. *Journal of Chemical Education*. 2007; 84:322-5.
16. Berne BJ, Pecora R. *Dynamic Light Scattering*. Courier Dover Publications. 2000 ISBN0-486-41155-9.
17. Benn T, Cavanagh B, Hristovski K, Posner JD, Westerhoff J. The release of nanosilver from consumer products used in the home. *J Environ Qual*. 2010; 39 (1875-1882).
18. Sawosz E Grodzik M Zielinska M Niemiec T, Olszanska B, Chwalibog A. Nanoparticles of silver do not affect growth, development and DNA oxidative damage in chicken embryos. *Arch Geflugelk*. 2009; 73 (3):208-13.

## ORIGINAL ARTICLE

### AUTHORS:

1. Jyoti Prakash Pani
2. Rajniti Prasad
3. Deepika Joshi
4. Royana Singh

### PARTICULARS OF CONTRIBUTORS:

1. Research Scholar, Department of Anatomy, IMS, BHU Varanasi, Uttar Pradesh.
2. Professor, Department of Paediatrics, IMS, BHU, Varanasi, Uttar Pradesh.
3. Professor & HOD, Department of Neurology, IMS, BHU, Varanasi, Uttar Pradesh.

### FINANCIAL OR OTHER

**COMPETING INTERESTS:** None

4. Professor, Department of Anatomy, IMS, BHU, Varanasi, Uttar Pradesh.

### NAME ADDRESS EMAIL ID OF THE CORRESPONDING AUTHOR:

Dr. Royana Singh,  
Department of Anatomy,  
Institute of Medical Sciences,  
Banaras Hindu University,  
Varanasi-221005, Uttar Pradesh.  
E-mail: singhroyana@rediffmail.com  
royanasingh@bhu.ac.in

Date of Submission: 13/07/2015.  
Date of Peer Review: 14/07/2015.  
Date of Acceptance: 28/07/2015.  
Date of Publishing: 31/07/2015.