DOI: 10.14260/jemds/2015/398

ORIGINAL ARTICLE

ROLE OF SONOGRAPHY IN EVALUATION OF CERVICAL LYMPH NODES AND COMPARISON WITH THEIR CYTOLOGICAL FINDINGS

J. S. Sikarwar[1], Amit Jain[2], Shiv Singh Kaneria[3]

HOW TO CITE THIS ARTICLE:
J. S. Sikarwar, Amit Jain, Shiv Singh Kaneria. "Role of Sonography in Evaluation of Cervical Lymph Nodes and Comparison with their Cytological Findings". Journal of Evolution of Medical and Dental Sciences 2015; Vol. 4, Issue 16, February 23; Page: 2777-2791, DOI: 10.14260/jemds/2015/398

ABSTRACT: This study was conducted in department of radio-diagnosis, G.R. Medical College, Gwalior for period of one year (October 2013-September 2014). Ultrasound evaluation of cervical lymph-nodes was done using high frequency (7.5-MHz) linear transducer in 100 patients. Various Parameters such as size, shape (L/S ratio), hilar echogenicity, micro calcification, color flow pattern and R.I. (resistive index) were applied to assess the lymph nodes. Fine needle aspiration cytology of these lymph nodes was done under ultrasound guidance and sent for cytological evaluation. Finally results of ultrasound and cytology compared. In this study ultrasound examination of total 100 patients with subsequent F.N.A.C of cervical lymph node was done. Out of 100 pt 74 were having benign and 26 were having malignant etiology. In this study we found size criterion has sensitivity of 84.6%, specificity 67.5% PPV 47.8% NPV 92.5%.L/S ratio criterion has sensitivity 88.6%, specificity 75.6%, PPV 56.1%, and NPV 94.9%. Hilar echogenicity criterion has sensitivity 76%, specificity 82.4%, PPV 60.6%, NPV 91.9%. Using micro-calcification criterion we got sensitivity of 30.7%, specificity 97.2%, PPV 80%, NPV 80%. Peripheral vascularity criterion has sensitivity of 84.6%, specificity 70.2%, PPV 50 %and NPV 92.8%. Finally R.I. value has sensitivity 92.3% specificity 71.6% PPV 53% and NPV 96.3%. **AIMS AND OBJECTIVES:** Sonographic examination of cervical lymph nodes. To do FNAC of cervical lymph nodes. Comparison of ultrasound findings of cervical lymph node with Cytological findings. To assess sensitivity, specificity, positive predictive value, and negative predictive value of ultrasound in diagnosing malignant and benign nature of cervical lymph node. The aim of this study is to evaluate the role of ultrasound in differentiation of normal/reactive nodes from malignant one. **MATERIAL AND METHODS:** This is a prospective study conducted in department of radio diagnosis, G.R. Medical College and JA groups of hospitals Gwalior using USG machine Aloka Pro sound Alpha-6 (Aloka Trivitron Pvt. Ltd. Tokyo Japan). Linear 7.5-MHz probe was used for real-time B-scans of the neck, during period of one year. All the patients sent for USG guided FNAC from cervical lymph nodes were scanned sonographically. All the patients send to radiological assessment of cervical lymph adenopathy were scanned sonographically and USG guided FNAC from lymph nodes were taken in selected patients. Total one hundred patients were examined and F.N.A.C of these patient's lymph node was done. Findings of ultrasound and cytology were compared.
KEYWORDS: Sonography, Cervical Lymph nodes.

INTRODUCTION: Cervical lymphadenopathy is generally caused by non-malignant conditions but it is found in malignancy also. Five– Year survival rate depends on presence or absence of cervical lymph node involvement in malignant disease hence the prognosis and plan of action.

Although we can diagnose and monitor cervical lymphadenopathy by using various modalities like ultrasound, CT or MRI; easy availability, low cost and no risk of radiation makes ultrasound often the investigation of choice for assessment of cervical lymphadenopathy.

Ultrasound is very useful in assessment of cervical lymph nodes and versatile modality to characterize them benign or malignant. Superficial nature of cervical lymph node makes them easily assessable for ultrasound examination as well as for F.N.A.C.

Various parameters or criterion are there to suspect whether the particular lymph node is benign or malignant. Aim of this study is to evaluate the usefulness of these criteria in terms of sensitivity, specificity, PPV and NPV.

RESULTS AND DISCUSSION:

SIZE: Both inflammatory and malignant diseases lead to enlargement of lymph Nodes and to reduction of their echogenicity, whether as a consequence of an increase of intranodal fluid portion or hyperplasia of lymphoid follicles or tumor cell invasion.[1]

Sanja Kusacic Kuna stated that absolute measurements of the size of the lymph node, such as the maximum diameter, are not sufficient for differentiation of Inflammatory from metastatic lymph nodes.

Minimal axial diameter is the most accurate dimension for predicting malignancy.[2] Lymph nodes in the upper neck, including those in the submandibular and subdigastric region, tend to be larger than those in the lower neck.[3]

The size ranges for benign and malignant nodes overlapped; thus, differentiation of those lesions could not be based on size alone[4]. van del Brekel et al.[5] suggested that a minimal axial diameter of 9 mm for subdigastric nodes and 8 mm for all other cervical nodes yielded overall accuracy of 75%.

Bruneton et al. reported that normal cervical lymph nodes had a maximal short axis axial diameter of 8 mm or less.[6]

Bruneton et al., Hajek et al. and Sakai et al.[7] suggested nodal size to be a reliable indicator for differentiating benign from malignant nodes.

Ahuja et al suggested that if a lower cut off is used, the sensitivity increases but the specificity diminishes. If a higher cut off is used, the sensitivity is reduced but the specificity rises.

In a patient with known head and neck primary, larger lymph nodes have a greater likelihood of malignancy. However, reactive nodes may be as large as malignant nodes. Van den Brekel MW suggested that Minimal axial diameter is the most accurate dimension for predicting malignancy.

In our study out of 100 cases 46 were having enlarged lymph nodes >1 cm in short axis and 54 were having lymph nodes < 1 cm in short axis. Among 26 malignant lymph nodes 22 (84.6%) were >1 cm in short axis and among 74 benign lymph 24(32.43%) were >1 cm in short axis. Out of 26 malignant lymph nodes only 4(15.38%) were having size <1 cm in short axis whereas 50(67.5%) out of 74 non malignant lymph nodes were having size <1 cm in short axis. Criterion of size yielded sensitivity of 84.6%, specificity 67.5%.

DOI: 10.14260/jemds/2015/398

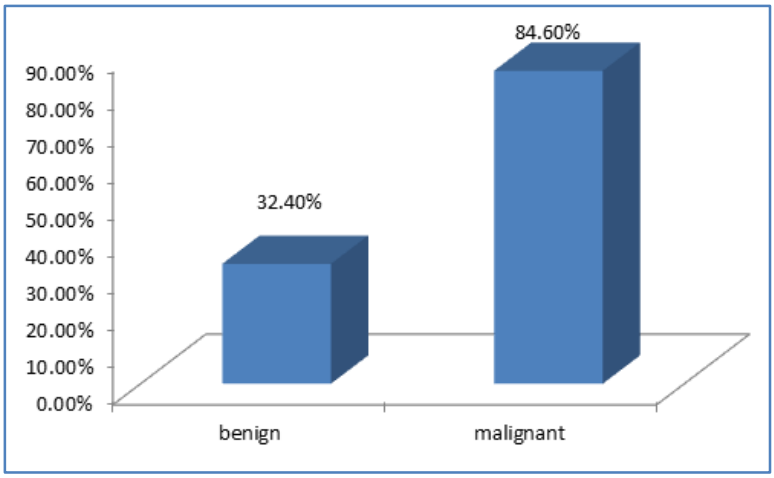

Graph 1

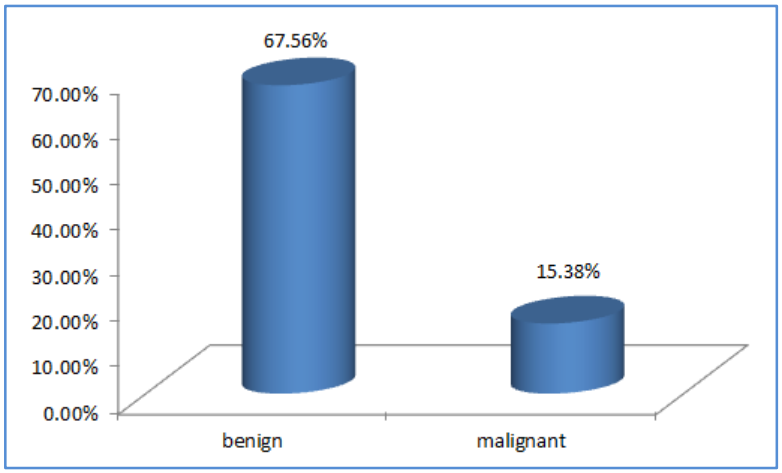

Graph 2

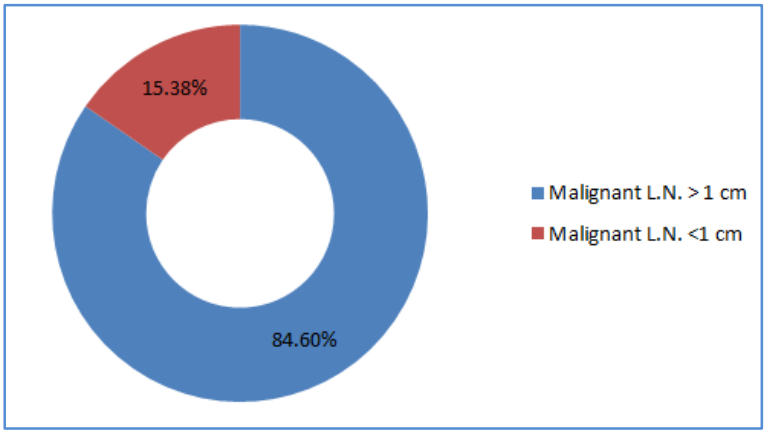

Graph 3

DOI: 10.14260/jemds/2015/398

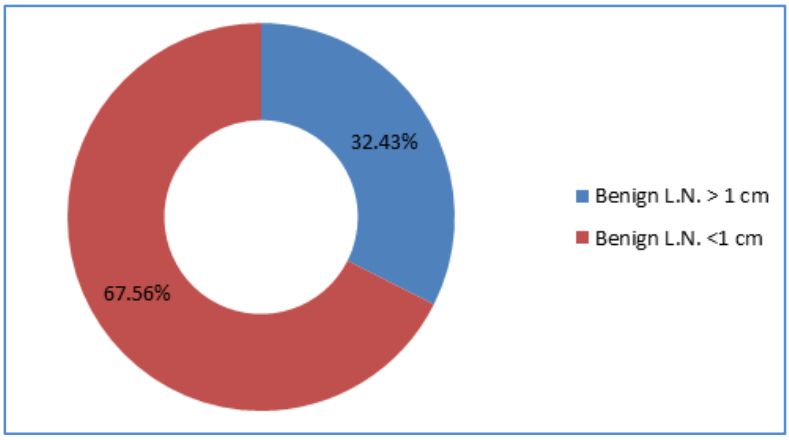

Graph 4

SHAPE: Malignant nodes tend to be round in shape, whereas normal or reactive nodes are usually oval or fusiform.[8]

A short to long axis (S/L) or long to short axis (L/S) ratio can be used to assess the nodal shape. An S/L ratio greater than 0.5 (or L/S ratio lesser than 2) indicates a round lymph node. Although round lymph nodes are more likely to be malignant, one must note that normal submandibular and parotid nodes are usually round.

Yusha et al. reported that short axis/long axis diameter ratio >0.73 (round) indicates metastatic node when compared to the reactive cervical lymph nodes with ratio <0.54.

Toriyabe et al. stated that in 68% of benign nodes S/L ratio was less than 0.6 and 81% of metastatic nodes ratio was more than 0.6 and round in shape.

Most investigators have suggested short axis/long axis ratio as the most reliable indicator for metastatic nodes.[9]

Steinkamp HJ et al report that 95% of metastatic nodes had L/S ratio of less than 2.

Yusha et al. reported that short axis/long axis diameter ratio >0.73 (round) indicates metastatic node when compared to the reactive cervical lymph nodes with ratio <0.54.

The L/T ratio has a high degree of accuracy in the differentiation between benign and metastatic lymph nodes.[10]

Normal cervical lymph nodes typically have an oval shape. Even when cervical lymph nodes are enlarged because of a benign inflammatory process, they usually retain this shape, whereas malignant lymph nodes acquire its shape to round (L/T <2).

We found that out of 100 patient 59 patient have Long axis/Short axis(L/S Ratio) ratio >2 out of these 56 are non-malignant and only 3 are malignant. On the other hand 41 patient have lymph node long axis/short axis ratio < 2 out of these 23 are malignant and 18 are benign. Out of 26 malignant lymph nodes 23(88.4%) have L/S ratio < 2 and only 3 (11.57%) malignant lymph nodes have L/S Ratio >2.

In our study 18 (24.3%)out of 74 non-malignant lymph nodes have L/S ratio <2 and 56(75.6%) out of 74 non-malignant lymph nodes have L/S Ratio >2.The criteria of L/S Ratio in our

DOI: 10.14260/jemds/2015/398

study this criterion is showing 88.46% sensitivity, 75.6% specificity, 56.09% PPV, 94.9% NPV and accuracy of 79 %.

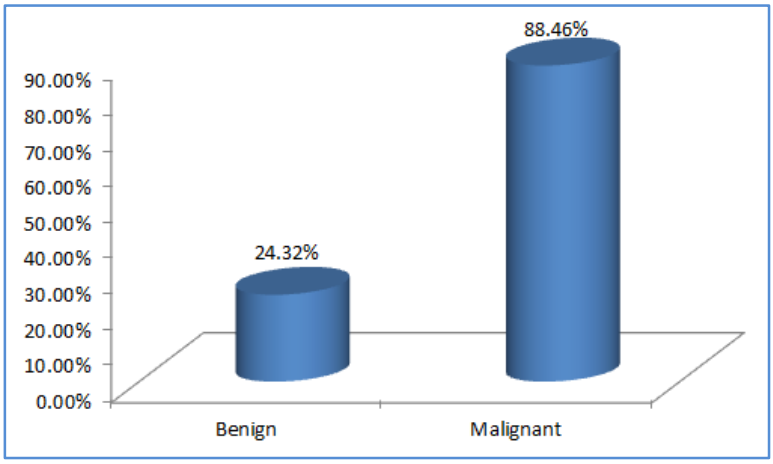

Graph 5

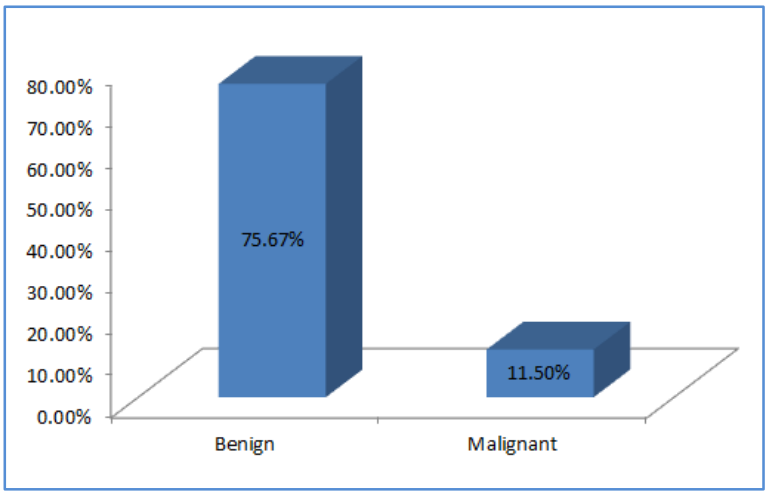

Graph 6

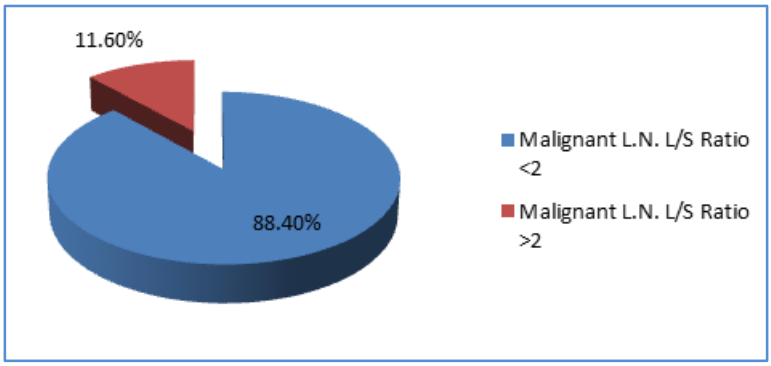

Graph 7

DOI: 10.14260/jemds/2015/398

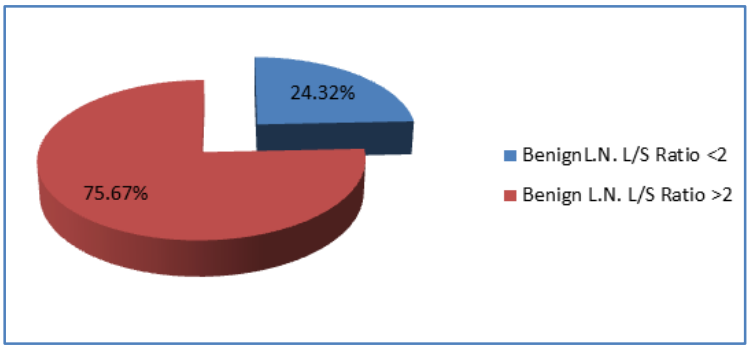

Graph 8

ECHOGENIC HILUM: The echogenic hilum is closely associated with the medullary sinuses in the lymph node. These act as multiple acoustic interfaces reflecting the ultrasound waves and producing an echogenic structure, fatty deposition only makes the hilum more obvious on ultrasound.[11]

Vassallo et al. reported that the echogenic hilum corresponds to the abundance of collecting sinuses and provides acoustic interfaces to reflect a portion of the ultrasonic wave making the hilum echogenic.

It is thought that a hyper echoic hilum is a good indicator of a benign lymph node. However, the absence of a hilum is more frequently a sign of malignancy.

Yusha et al. found absence of hilar echo in 97% of metastatic cervical lymph nodes. Where as 73% of non metastatic cervical lymph nodes showed hilar echogenicity.

Ying et al. found echogenic hilum to be a normal sonographic feature of normal cervical lymph nodes in 96% of cases; they stated that although metastatic nodes lack this feature, hilum may be present in the early stage of involvement in which medullary sinuses have not been sufficiently disrupted to eradicate it.

In our study echogenic hila is present in 67/100 lymph nodes and absent in 33/100 lymph nodes. Out of these 67 lymph nodes showing hilar echogenicity only 6 are malignant and out of 33 lymph nodes not showing hilar echogenicity 20 are malignant. Out of 26 malignant lymph nodes 20(76.9%) are not showing hilar echogenicity and out of 74 non malignant 61(82.43%) showing hilar echogenicity. Six (23.0%) out of 26 malignant lymph nodes shows hilar echogenicity and 13(17.56%) out of 74 non malignant lymph nodes do not show hilar echogenicity. The criterion of loss of hilar echogenicity has sensitivity 76.9%, specificity 82.4%, PPV 60.6%, NPV 91.0%.

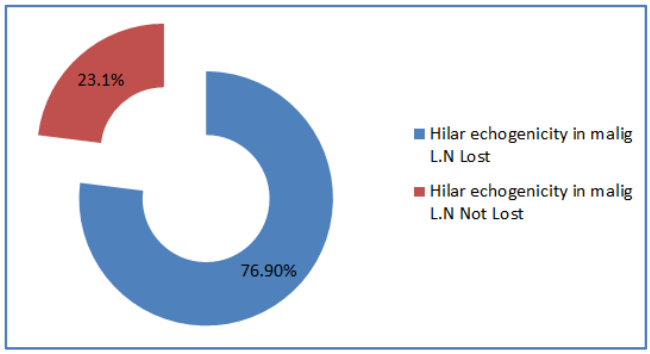

Graph 9

DOI: 10.14260/jemds/2015/398

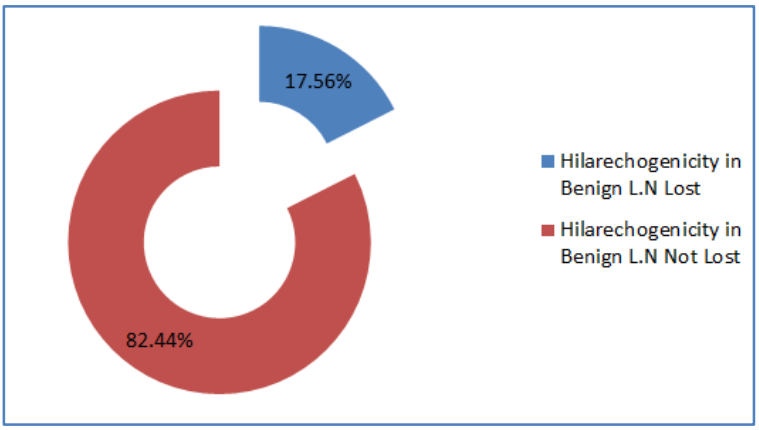

Graph 10

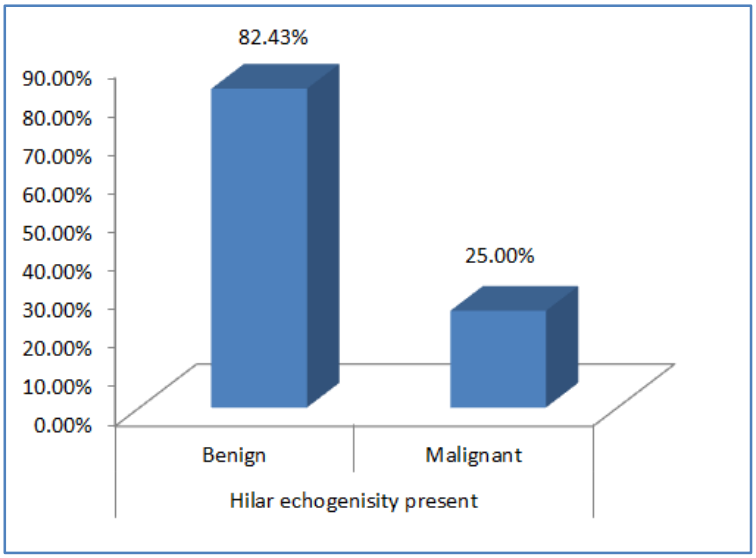

Graph 11

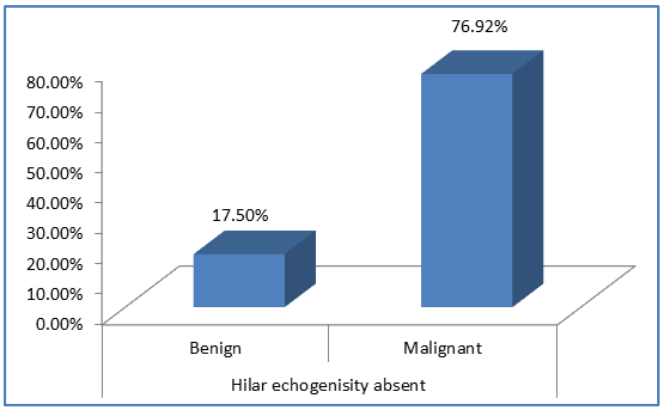

Graph 12

DOI: 10.14260/jemds/2015/398

CALCIFICATION: The presence of calcifications can also be useful in predicting the benign or malignant nature of lymph nodes. Most authors have reported calcifications only in malignant nodes.[12]

Lymph node calcification if found is highly suspicious of Papillary carcinoma thyroid (psammoma bodies) and medullary carcinoma thyroid. However tubercular lymph nodes may show calcification.

Calcification may also be seen in post treatment lymphomatous and tuberculous nodes. However, the calcification in these nodes is usually dense and shows strong acoustic shadowing.

Intranodal calcification is rarely found in cervical lymphadenopathy.

Ahuja AT, Chow L found that about 50-69% of metastatic nodes from papillary carcinoma of the thyroid show calcification which is punctuate, peripherally located and may show acoustic shadowing with a high-frequency transducer.

In our study out of 100 lymph nodes 10 are showing micro-calcification. Out of 74 non malignant lymph nodes only 2 are showing micro-calcification and 8 out of 26 malignant lymph nodes showing micro-calcification. A criterion of micro-calcification has shown 30.7% sensitivity, 97.2% specificity, 80% NPV, and 80% PPV.

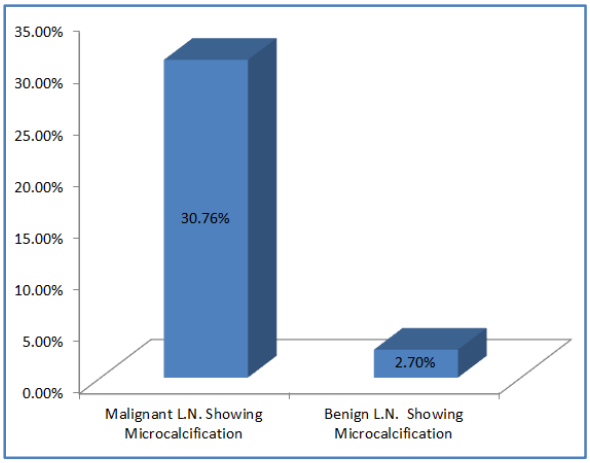

Graph 13

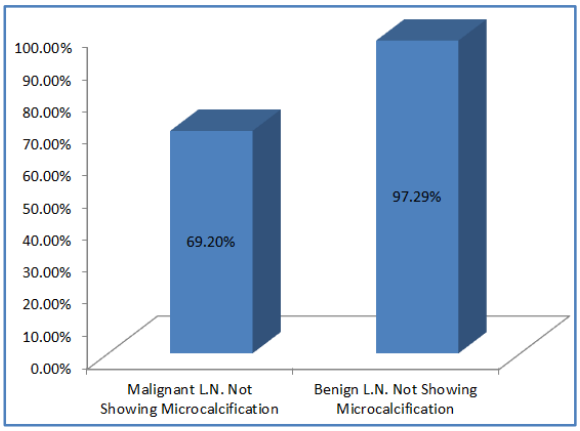

Graph 14

DOI: 10.14260/jemds/2015/398

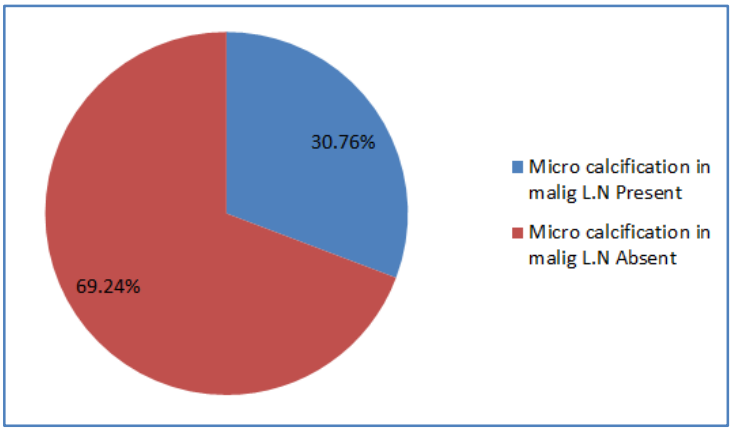

Graph 15

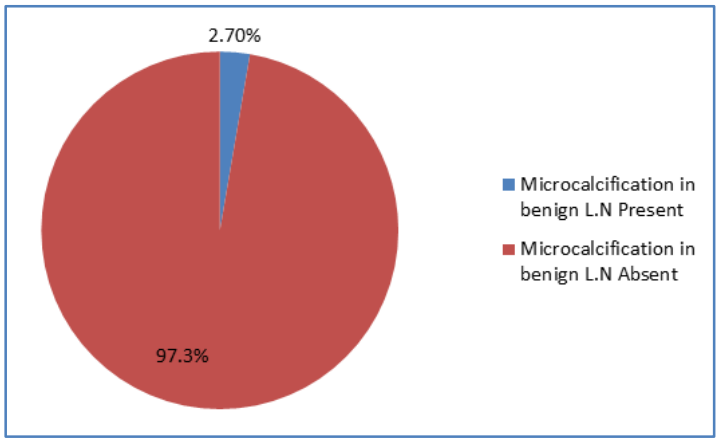

Graph 16

VASCULARITY: Most of the studies agreed that peripheral vascular pattern is associated with malignancy with high specificity and varying sensitivity. This is because tumor cells secrete angiogenic factors. As the hilar vessels get obstructed due to tumor infiltration, revascularization arises from peripheral and adjacent vessels.

Benign lymph nodes tend to have a central hilar vascular pattern.[13] Peripheral vascularity is commonly found in metastatic nodes and is related to angiogenesis that induces recruitment of peripheral vessels into the lymph nodes. Hilar vascularity may be present together with peripheral vascularity in metastatic nodes. (Mixed vascularity). Such mixed vascularity is usually found in early metastases where the peripheral vessels are induced, but the normal hilar vessels are preserved, which may be destroyed by the tumor cells at a later stage.

Using high resolution ultrasound, 90% of lymph nodes with a maximum transverse diameter >5mm will demonstrate intra-nodal vascularity (hilar vascularity) and the remaining appear apparently avascular.[14]

On color/power doppler sonography, reduction in intra-nodal vascularity is a sensitive sign of positive treatment response and is useful in predicting patient prognosis.

DOI: 10.14260/jemds/2015/398

In our study peripheral vascularity was present in 44 lymph nodes out of 100. Twenty two out of 26 malignant lymph nodes were showing peripheral vascularity whereas 22 out of 74 non malignant lymph nodes were showing peripheral vascularity. Four out of 26 malignant lymph nodes not showing peripheral vascularity and 52 out of 74 non malignant lymph nodes were not showing peripheral vascularity. We found sensitivity of 84.6%, specificity of 70.2% of peripheral vascularity criterion.

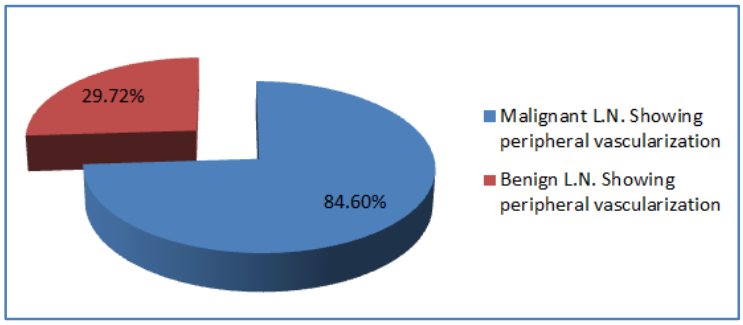

Graph 17

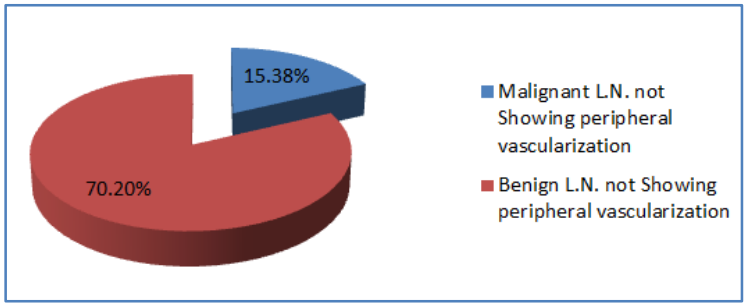

Graph 18

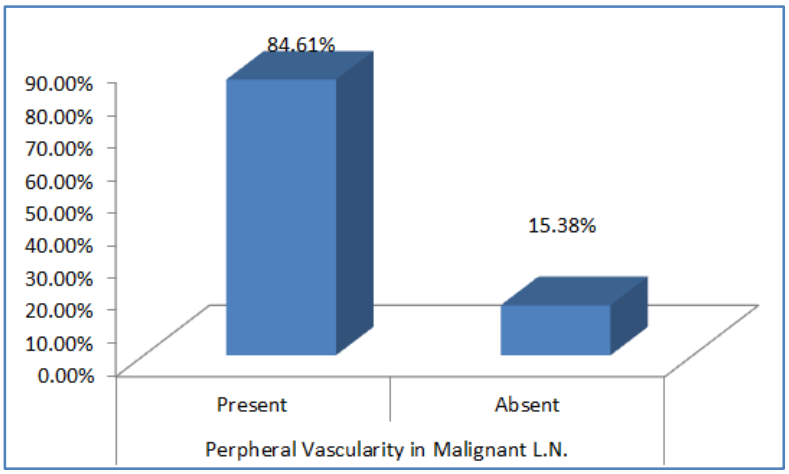

Graph 19

DOI: 10.14260/jemds/2015/398

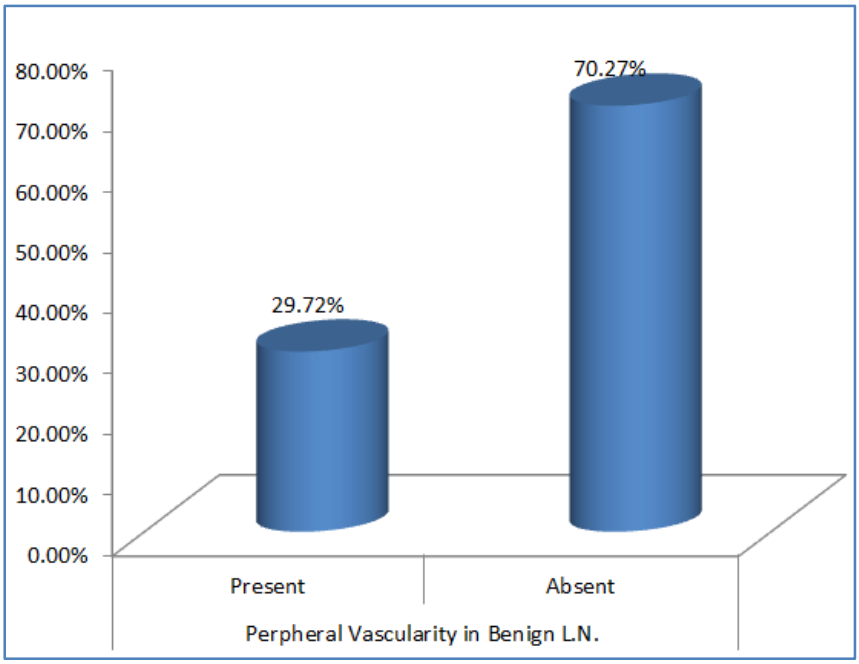

Graph 20

R. I VALUE: Malignant lymph nodes have high value of resistivity index because of altered vasculature due to malignant cell invasion and new angiogenesis.

Theoretically, low impedance, produced by vasodilatation, is encountered in inflammation while vessel compression by tumor cells leads to increased impedance. In normal or reactive lymph nodes, as the size of the nodes increases, the intranodal blood flow velocity increases significantly as well.

There was considerable overlap of the parameters between the two groups.[15]

Ahuja AT, Ying M, Ho SY, et al found in their study that the cut-off value of 0.7 for RI yielded a sensitivity of 86% and a specificity of 70%.

The reliability of Doppler US in differentiating malignant from benign lymph nodes is still a matter of debate. Authors who have analyzed vascular resistance in cervical lymph nodes have mostly found higher Doppler indices in malignant than in benign nodes.

Ahuja AT, Ying M, Ho SY, et al found in their study that the cut-off value of 0.7 for RI yielded a sensitivity of 86% and a specificity of 70%.

In our study Out of 100 lymph nodes 45 were showing R.I. (Resistive Index) Value >0.75.and 55 were showing R.I. values <0.75. Out of 26 malignant lymph nodes 24 were showing R.I. values > 0.75.and only 21 out of 74 non malignant lymph nodes were showing R.I. values >0.75.On the other hand 2 out of 26 malignant lymph nodes showing R.I. value < 0.75 and 53 out of 74 non malignant lymph nodes showing R.I. value <0.75.R.I. criteria yielded 92.3% sensitivity, 71.6% specificity, 53% PPV, 96.3 % NPV and 77 % accuracy.

DOI: 10.14260/jemds/2015/398

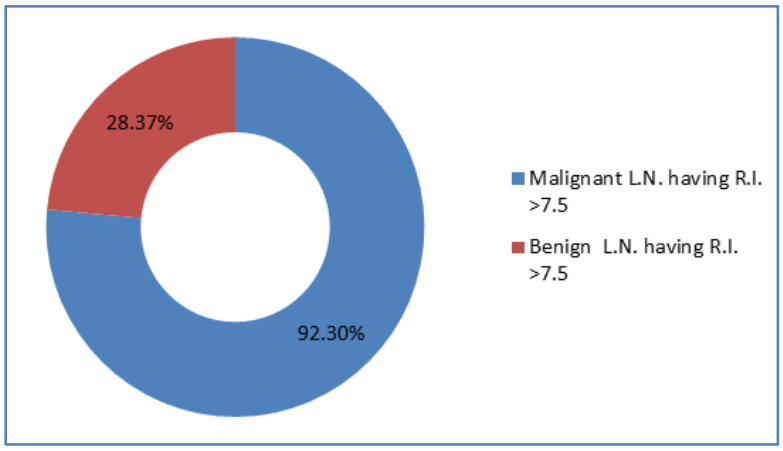

Graph 21

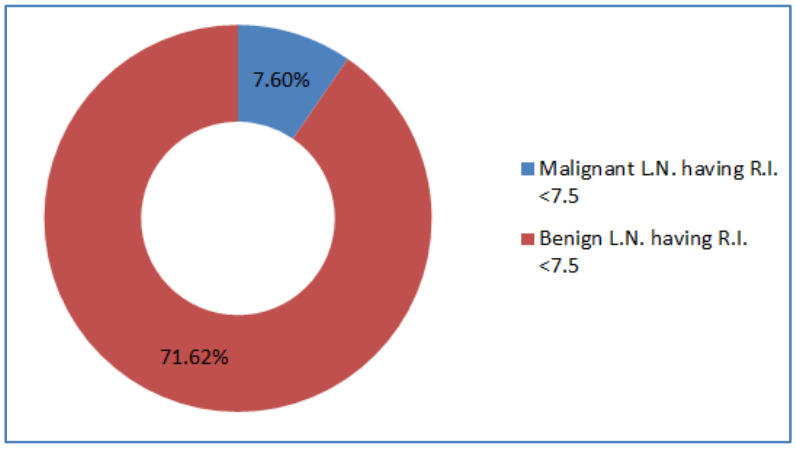

Graph 22

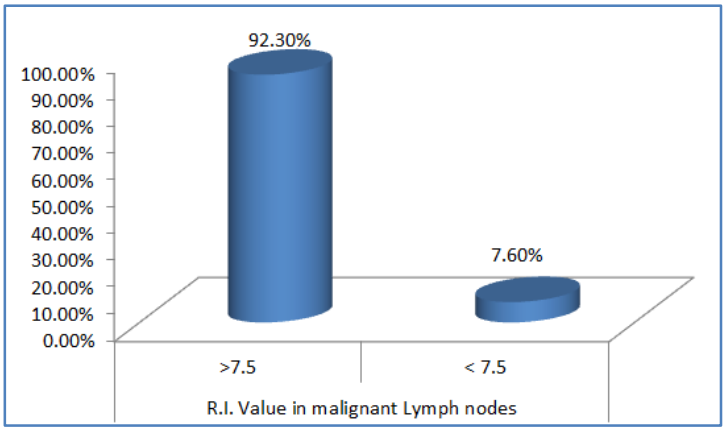

Graph 23

DOI: 10.14260/jemds/2015/398

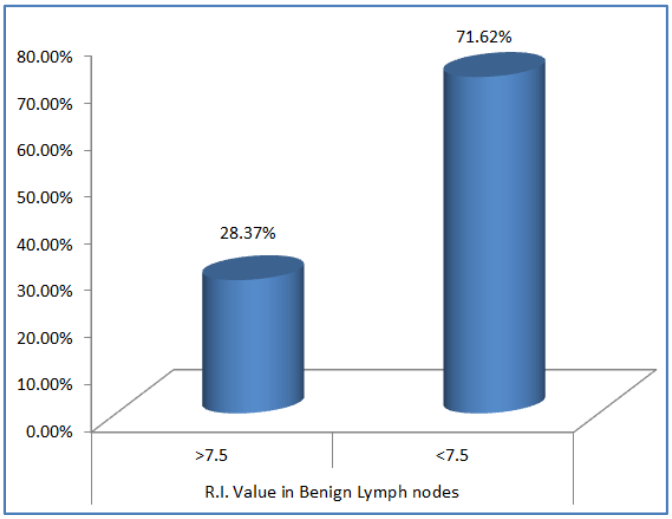

Graph 24

SUMMARY AND CONCLUSSION: There are different ultrasound criteria for assessment of cervical lymph nodes. The aim of this study is to evaluate sensitivity, specificity, PPV, NPV and ultimately usefulness of these criteria. In our study we found that size alone is not a very good criterion to categorize cervical lymph node. Malignant lymph nodes tend to be larger due to rapid growth but benign lymph node can be large as well. We have found malignant involvement of small lymph node in 4 cases out of 26 malignant cases.

Shape of normal and reactive lymph node is oval (L/S Ratio >2), whereas malignant lymph nodes are round shaped (L/S Ratio <2) due to rapid overgrowth. We found that in our study 23/26 (88.46%) of malignant lymph nodes have L/S Ratio <2. This criterion has 94.9% Negative predictive value.

Hilar echogenicity is due to abundance of collecting sinuses at hila providing interfaces to reflect a portion of ultrasound wave. In malignant infiltration the hilar echogenicity is lost. We found in our study that 20/26 malignant lymph nodes hilar echogenicity was lost and 61/74 (82.4%) non malignant lymph nodes have echogenic hila.

Micro-calcification are found only in 10/100 cases out of these 8 were having malignant etiology and only 2 have non malignant etiology. The fact that calcification in lymph nodes are rare and found in specific type of malignancy(papillary carcinoma thyroid psammoma bodies) and some infections (tuberculosis) explains it low prevalence in our study group. Nevertheless this criterion has highest specificity (97.3%) in our study.

Peripheral vascularization in cervical lymph node is feature of malignancy. Non malignant lymph nodes have central flow. This is due to altered vasculature of node due to malignant involvement. In our study 22 out of 26 malignant cases had peripheral vascularization. This criterion has sensitivity 84.6% and specificity 70.2%.

On spectral Doppler high resistive index points toward malignancy. In our study 24/26 malignant lymph nodes have high (>0.75) R.I. values. It has got highest NPV (96.3%) in our study, but high R.I. values can be found in inflammatory lymphnodes too.In our study we found 21/74 non-

DOI: 10.14260/jemds/2015/398

malignant lymph nodes showing high (>0.75) R. I values. This is due to overall increased blood supply to inflammatory lymph node.

Ultrasound is very useful modality in assessment of cervical lymphadenopathy. Different criteria have different sensitivity, specificity, NPV and PPV. Considerable overlap occurs among different criteria. Neither of them alone is 100% specific, nor 100% sensitive. Almost all criteria have very high negative predictive value, and different positive predictive values signifying role of ultrasound to find out non malignant lymph nodes with greater degree of confidence.

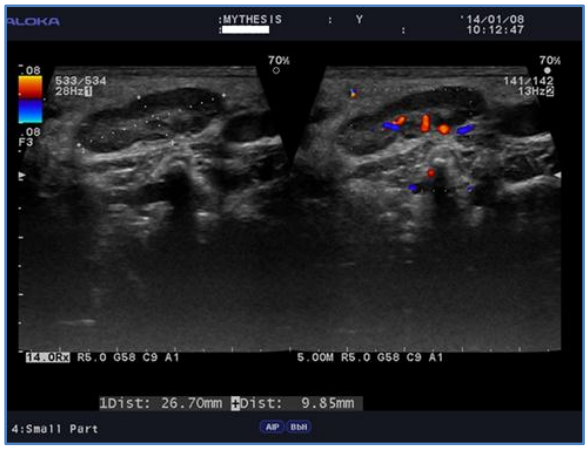

Fig. 1: Oval shaped lymph node showing hilar echogenicity, L/S Ratio > 2 (2.71) and central flow

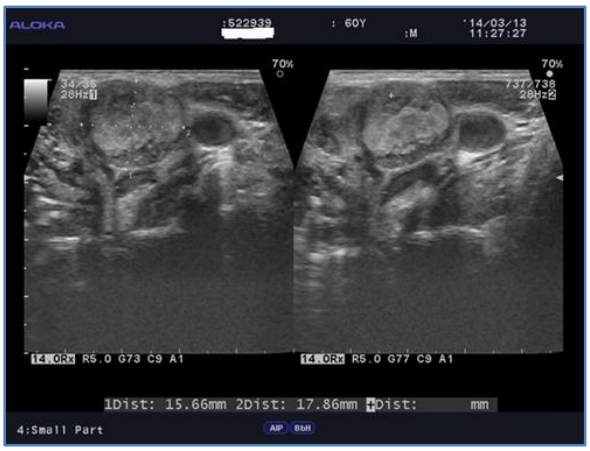

Fig. 2: Round shaped Lymph node having L/S Ratio < 2 (1.14) with loss of hilar echo

BIBLIOGRAPHY:

1. Koischwitz D, Gritzmann N. Ultrasound of the neck. Radiol Clin North Am 2000; 38: 1029–1045.
2. Van den Brekel MW, Stel HV, Castelijns JA, Nauta JJ, van der Waal I, Valk J, et al. Cervical lymph node metastasis: assessment of radiologic criteria.Radiology. 1990; 177: 379–84.
3. Ying M, Ahuja A, Brook F, Brown B, Metreweli C.Sonographic appearance and distribution of normalcervical lymph nodes in a Chinese population. J Ultrasound Med. 1996; 15: 431–6.

4. Sutton RT, Reading CC, Charboneau WJ, James EM, Grant CS, Hay ID. US-guided biopsy of neck masses in postoperative management of patients with thyroid cancer. Radiology 1988; 168: 769–772.
5. Van den Brekel MW, Castelijns JA, Stel HV, Golding RP, Meyer CJ, Snow GB. Modern imaging techniques and ultrasound-guided aspiration cytology for the assessment of neck node metastases: a prospective comparative study. Eur Arch Otorhinolaryngol. 1993; 250: 11–7.
6. Ahuja A, Leung SF, Ying M, Metreweli C. Echography of metastatic nodes treated by radiotherapy. J Laryngol Otol. 1999; 113: 993–8.
7. Swartz JD, Yussen PS, Popky GL. Imaging of the neck: nodal disease. Crit Rev Diagn Imaging.1991; 31: 413–69.
8. Ahuja A, Ying M. Sonography of neck lymph nodes.
9. F. Sakai, K. Kiyono, S. Sone et al., "Ultrasonic evaluation of cervical metastatic lymphadenopathy," Journal of Ultrasound in Medicine, vol. 7, no. 6, pp. 305–310, 1988.
10. Solbiati L, Cioffi V, Ballarati E. Ultrasonography of the neck. Radiol Clin North Am 1992; 30: 941–954.
11. Evans RM, Ahuja A, Metreweli C. The linear echogenic hilum in cervical lymphadenopathy–a sign of benignity or malignancy? Clin Radiol. 1993; 47: 262–4.
12. Ahuja AT, Chow L, Chick W, King W, Metreweli C. Metastatic cervical nodes in papillary carcinoma of the thyroid: ultrasound and histological correlation. Clin Radiol 1995; 50: 229–331.
13. Ying M, Ahuja A, Brook F, Metreweli C. Vascularity and grey-scale sonographic features of normal cervical lymph nodes: variations with nodal size. Clin Radiol. 2001; 56: 416–9.
14. Ying M, Ahuja A, Brook F, Metreweli C. Power Doppler sonography of normal cervical lymph nodes. J Ultrasound Med. 2000; 19: 511–7.
15. Ahuja A, Ying M. Sonographic evaluation of cervical lymphadenopathy: is power Doppler sonography routinely indicated? Ultrasound Med Biol 2003; 29: 353-359.

AUTHORS:

1. J. S. Sikarwar
2. Amit Jain
3. Shiv Singh Kaneria

PARTICULARS OF CONTRIBUTORS:

1. Associate Professor, Department of Radio-diagnosis, G. R. Medical College, Gwalior, Madhya Pradesh.
2. Assistant Professor, Department of Radio-diagnosis, G. R. Medical College, Gwalior, Madhya Pradesh.
3. Post Graduate Student, Department of Radio-diagnosis, G. R. Medical College, Gwalior, Madhya Pradesh.

NAME ADDRESS EMAIL ID OF THE CORRESPONDING AUTHOR:
Dr. Shiv Singh Kaneria,
1091, H. I. G. New Darpan Colony,
Thatipur, Gwalior,
Madhya Pradesh-474010.
E-mail: doctorsskaneria@gmail.com

FINANCIAL OR OTHER COMPETING INTERESTS: None

Date of Submission: 22/01/2015.
Date of Peer Review: 23/01/2015.
Date of Acceptance: 16/02/2015.
Date of Publishing: 21/02/2015.