

## OPERATIVE MANAGEMENT OF INTRA-ARTICULAR DISTAL HUMERAL FRACTURES WITH LOCKING PLATES

Abhilekh Mishra<sup>1</sup>, Vidya Bhushan Singh<sup>2</sup>, Amit Chaurasia<sup>3</sup>, P. K. Lakhtakia<sup>4</sup>

<sup>1</sup>Assistant Professor, Department of Orthopaedics, S. S. Medical College, Rewa, Madhya Pradesh.

<sup>2</sup>Assistant Professor, Department of Orthopaedics, S. S. Medical College, Rewa, Madhya Pradesh.

<sup>3</sup>Associate Professor, Department of Orthopaedics, S. S. Medical College, Rewa, Madhya Pradesh.

<sup>4</sup>Professor, Department of Orthopaedics, S. S. Medical College, Rewa, Madhya Pradesh.

**ABSTRACT: BACKGROUND:** Intra-articular distal humeral fractures are common, but complex elbow injuries. To obtain good results, anatomical reduction with rigid fixation and early range of mobilization is required. Treatment of these fractures with conventional plates is associated with many complications such as non-anatomic reduction of articular surfaces, malunion, non-union, loosening of implant, residual stiffness of the elbow and post-traumatic osteoarthritis. In this situation the application of locking plates having a fixed angle plate screw construct can minimise most of the above complications.

**OBJECTIVE:** To evaluate radiological and functional outcome of locking plate application for the management of intra-articular distal humeral fractures.

**MATERIAL AND METHODS:** This prospective study was conducted from January 2013 to December 2014. We operated 20 patients of AO type-C intra-articular distal humeral fractures. Fracture was exposed using modified Campbell's posterior approach in less comminuted fractures and a V-shaped Olecranon osteotomy was done to get better exposure of the articular surface in cases with severe articular comminution. The fracture was stabilized using an intercondylar screw, pre-contoured locking compression plates and/or locking reconstruction plates as per preoperative planning. Patients were reviewed at monthly interval for clinical-radiological evaluation. Final outcome measures included radiological assessment, range of motion and Mayo elbow performance score (MEPS).

**RESULTS:** All the fractures were united at an average 12 weeks. Two patients developed numbness in the distribution of ulnar nerve and one patient developed superficial infection in immediate postoperative period. None of the patients had malunion and loosening of implant. The average arc of flexion-extension was 105°, although no patient had loss of supination/pronation. Mayo Elbow Performance Score was excellent in 15 (75%), good in 3 (15%), fair in 1 (5%) and poor in 1 (5%).

**CONCLUSION:** The locking plate is a useful implant for the treatment of complete articular (type-c) distal humeral fractures.

**KEYWORDS:** Distal Humeral Fractures, Complete Articular, Locking Plate.

**HOW TO CITE THIS ARTICLE:** Abhilekh Mishra, Vidya Bhushan Singh, Amit Chaurasia, P. K. Lakhtakia. "Operative Management of Intra-Articular Distal Humeral Fractures with Locking Plates." Journal of Evolution of Medical and Dental Sciences 2015; Vol. 4, Issue 94, November 23; Page: 15923-15926, DOI: 10.14260/jemds/2015/2318.

**INTRODUCTION:** Fractures of the distal humerus account for approximately 2–6% of all fractures and about 30% of all elbow fractures.<sup>1</sup> Distal humeral fracture occurs in the younger age-groups secondary to high-energy trauma and in elderly women as a result of relatively low-energy trauma.<sup>2</sup> Fractures of the distal humerus are challenging to treat because the chances of functional impairment and deformity are very high following conservative treatment and stable internal fixation may be difficult to achieve due to the complexity of the fracture and associated osteoporosis.<sup>3</sup> To obtain good results, anatomical reduction with rigid fixation and early range of mobilization is required.

Due to the characteristic intra-articular involvement and poor control of fracture fragments with closed treatment these fractures are treated operatively to achieve anatomic reduction and stable fixation of the fractured fragments.<sup>4</sup>

The frequent multi-fragmentary nature of these fractures with comminution of the articular surface and metaphysis makes accurate reduction and fixation very difficult.<sup>5</sup> Double plate fixation is considered the correct treatment for a comminuted intra-articular fracture of the distal humerus.<sup>6</sup> The present study was planned to evaluate the radiological and functional outcome of parallel locking plate application for the management of intra-articular distal humeral fractures.

**METHODS:** This prospective study comprised 20 consecutive patients with complete articular fractures of the distal humerus reported to us in the Department of Orthopaedics, S. S. Medical College Hospital, Rewa from January 2013 to December 2014. Patients of all ages and of either sex after fusion of epiphysis were included in this study. We included both closed and open fractures (Gustillo Grade-I) of distal end of the humerus. Patients were excluded if they had pathological fracture, pre-existing deformity, disability, infection, previous surgical intervention in the involved elbow, unfit for surgery or failure to give consent.

After detailed clinical-radiological examination and informed consent, all patients were subjected to surgery

*Financial or Other, Competing Interest: None.*

*Submission 04-11-2015, Peer Review 05-11-2015,*

*Acceptance 13-11-2015, Published 20-11-2015.*

*Corresponding Author:*

*Dr. Vidya Bhushan Singh,*

*F-10, Doctor's Colony, S. S. Medical College Campus,*

*Rewa, Madhya Pradesh, India*

*E-mail: dr.vidyabhushan.singh@gmail.com*

*DOI:10.14260/jemds/2015/2318.*

under pneumatic tourniquet. Intravenous antibiotic was given half an hour before surgery.

The patients were taken up for surgery after regional/general anaesthesia in lateral decubitus position with arm supported and forearm hanging. Elbow was exposed through standard midline posterior approach with incision beginning 5cm distal to the tip of the olecranon and extending proximally in the arm up to 8cm above the tip of the olecranon. Ulnar nerve was exposed and secured. Fracture was exposed using modified Campbell's posterior approach in less comminuted fractures and a V-shaped Olecranon osteotomy was done to get better exposure of the articular surface in cases with severe articular comminution.

The fracture was reduced to correct anatomic position, including articular surface with special attention to trochlear reconstruction. Reduction was temporarily held by K-wires and reduction bone clamps. The fracture was stabilized using an intercondylar screw, pre-contoured locking compression plates and/or locking reconstruction plates as per preoperative planning. The more comminuted column with small distal fragment was fixed using radial or ulnar precontoured locking compression plates.

The other column was fixed with another precontoured locking compression plate or locking reconstruction plates depending upon the size of distal fragment, fracture pattern and the stability of fixation. The stability of internal fixation was tested by moving the elbow through full range of motion.

The olecranon osteotomy was then reduced under direct vision and fixed by figure of '8' tension band wiring. After fixation of the osteotomy the elbow was again put through the range of motion to test the stability of fixation.

The tourniquet was released and hemostasis achieved over a negative suction drain and the wound was closed in layers. Pressure bandage was applied. Postoperative posterior POP slab was given to rest to the operated part. Supervised physiotherapy in the form of active flexion and extension at elbow was permitted by removing the POP posterior slab at elbow as soon as patient was reasonably pain free. Sutures/staples were removed on the 14<sup>th</sup> postoperative day and patient was discharged with instruction to carry out physiotherapy in the form of active flexion-extension and pronation-supination exercises without loading.

Elbow was mobilised through full range of movement at least twice daily. Patients were reviewed at monthly interval for clinical-radiological evaluation. Final outcome measures included radiological assessment, range of motion and Mayo elbow performance score (MEPS).<sup>7</sup> Result was considered excellent if the MEPS was 90 or above, good if it was between 75 and 89, fair between 60 and 74 and poor less than 60.

**RESULTS:** Twenty patients were operated and followed up to analyse their final functional outcomes. There were 12 males and 8 females with an average age of 36 years (18 to 62 years). The mode of trauma was road side accident in 12 (60%), fall from height in 6 (30%) and assault in 2 patients (10%). Majority of cases of road traffic accident were in younger age group and direct fall onto elbow was a common mode of injury in the older age group. The average delay to operation from the time of injury was 7 days (4 to 15 days).

Three patients had fracture open grade-1. There was no case with neurovascular injury.

According to AO-ASIF classification all the cases selected for the study was of type-C (Complete articular). The average follow-up period was 8 months (6 to 12 months). All the fractures were united at an average 12 weeks (8-15 weeks). Two patients developed numbness in the distribution of ulnar nerve postoperatively which resolved eventually at the end of 1 month. One patient with open fracture lower end humerus developed superficial infection in immediate postoperative period that healed with wound debridement, dressing and antibiotics. None of the patients had angular or rotational malunion and loosening of implant or implant failure. At the final follow-up average arc of flexion-extension was 105° (Range 70°-130°), although no patient had loss of supination/pronation. The mean fixed flexion deformity was 6° (Range 0°-10°) and mean flexion was 120° (Range 90°-135°). All the patients had stable elbow in antero-posterior and medio-lateral planes at the end of 6 months follow-up. The functional results were assessed by MEPS (Mayo Elbow Performance Score) and found excellent in 15(75%), good in 3(15%), fair in 1(5%) and poor in 1(5%).

**DISCUSSION:** The ORIF of intra-articular distal humeral fractures has been accepted as standard of care. Many studies have shown superior results of operative over non-operative treatment methods.<sup>7,8,9,10,11,12</sup> In spite of the fact that surgical techniques for the treatment of fractures of the distal humerus have advanced substantially over the past 20 years and now are quite sophisticated, the rate of complications remains quite high.<sup>13,14,15</sup> Such complications include nonanatomic reduction of articular surface, malunion, non-union, loosening of implant, residual stiffness of the elbow and posttraumatic osteoarthritis. Most of the above mentioned complications can be minimized by using some rigid implants such as locking plates that allow early aggressive elbow mobilization.<sup>16,17,18,19</sup>

We preferred anatomically pre-contoured distal humeral plates because it gives multiple screw options for easy application in distal complex fractures. We also used locking reconstruction plate to reconstruct the other column wherever distal fragment was sufficiently large. In our series there was no case of non-union or implant failure whereas markedly high failure rate have been reported in the literature for conventional plates especially loosening of distal screws.<sup>1,18,19</sup> In this study with the use of locking plates for the treatment of all AO type-C distal humeral (Complete articular) fractures we were able to achieve excellent to good results in 18 patients (90%), fair in 1 (5%) and poor in 1 (5%).

In this series fair-to-poor results are attributed to extensive comminution of fragments, inability to achieve congruous joint surface and prolonged immobilization. Our patients had average flexion/extension range 105° (Range 70°-130°) and full forearm rotation. Much of the elbow function was seen to be acquired within 3 months after surgery and no improvement was seen after six months. Extension at elbow was more difficult to achieve than flexion. This indicates that maximum benefit can be achieved with aggressive physiotherapy in first three months of surgery.

This can only be achieved if anatomical fracture reduction and rigid internal fixation is done by using locking plates. In our series elderly patients regained less movement, but none of them had instability or very painful or stiff elbow. Thus old age and osteoporosis is not a contraindication to operation. We have not encountered with complications described with non-locking plates like non-union, implant loosening and implant cutting out. Postoperative transient ulnar neuropraxia was reported in one patient. Superficial infection was found in one patient that recovered with regular dressing and intravenous antibiotic. Both of these complications are well below the rate reported by Kundel et al.<sup>19</sup>

**CONCLUSION:** All cases united within 12 weeks with good function and acceptable complications. Thus we can conclude that locking plates are useful implants for the treatment of complete articular (Type-C) distal humeral fractures with comminuted small distal fragments, although larger control studies with long-term follow-up may be required before advocating it for wider application.

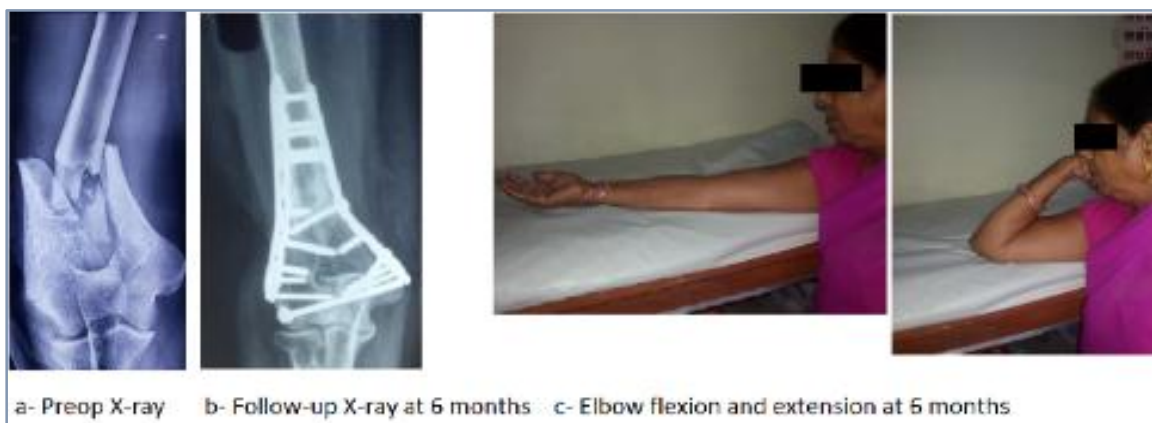MEPS	Score	No. of Patients
Excellent	>90	15
Good	75-89	3
Fair	60-74	1
Poor	<60	1

**Table 1**

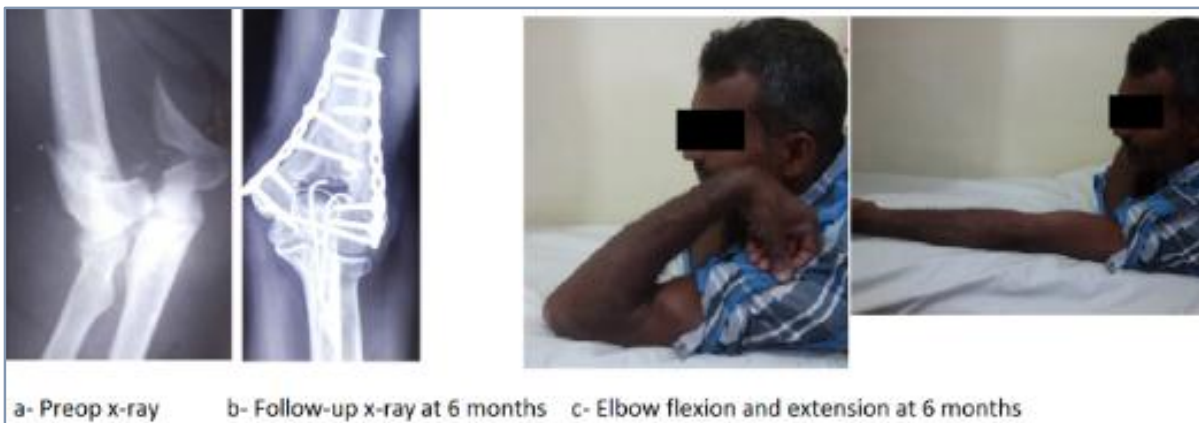**REFERENCES:**

1. Korner J, Lill H, Müller LP, Rommens PM, Schneider E, Linke B. The LCP-concept in the operative treatment of distal humerus fractures--biological, biomechanical and surgical aspects. *Injury*. 2003; 34 (Suppl 2):B20-30.
2. Galano GJ, Ahmad CS, Levine WN. Current treatment strategies for bicolunar distal humerus fractures. *J Am Acad Orthop Surg*. 2010; 18:20-30.
3. Ring D, Jupiter JB. Fractures of the distal humerus. *Orthop Clin North Am* 2000; 31(1):103-13.
4. Ilyas AM, Jupiter JB. Treatment of Distal Humerus Fractures. *Acta Chir Orthop Traumatol Cech*. 2008; 75(1):6-15.
5. Huang TL, Chiu FY, Chuang TY, et al. The results of open reduction and internal fixation in elderly patients with severe fractures of the distal humerus: a critical analysis of the results. *J Trauma* 2005; 58(1):62-9.

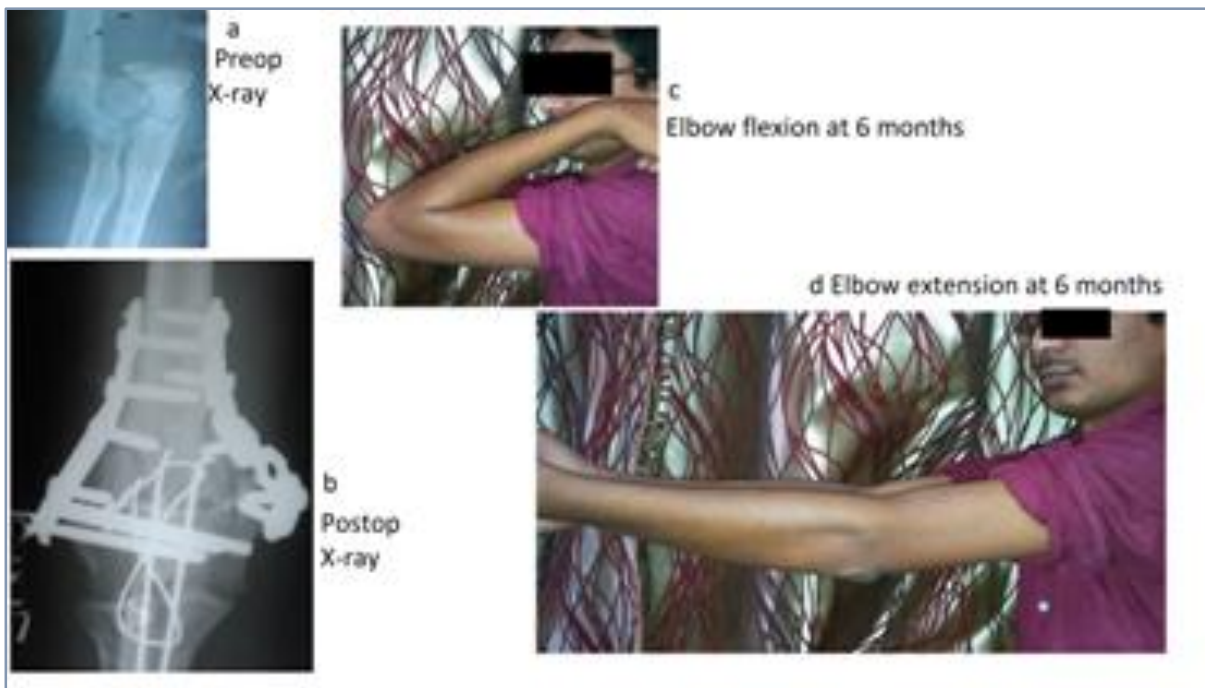
6. McKee MD, Wilson TL, Winston L, Schemitsch EH, Richards RR. Functional outcome following surgical treatment of intra-articular distal humeral fractures through a posterior approach. *J Bone Joint Surg Am*. 2000; 82-A (12):1701-07.
7. Van Gorder, G.W. Surgical approach in supracondylar "T" fractures of the humerus requiring open reduction. *J Bone Joint Surg Am*. 1940; 22:278-292.
8. Bryan RS, Bickel WH. The condylar fractures of distal humerus. *J Trauma* 1971; 11:830-835.
9. Riseborough EJ, Radin EL. Intercondylar T fractures of the humerus in the adult. A comparison of operative and non-operative treatment in twenty-nine cases. *J Bone Joint Surg Am* 1969; 51:130-141.
10. Horne G. Supracondylar fractures of the humerus in adults. *J Trauma* 1980; 20:71-74.
11. Keon-Cohen BT. Fractures at the elbow. *J Bone Joint Surg Am* 1966; 48-A: 1623-1639.
12. Miller WE. Comminuted fractures of the distal end of the humerus in the adult. *J Bone Joint Surg Am* 1964; 46:644-657.
13. Bryan RS, Morrey BF. Fractures of the Distal Humerus. In: Morrey BF, Ed. *The Elbow and Its Disorders*. Philadelphia: WB Saunders, 1985:302.
14. Holdsworth BJ, Mossad MM. Fractures of the Adult Distal Humerus. *Elbow Function after Internal Fixation*. *J Bone Joint Surg Br* 1990; 72:362.
15. Jupiter JB. Complex Fractures of the Distal Part of the Humerus and Associated Complications. *J Bone Joint Surg Am* 1994; 76:1252.
16. Doornberg JN, van Duijn PJ, Linzel D, et al. Surgical treatment of intra-articular fractures of the distal part of the humerus. Functional outcome after twelve to thirty years. *J Bone Joint Surg Am* 2007; 89(7):1524-32.
17. O'Driscoll SW. Optimizing stability in distal humeral fracture fixation. *J Shoulder Elbow Surg* 2005; 14(1 Suppl S):186S-94S.
18. McKee MD, Kim J, Kebaish K, et al. Functional outcome after open supracondylar fractures of the humerus. The effect of the surgical approach. *J Bone Joint Surg Br* 2000; 82(5):646-51.
19. Kundel K, Braun W, Wieberneit J, et al. Intraarticular distal humerus fractures. Factors affecting functional outcome. *Clin Orthop Relat Res* 1996;(332):200-8.



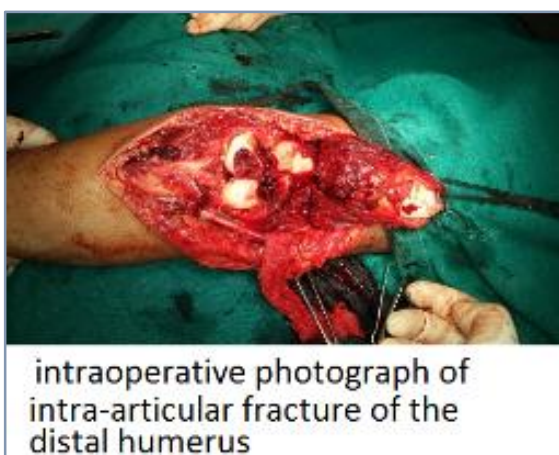**Case 1: a- Preop x-ray, b- Postop x-ray, c- Elbow flexion and extension at 6 months**



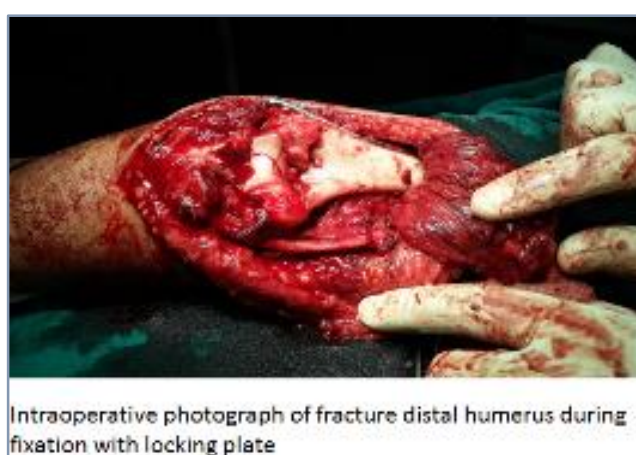*Case 2: a- Preop x-ray, b- Postop x-ray, c- Elbow flexion and extension at 6 months*



*Case 3: a- Preop x-ray, b- Postop x-ray, c & d, Elbow flexion and extension at 6 months*



**intraoperative photograph of intra-articular fracture of the distal humerus**



**Intraoperative photograph of fracture distal humerus during fixation with locking plate**