

# CASE REPORT

## ETHMOIDAL SINUSITIS WITH PRESEPTAL ABSCESS: A CASE REPORT

Vikramjit Singha<sup>1</sup>, Amar Kanti Chakma<sup>2</sup>, Gautam Biswas<sup>3</sup>, Kabita Barauh<sup>4</sup>

### HOW TO CITE THIS ARTICLE:

Vikramjit Singha, Amar Kanti Chakma, Gautam Biswas, Kabita Barauh. "Ethmoidal Sinusitis with Preseptal Abscess: A Case Report". Journal of Evolution of Medical and Dental Sciences 2014; Vol. 3, Issue 34, August 11; Page: 9068-9071, DOI: 10.14260/jemds/2014/3169

**ABSTRACT:** Complications of sinusitis are rare nowadays because of higher and broad spectrum antibiotics. Preseptal abscess may rarely present as a complication of sinusitis. Our patient presented with a preseptal abscess with underlying ethmoidal sinusitis. The patient was treated with antibiotics; Incision and drainage of the preseptal abscess were done and infection in the ethmoidal sinuses was eradicated by endoscopic sinus surgery.

**KEYWORDS:** Preseptal abscess, orbital cellulitis, ethmoidal sinusitis, endoscopic sinus surgery.

**INTRODUCTION:** Bacterial infection in the paranasal sinuses is one of the most frequent diseases both in adults and children. But due to higher and broad spectrum antibiotics, complications of sinusitis are rare nowadays. If occurs at all, complications of acute sinusitis occur more frequently in the young, and are directly linked to the intimate anatomical relations of the paranasal sinuses with the surrounding structures. Among the sinusitis complications, the ones that involve the eye region are the most frequent and usually associated with ethmoidal sinusitis involving younger patients. <sup>[1]</sup>

Chandler has classified orbital complications of sinusitis into five groups viz. Preseptal cellulitis, orbital cellulitis, subperiosteal abscess, orbital abscess and cavernous sinus thrombosis. <sup>[2]</sup>

Though common, preseptal cellulitis or abscess rarely occurs as a complication of sinusitis. Here we are presenting the case because of the rare association between preseptal abscess and sinusitis.

**CASE REPORT:** A 13 year old boy was referred from the department of ophthalmology to the department of Otorhinolaryngology with swelling of the left eye (Fig. 1). The boy presented with a chief complaint of pain and swelling of the left upper eyelid and intermittent fever for last 10 days. The patient also stated that it had become difficult to open his left eye. But there was no diminution of vision on opening the eye with hand and no pain while moving the eyeball.

On examination, there was fluctuant swelling involving the left upper eyelid almost closing the eye. There was the reddish coloration of the eyelid. Tenderness of the swelling was positive and there was local rise of temperature. There was no conjunctival chemosis and no motility restriction.

Tenderness was positive on nasal bridge and on the left medial canthus. On anterior rhinoscopy the left nasal cavity was congested and there was pus in the left middle meatus.

On ocular examination by ophthalmologist reveals- visual acuity: 6/6 both eyes, pupils: 4mm→2mm, brisk, equal, motility: normal both eyes.

Slit lamp examination reveals- conjunctiva & sclera: normal both eyes, cornea: normal both eyes, AC: no flare both eyes, lens: normal both eyes, vitreous: no cell both eyes.

CT scan PNS showed pus in the left upper lid, pus in the left ethmoidal sinuses and the left eyeball was pushed anterolaterally (Fig. 2).

## CASE REPORT

Intravenous injection Amoxyclav 1.2g twice daily, inj Diclofenac and inj Ranitidine were started. Incision & drainage were done on the next day, profuse pus was drained out and a gauze drain was put and dressing was done. Antiseptic dressing was done every day. Endoscopic sinus surgery under G.A. was done on 4<sup>th</sup> day of admission.

Endoscopically uncinectomy was done, then all the anterior ethmoidal air cells were removed along with pus from the cells, basal lamella was perforated and posterior ethmoidal air cells were removed. Left maxillary sinus clearance was accomplished by widening the maxillary sinus ostium. There was gradual improvement and total recovery (Fig. 3). The patient was discharged on the 7<sup>th</sup> postoperative day.

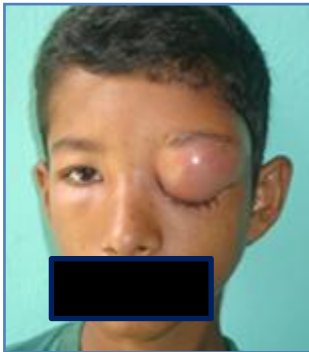

Fig. 1: Before Treatment

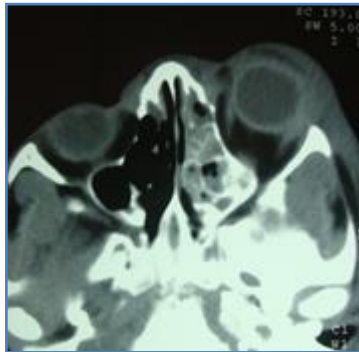


Fig. 2: CT Scan PNS

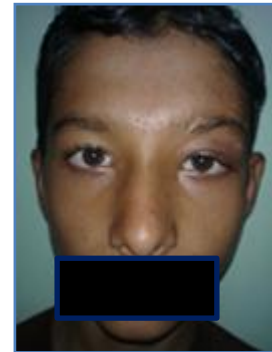

Fig. 3: After Treatment

**DISCUSSION:** The paranasal sinus infection is one of the most frequently encountered condition in medical practice and with higher, broad spectrum, and newer antibiotics the majority of cases are managed without complication. Due to the close proximity of orbit with the ethmoid, maxillary, frontal and sphenoid sinuses any sinonasal infection, if not diagnosed early and treated adequately, can lead to the spread of infection through the neurovascular foramina via congenital and acquired bony dehiscence and indirectly through the valveless ophthalmic veins draining the sinuses and orbit as a result of thrombophlebitis and embolism.<sup>[3,4,5]</sup> The erosion and destruction of the lamina papyracea provides the most common pathway for the contagious spread of sinus infection to the orbit.<sup>[3]</sup>

Preseptal cellulitis is infection of the eyelid and surrounding skin anterior to the orbital septum. This condition is more common in children than in adults.

Preseptal cellulitis is usually caused by contiguous spread of infection from local facial or eyelid injuries, insect bites, conjunctivitis and chalazion and rarely sinusitis. Preseptal cellulitis is not a common complication of sinusitis. Orbital cellulitis on the other hand may occur after trauma or intraorbital surgery, however, it is more frequently found in children as a complication of sinusitis, especially of ethmoidal sinusitis.<sup>[6,7]</sup>

The most common inciting microorganisms include streptococcus pneumoniae, staphylococcus aureus, anaerobes and haemophilus influenzae.

Symptoms and signs of preseptal cellulitis include tenderness, swelling, warmth, redness or discoloration of the eyelid and sometimes fever. Patients may be unable to open their eyes because of eyelid swelling.

## CASE REPORT

---

The swelling and discomfort can make it difficult to examine the eye, but when accomplished, examination shows that visual acuity is not affected, ocular movement is intact. Chemosis is not found in preseptal abscess.

Diagnosis of preseptal abscess is mainly by clinical evaluation. CT scan of the orbits and paranasal sinuses is essential. Evidence of sinusitis mandates otolaryngology involvement. Other disorders to consider include trauma, insect bite without cellulitis, retained foreign bodies, allergic reactions, tumours and inflammatory orbital pseudotumour.

The treatment of the complications of sinusitis require a team of different specialists, the otorhinolaryngologist taking care of the sinus infection, the ophthalmologist tending to visual complications and the paediatrician taking care of the clinical problems. Clinical treatment is based on the use of high doses of intravenous antibiotics,<sup>[1]</sup> and in some instances treatment must include surgical drainage of the pus in the affected paranasal sinus.<sup>[8,9,10]</sup>

**CONCLUSION:** Orbital complications, secondary to sinusitis in the new millennium still poses a serious threat to patients. The clinical manifestations and CT findings provide the means for making diagnostic and therapeutic decisions. The trend has shifted from conventional method to endoscopic sinus surgery as a safe and effective measure of eradication of infections from the sinuses.

### REFERENCES:

1. Neto L M, Pignatary S. Acute sinusitis in children- A retrospective study of orbital complications. *Rev Bras Otolaryngol* 2007; 73 (1): 81-5.
2. Chandler JR, Langenbrunner DJ, Stevens ER. The pathogenesis of orbital complications in acute sinusitis. *Laryngoscope*.1970 Sep; 80 (9): 1414-28.
3. Elango S, Krihshna Reddy TN. Orbital complications of acute sinusitis. *Singapore Medical Journal* 1990;31: 341-344.
4. Nwargu OGB, Awobem FJ, Onakoya PA, Awobem AA. Orbital cellulites complicating sinusitis: A 15 year review. *Nigerian journal o surgical research*. 2004; 6 (1): 14-16.
5. Younis RT, Lazar RH, Bustilo A, Anand VK. Orbital infection as a complication of sinusitis: are diagnostic and treatment trends changing? *Ear Nose Throat J*. 2002 Nov; 81 (11): 771-5.
6. Hawkins DB, Clark RW. Orbital involvement in acute sinusitis. Lessons from 24 childhood patients. *Clin Pediatr (Phila)* 1977; 16: 464-71.
7. Rubinstein JB, Handler SD. Orbital and periorbital cellulitis in children. *Head Neck Surg* 1982; 5: 15-21.
8. Weizman Z, Mussai H, Ethmoiditis associated periorbital cellulitis. *Int J Pediatr Otorhinolaryngol* 1986; 11: 147-51.
9. Welsh I. W, Welsh JJ. Orbital complications o ethmoiditis. *Otolaryngol Clin North Am* 1985; 18: 139-47.
10. Wald ER. Acute sinusitis and orbital complications in children. *Am J Otolaryngol* 1983; 4: 424-7.

## CASE REPORT

---

### **AUTHORS:**

1. Vikramjit Singha
2. Amar Kanti Chakma
3. Gautam Biswas
4. Kabita Barauh

### **PARTICULARS OF CONTRIBUTORS:**

1. Assistant Professor, Department of ENT, Tripura Medical College & Dr. BRAM Teaching Hospital, Hapania, Agartala.
2. Associate Professor, Department of Ophthalmology, Tripura Medical College, Hapania, Agartala.
3. Professor, Department of Ophthalmology, Tripura Medical College, Agartala.
4. Professor and HOD, Department of ENT, Tripura Medical College, Hapania, Agartala.

### **NAME ADDRESS EMAIL ID OF THE CORRESPONDING AUTHOR:**

Dr. Vikramjit Singha,  
Department of ENT,  
Tripura Medical College &  
Dr. BRAM Teaching Hospital,  
Hapania, Agartala-14.  
Email: vjtmc2011@gmail.com

Date of Submission: 23/07/2014.

Date of Peer Review: 24/07/2014.

Date of Acceptance: 05/08/2014.

Date of Publishing: 09/08/2014.