

EVALUATION OF HRCT TEMPORAL BONE AND PATHOLOGIESR. Vivek¹, P. Gunasekaran², S. Sethurajan³, M. Adaikappan⁴**HOW TO CITE THIS ARTICLE:**

R. Vivek, P. Gunasekaran, S. Sethurajan, M. Adaikappan. "Evaluation of HRCT Temporal Bone and Pathologies". Journal of Evolution of Medical and Dental Sciences 2014; Vol. 3, Issue 52, October 13; Page: 12118-12126, DOI: 10.14260/jemds/2014/3600

ABSTRACT: AIM: To assess the role of High Resolution Computer Tomography as the prime modality in the diagnosis and characterization of lesions of the temporal bone. **METHODOLOGY:** Patients presenting with symptoms and clinical features suggestive of lesion involving temporal bone were included in the study. **RESULTS:** High Resolution Computed Tomography was highly sensitive and specific in evaluating lesions like mastoiditis, cholesteatoma, paragangliomas, cerebello pontine meningiomas and fractures. **CONCLUSION:** High Resolution Computed Tomography is the imaging modality of choice in evaluation of the temporal bone which is a relatively inaccessible area of the human anatomy. By using an orthogonal plane of 30° we are able to reduce the radiation to the eye with no compromise in the image quality. It also dictates proper and adequate medical treatment or timely surgery that can prevent further serious complications. High Resolution Computed Tomography has abled in planning more direct procedures like cochlear implantation, avoiding fatal surgical interventions on aberrant ICA etc, while preserving function of the essential structures of Temporal bone thereby making HRCT a valuable tool in diagnosis and treatment.

KEYWORDS: High Resolution Computed Tomography, Temporal bone, Cholesteatoma, Mastoiditis.

INTRODUCTION: A major advance in diagnostic imaging has occurred with the introduction of High Resolution computed Tomography which have made it possible to obtain high quality images with exquisite demonstration of most normal temporal bone structures and numerous pathological processes.

High resolution computed tomography provides excellent of bony land marks within the temporal bone, due to the temporal bone inherent contrast, its dense bone being surrounded by air of the tympanic cavity and mastoid air cells. It has also added whole new dimension to the temporal bone by allowing visualization of the of the tissue components within and adjacent to the temporal bone.

Because high resolution computed tomography can assess this area with unprecedented accuracy, it has allowed better understanding of the etiology, pathology, the disease course earlier detection of complications and treatment modality which has considerably reduced the morbidity and mortality pertaining to lesions of this region.

MATERIALS & METHODS: A total of 50 patients of whom 30 were males and 20 were females were studied. Age group varied from 5 to 75 years. Patients were selected from outpatient clinics and wards of Department of Otolaryngology RMMCH Chidambaram. Patients were selected on the basis of their symptoms and clinical findings suggestive of a lesion involving the temporal bone such as otalgia, otorrhoea and sensorineuronal deafness, pulsatile tinnitus, vertigo and giddiness. All the examinations were performed on a Philips mx 8000 Computed Tomographic scanner.

ORIGINAL ARTICLE

Patients were scanned in two plane one axial at 30 degree with the patient place supine with head flexed and the scan plane passing through the external auditory canal and superior orbital rim. Coronal sections were performed with the patient placed prone with neck maximally extended. The scan plane was oriented to intersect the external auditory canal parallel to the posterior margin of the maxillary sinus.

Thickness of the slices were 2 mm, Table increments 2mm, Tube voltage 120 KV, Tube current 440 mAs, Scan time 2.7 sec, magnification factor of 1.7 to 2 used for visualization of both temporal bones. Magnification factor of 3.5 used for evaluating a single temporal bone in great detail. IV contrast administered in suspected intracranial extension. Contrast enhanced lesions visualized in soft tissue window using raw data process.

Reconstructed images were viewed using a window length of 400 and a wide window of maximum possible. The features evaluated were site, size, characterization, involvement of adjacent structures, vascular involvement.

RESULTS: Our study included 50 patients in the age group of 5 to 75 with the mean age of 30-35 years with a male: female 1.7:1 with greater number of patients in age group of 20-40 years. Common symptoms included otorrhoea 58.33% followed by otalgia, features of raised intracranial tension and fever with percentage incidence of each being 43.43%, 40% and 38.33% respectively and deafness 36.66%. 34.68 % of cases had acute mastoiditis, 17.22% of cases had coalescent mastoiditis, 48.10% of cases had chronic mastoiditis. 100% of cases of cholesteatoma were of acquired type of which attico-antral 30.78%, tubo-tympanic 15.38% and extensive 53.84%. Cochlear erosion was seen in 1.69%, lateral semicircular canal erosion in 1.69% and facial nerve canal erosion in 30.76% of cases. Longitudinal fractures were seen in 40%, atypical fractures in 40% and complex fractures in 20% of cases.

DISCUSSION: High resolution computed tomography provides exquisite details of the bony landmarks within the temporal bone and has added a whole new dimension to evaluation of the temporal bone by allowing the visualization the soft tissue components within and adjacent to the temporal bone.

FRACTURES: High Resolution Computed Tomography helps in identifying the fracture line and its complications. Longitudinal and transverse components are complex fractures and fractures only partially involving the petrous or mastoid are a typical fractures. Longitudinal fractures constitute the majority of temporal bone fractures and occurs due to direct blow to the temporal or parietal areas. They course through the external auditory canal, through the geniculate ganglion region and end in the fibrous tissue of Foramen Lacerum.

Transverse fractures occur due to blow to the frontal or parietal areas and are of two types. In the lateral type the fractures line passes through the vestibule or cochlea and in the medial type the fractures line passes medial to the otic capsule through the Internal Auditory Canal fundus. Ossicular lesions commonly associated with temporal bone fractures include incudo-malleolar subluxation, fractures of stapes crura, incus long process and neck of malleus.

Facial nerve injury commonly involves geniculate ganglion region in longitudinal fractures and labyrinthine portion in transverse fractures. Otorrhino-liquorrhoea results from disruption of dura in tegmen tympani region.

ORIGINAL ARTICLE

CHOLESTEATOMA^[1]: It is a sack of stratified squamous epithelium filled with exfoliated keratin that is trapped and growing within the tympanic cavity or other pneumatized areas of the petrous bone or more simply "skin in the wrong place" The term cholesteatoma is a misnomer as it is not a tumor and doesn't always contain cholesterol. There are two types of cholesteatoma congenital (2%) and acquired (98%).^[2]

CONGENITAL: Cholesteatoma found behind an intact tympanic membrane in a patient with no H/o otitis media is congenital cholesteatoma. It occurs at five sites in the temporal bone the petrous apex, mastoid, middle ear, middle ear and mastoid and External Auditory canal. **ACQUIRED:** These lesions arise from either pars tensa or pars flaccida. It is more invasive in children.^[3] Cholesteatomas can produce many complications as bone erosion, ossicular erosions, meningitis, cerebral and cerebellar abscess, sinus thrombosis.^[4]

GRADENIGO'S SYNDROME: Infection of the petrous apex air cells with deep pain along V Nerve distribution, VI Nerve palsy with otorrhoea.

MALIGNANT OTITIS EXTERNA: Usually due to pseudomonas infection of the soft tissues External auditory canal occurring in elderly diabetics or immuno compromised patient which can produce rapid bone destruction and soft tissue extension into naso-pharynx, neck (Bezold's abscess) and intracranial extension with serious threat to life.

GRANULATION TISSUE AND CHOLESTEROL GRANULOMA: It is a complication of chronic infection and manifests in 3 ways-soft, fibrous and cholesterol granuloma. It is friable and produces haemotympanum which produces blue tympanic clinically.

BENIGN NEOPLASMS: Acoustic neuromas comprise about 80% of all masses of Cerebello Pontine angle masses. They arise at the junction of neuroglial and Schwann cell sheaths commonly near the porus acuticus. Bilateral lesions are pathognomonic of Neurofibromatosis II. Neuromas at the Cerebello - Pontine angle and petrous temporal region can also arise from V, VII, IX Nerves etc. Meningiomas arise from the meninges covering the posterior petrous bone and may subsequently invade the temporal bone.

The Internal auditory canal is usually not affected. They may produce hyperostosis of the adjacent temporal bone.^[5,6,7] Glomus tumors or Paragangliomas are slow growing purplish red vascular tumors that are of mesenchymal or neuroectodermal origin. They arise from chemoreceptor cells that accompany Arnold's or Jacobson's Nerve and found in the middle ear or upper portion of jugular bulb or in both regions when they are called Glomus tympanicum. Glomus jugulare and Glomus jugulo-tympanicum respectively.^[8]

MALIGNANT LESIONS: PRIMARY MALIGNANCIES: Cancer of the ear arising in the external auditory meatus, middle ear cleft or in a mastoid cavity is a rare disease. Squamous cell carcinoma is the commonest but basal cell carcinoma, Adeno carcinoma and adenoid cystic carcinoma, lymphoma, melanoma can occur as well. Patients often have a history of chronic external otitis and present with bloody discharge, dizziness, deafness, VII nerve palsy.

ORIGINAL ARTICLE

METASTASIS: Metastasis to the temporal bone can be by direct extension or haematogenous extension. Haematogenous extension can be from breast, kidney or lung. Direct spread occurs commonly from salivary gland, nasopharyngeal or sellar masses.

POST SURGICAL EAR-MASTOIDECTOMY^[10]: Mastoidectomy can be divided into closed cavity and open cavity. In closed cavity surgery the posterior canal wall is left intact. In the open cavity types the posterior external auditory canal walls are removed to create a permanent cavity. Closed cavity type surgeries include the simple cortical mastoidectomy and intact canal wall mastoidectomy which includes tympanoplasty and inspection middle ear structures.

Open cavity type surgeries include the Radical mastoidectomy in which tympanic membrane remnants and the ossicular chain are removed and the Modified Radical Mastoidectomy in which there is meticulous preservation or reconstruction of middle ear structures. It also dictates proper and adequate medical treatment or timely surgery that can prevent further serious complications.

High Resolution Computed Tomography has abled in planning more direct procedures like cochlear implantation, avoiding fatal surgical interventions on aberrant ICA etc, while preserving function of the essential structures of the Temporal bone thereby making HRCT a valuable tool in diagnosis and treatment. Hence High Resolution Computed Tomography has helped to define accurate planes that enable the diagnosis, characterization and treatment of pathological processes affecting the temporal bone.

Age Chart:

AGE	No. of cases	% CASES
0-10	2	5.00
10-20	10	18.33
21-30	15	30.08
31-40	14	28.33
41-50	5	10.00
51-60	2	5.00
61-70	1	1.60
71-80	1	1.66

Mean age: 30.95

Commonest age group: 21-40 years

Younger patients (less than 40 years) more commonly affected than older age group patients.

Sex Distribution

No of males: 32 (64%)

No of females: 18 (36%)

ORIGINAL ARTICLE

AGE GROUP (YEARS)	No. of cases	% MALES	No. of cases	% FEMALES
0-10	1	1.66%	2	3.32%
10-20	6	13.33%	5	11.66%
21-30	11	21.17%	4	8.33%
31-40	8	15.00%	3	7.33%
41-50	3	6.64%	2	3.32%
51-60	1	1.66%	2	3.32%
61-70	1	1.66%		
71-80	1	1.66%		

Majority of cases were males.

Males: Females: 1. 7: 1

CHOLESTEATOMA:

ACQUIRED TYPE: 100%

TOTAL NO. OF CASES: 20

REGION OF INVOLVEMENT	No. of cases	PERCENTAGE
ATTICO-ANTRAL	6	30.78
TUBO-TYMPANIC	3	15.38
EXTENSIVE	11	53.84

In our study of all acquired types attico-antral was seen in 30.78%, tubo-tympanic in 15.38% and extensive in 53.84%.

COMPLICATIONS:

INTRA-CRANIAL COMPLICATION	No. of cases	PERCENTAGE
MENINGITIS	11	23.07
EPIDURAL ABSCESS	4	7.69
CAROTID CANAL IRREGULARITY ie IRREGULARITY	4	7.69

In our study meningitis accounted for 23.07% of all cases with complication.

INFECTIONS:

TYPE	No of cases	PERCENTAGE OCCURRENCE
MASTOIDITIS	13	39.13
CHOLESTEATOMA	20	56.52
GRANULATION	2	4.35

ORIGINAL ARTICLE

In all cases with infections, cholesteatoma was seen in 56.52%, mastoiditis in 39.13% and granulation in 4.35%.

MASTOIDITIS:

Total no. of cases: 13

TYPE	No. of cases	PERCENTAGE OCCURRENCE
ACUTE	5	34.68
COALESCENT	2	17.22
CHRONIC	6	48.10

In all cases of mastoiditis, chronic type was seen in 48.10%, acute type in 34.68% and coalescent in 17.22%.

FRACTURES:

Total no of cases: 10

TYPE	No. of cases	PERCENTAGE OCCURRENCE
LONGITUDINAL	4	40
ATYPICAL	4	40
COMPLEX	2	20

In our study of all fractures, longitudinal fracture was seen in 40%, atypical fracture in 40% and complex fractures in 20%.

Figure 1: HRCT Temporal boan scan Axial section showing fluid collection in left mastoid and middle ear cavity with no evidence of bony destruction or remodeling suggestive of acute mastoiditis on Left side.

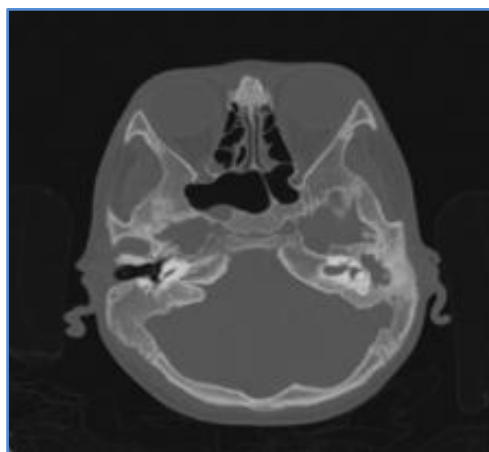


Figure 1

ORIGINAL ARTICLE

Figure 2: HRCT Temporal bone scan Axial section showing longitudinal fracture involving right mastoid bone with middle ear fluid collection.

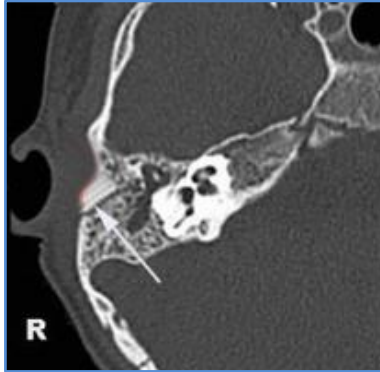

Figure 2

Figure 3: NECT Axial section showing a well-defined hyper dense extra axial lesion noted in the right cerebellopontine angle and was diagnosed as CP angle Meningioma biopsy proven.

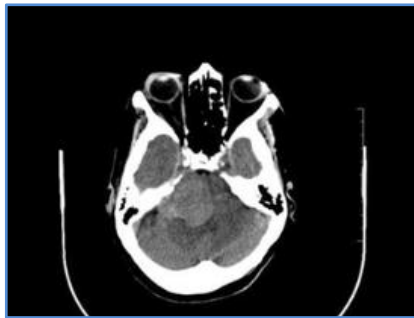

Figure 3

Figure 4: HRCT Temporal bone coronal sections showing hypo dense mass lesion in left middle ear cavity with evidence of fluid collection in mastoid air cells and bone destruction suggestive of left side cholesteatoma.

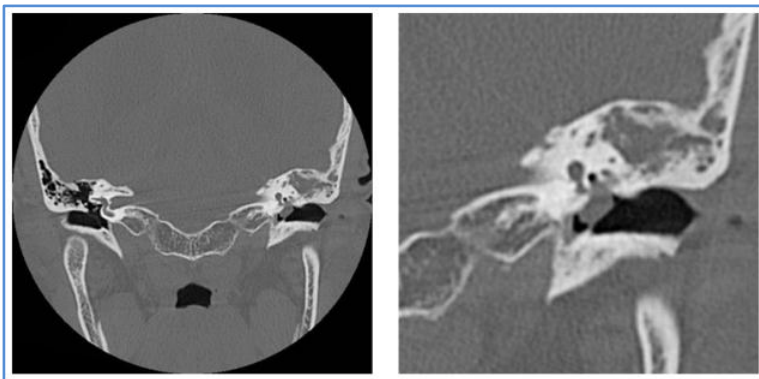

Figure 4

ORIGINAL ARTICLE

Figure 5: NECT Axial section showing a Lobulated soft tissue in hypotympanum of right middle ear.

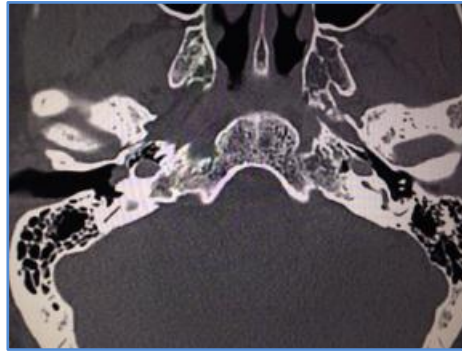


Figure 5

Figure 6: CECT Axial section showing showing enhancement of the lobulated soft tissue suggestive of glomus tympanicum tumor in right middle ear.

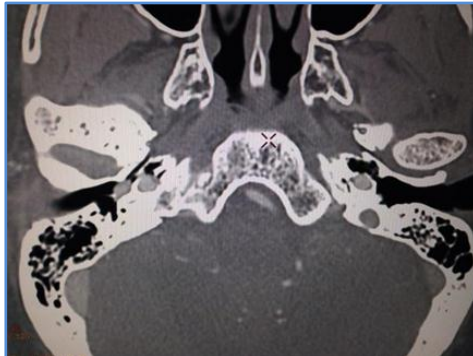


Figure 6

REFERENCES:

1. D Phelps and Lloyd. The radiology of cholesteatoma. *Clinic Radiology* 31, 501-512.1980.
2. Mahmood F Mafee et al. CT of the middle ear in evaluation of cholesteatoma and other soft tissue masses. *Radiology* 148: 465-472 1983.
3. Dexter W Johnson et al. Cholesteatomas of temporal bone. *Role of CT Radiology*, 148: 733-737, 1983.
4. Joel D Swartz. Cholesteatomas of middle ear. *Radiologic Clinics of North America* vol.22, no. 1, 1984.
5. Col. James E Olson, Maj. Robert H Dorwart, Itc. William E Brant. Use of high resolution thin section ct scanning of the petrous bone. *Temporal Bone Anomalies* 92, 1274-1278, 1982.
6. Donald W Chakeres, Peter K Spiegel. A systematic technique for comprehensive evaluation of temporal bone for CT. *Radiology* 146, 97-106, 1983.
7. Joel D Swartz. High resolution CT of the middle ear and mastoid. *Radiology* 148: 449-464, 1983.
8. Valavanis O Shubiger, M Oguz. HRCT of non chromaffin paragangliomas of temporal bone. *AJNR* 4: 516-519, 1983.

ORIGINAL ARTICLE

9. William W.M Lo, Livia G. Solti Boham. Post-surgical evaluation of temporal bone. Radiology 150: 743-747, 1984.

AUTHORS:

1. R. Vivek
2. P. Gunasekaran
3. S. Sethurajan
4. M. Adaikappan

PARTICULARS OF CONTRIBUTORS:

1. Final Year Resident, Department of Radio-Diagnosis, Rajah Muthiah Medical College.
2. Assistant Professor, Department of Radio-Diagnosis, Rajah Muthiah Medical College.
3. Assistant Professor, Department of Radio-Diagnosis, Rajah Muthiah Medical College.
4. Professor, Department of Radio-Diagnosis, Rajah Muthiah Medical College.

NAME ADDRESS EMAIL ID OF THE CORRESPONDING AUTHOR:

Dr. R. Vivek,
S2/1, Sugham Apartments,
Pinkys Restaurant,
OP Main Road, Annamalai Nagar,
Chidambaram-608002.
Email: vivekdocsrmc@gmail.com

Date of Submission: 24/09/2014.
Date of Peer Review: 25/09/2014.
Date of Acceptance: 08/10/2014.
Date of Publishing: 10/10/2014.