

**ADULT ONSET ACUTE OTITIS MEDIA - A PRELIMINARY REPORT**Mukta Pagrani<sup>1</sup>, Abhinav Srivastava<sup>2</sup>, Chander Mohan<sup>3</sup>**HOW TO CITE THIS ARTICLE:**

Mukta Pagrani, Abhinav Srivastava, Chander Mohan. "Adult Onset Acute Otitis Media - A Preliminary Report". Journal of Evolution of Medical and Dental Sciences 2014; Vol. 3, Issue 19, May 12; Page: 5094-5099, DOI: 10.14260/jemds/2014/2559

**ABSTRACT:** Acute otitis media is a common disease of children with typical symptomatology & is not infrequent in adults. Literature available on adult acute otitis media is limited. This study has been carried out to assess the presentation, progression & outcome of disease in adults. 90 patients presenting with signs & symptoms consistent with acute otitis media were examined, evaluated & followed up. Earache was the commonest symptom present in 65 patients. Spontaneous perforation was present in 37 patients. Earache, ear discharge & hearing loss are the commonest symptoms in adults & rate of spontaneous perforation is higher compared to children.

**KEYWORDS:** Acute Otitis Media, Otorrhoea, Mastoiditis, Labyrinthitis.

**INTRODUCTION:** Acute Otitis Media is one of the commonest infections of the mucosal lining of middle ear cleft. Adults make up less than 20% of patients presenting with acute otitis media.<sup>[1]</sup> In a prospective study of patients (n = 3224) seen in primary care with symptoms & signs consistent with acute otitis media in eight developed countries, adult population was 16% of the total, making it not infrequent in otherwise healthy adults.<sup>1</sup> This disease is common in children. By the age of 3 months, 10% of the children will have suffered at least one episode of AOM.<sup>2</sup> Extensive literature is available on AOM in children but is sparse in case of adults. How much of the pediatric literature is translatable to adults is unknown.<sup>3</sup>

**MATERIAL & METHODS:** This cross-sectional study was conducted in the Department of ENT, Rohilkhand Medical College & Hospital, Bareilly and 90 consecutive adult patients presenting in OPD with signs & symptoms consistent with acute otitis media were included in this study. The diagnosing criteria adopted were same as for children.<sup>3</sup> Thorough history was taken & complete ear, nose, throat examination of all the patients was done.

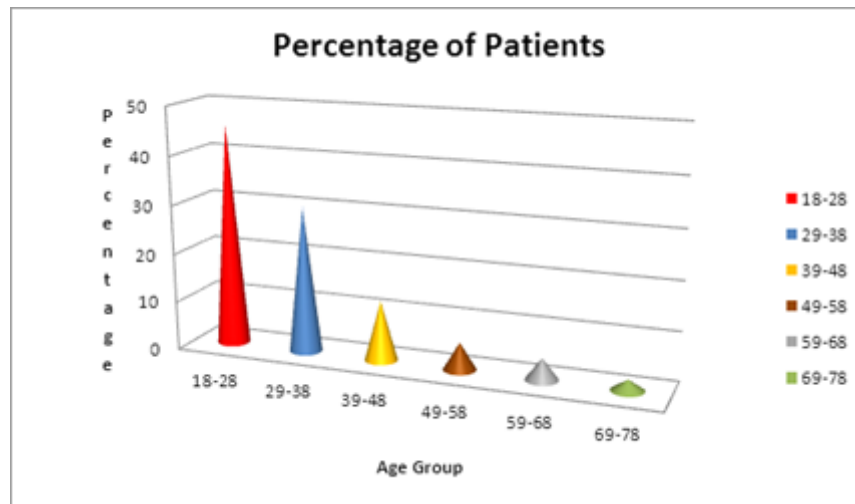
General symptoms like Fever, Irritability & Gastrointestinal symptoms & local symptoms of (1) Cold (2) Earache (3) Hearing Impairment (4) Ear Discharge (5) Retro Auricular pain (6) Tinnitus (7) Vertigo & (8) Facial Asymmetry were considered to be diagnostic of AOM.

**RESULTS:** 90 adult patients between the age group of 18 to 79 were included in this study. The youngest was 18 & oldest 73 years of age. Forty One patients, which accounted for 47.78% were in the age group of 18 to 28 years. There were 63 females (70%) and 27 males (30%). [Table 1]

## ORIGINAL ARTICLE

Age Group	Number	Males	Females
18-28	41(45.56%)	7	34
29-38	27(30.00%)	12	15
39-48	11(12.22%)	5	6
49-58	5(5.55%)	2	3
59-68	4(4.44%)	1	3
69-78	2(2.22%)	0	2

**Table 1: Age & sex distribution**

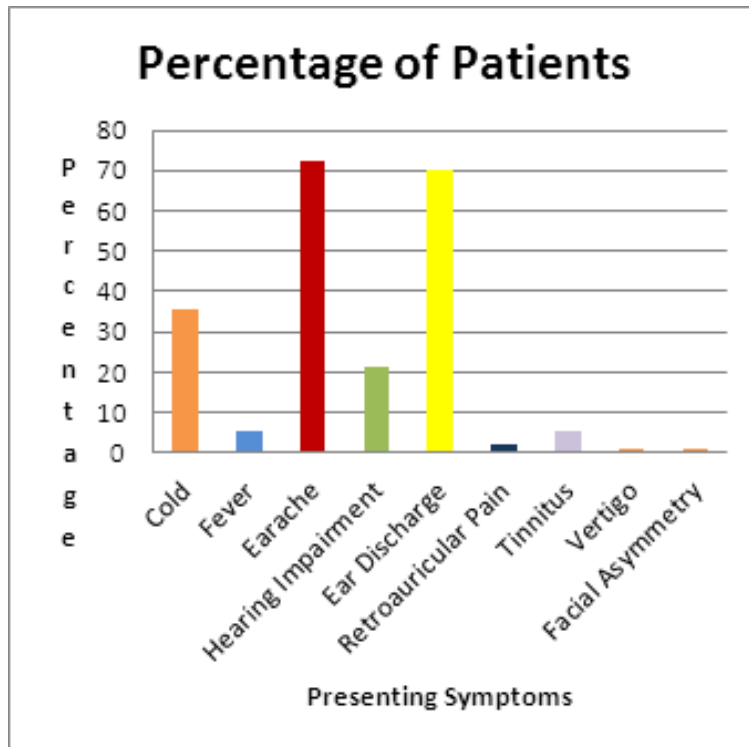


Earache was the commonest symptom in 65 patients (72.22%) followed by ear discharge in 63 Patients (70%). One patient (1.11%) presented with ipsilateral Lower Motor Neuron (LMN) facial palsy. Two patients (2.22%) had associated acute mastoiditis & one patient (1.11%) presented with labyrinthitis. Nasal obstruction was the complaint of 6 patients. 7 patients also had CSOM in the other ear. 32 patients (35.56%) gave history of an episode of cold, on an average one week prior to appearance of ear symptoms. [Table 2]

Symptom	Number	Percentage
Cold	32	35.56%
Fever	5	5.56%
Earache	65	72.22%
Hearing impairment	19	21.11%
Ear discharge	63	70%
Retro auricular pain	2	2.22%
Tinnitus	5	5.56%
Vertigo	1	1.11%
Facial asymmetry	1	1.11%

**Table 2: Symptoms of Acute otitis media in adults**

## ORIGINAL ARTICLE

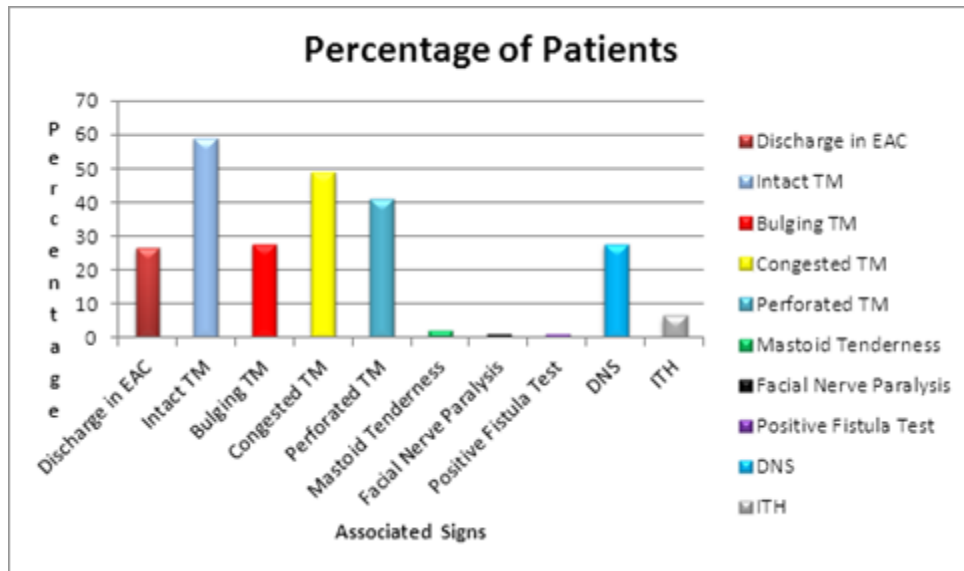


24 patients (26.66%) presented with active otorrhoea on first visit. Congested tympanic membrane was seen in 44 ears (48.89%) & bulging in 25 ears (27.78%). Spontaneous perforation was seen in 37 cases (41.11%). Anteroinferior quadrant of tympanic membrane was the commonest site (62.5%) of perforation. 4 ears developed perforation during the course of treatment. [Table3]

Signs	Number of patients	Percentage
Discharge in external auditory canal	24	26.66%
Intact TM	53	58.89%
Bulging TM	25	27.78%
Congested TM	44	48.89%
Perforated TM	37	41.11%
Mastoid Tenderness	2	2.22%
Facial nerve paralysis	1	1.11%
Positive fistula test	1	1.11%
Associated DNS	25	27.78%
Inferior turbinate hypertrophy	6	6.67%

Table 3: Signs of Acute otitis media in adults

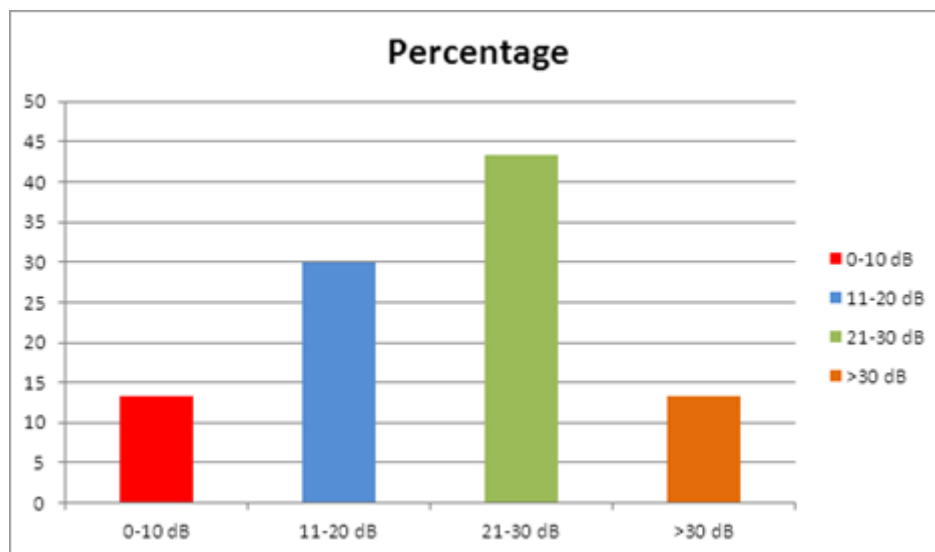
## ORIGINAL ARTICLE



Audiometric results – The air- bone gap between 21-30 dB was found in 39 ears (Table 4).<sup>4</sup> Mixed hearing loss was found in the patient who developed labyrinthitis.

Air-bone Gap	Number	Percentage
0-10	12	13.33%
11-20	27	30%
21-30	39	43.33%
>30	12	13.33%

**Table 4: Hearing loss in acute otitis media**



## ORIGINAL ARTICLE

---

**DISCUSSION:** Acute otitis media has been studied widely in case of children but little information is available on adult acute otitis media. This is a prospective study done with the objective of assessing the clinical features & disease outcome of acute otitis media in adults. The parameters included were same as for children. 90 consecutive patients attending ENT OPD of RMCH, Bareilly were included in the study.

Culpepper et al. reported that adults were more likely to complain of ear pain, decreased hearing, sore throat & ear discharge.<sup>1</sup> In our study also earache was the commonest symptom (72.22%), followed by ear discharge (70%). They also found that in comparison to adults, children frequently presented with history of recent upper respiratory tract infection, symptoms of fever & diarrhea.<sup>1</sup> In our study 32 subjects (35.56%) presented with history of recent cold & five (5.5%) with history of fever. None of the patient had gastrointestinal symptoms.

De Zinis et al. reported acute mastoiditis as the commonest complication at 83% followed by facial nerve paralysis at 30%.<sup>5</sup> They also stated that full recovery of the facial nerve is to be expected irrespective of the management. The complications of AOM observed in the present study were ipsilateral lower motor neuron facial nerve paralysis (1 case), two patients had acute mastoiditis & one had labyrinthitis. All the patients with complications recovered with medical treatment. The patient with labyrinthitis had residual mixed hearing loss.

Vanzuijlen et al. in a study to substantiate the suggestion that restrictive use of antibiotics leads to higher incidence of acute mastoiditis, concluded that incidence of acute mastoiditis in Netherlands was higher (3.5/1 lakh person year) compared to countries with higher antibiotic prescription rates (1.2 to 2/ lakh person year).<sup>6</sup> In the present study antibiotics were prescribed to patient's presenting with pain & bulging or congested tympanic membrane, active otorrhea or with complications.

Pukender et al. reported spontaneous perforation in 4.6% of cases in AOM among children.<sup>7</sup> In the study on adult AOM by Culpepper et al. 10% of the patients had spontaneous perforation.<sup>1</sup> In this study 37 cases (41.11%) had spontaneous perforation.

Tympanic membrane perforation is the commonest complication of acute otitis media & typically occurs in posterior half of the pars tensa. In the present study anteroinferior quadrant was the commonest site (62.5%).<sup>8</sup>

Culpepper et al. also found a poor outcome of disease with an increasing number of past episodes & increasing age.<sup>1</sup> In our study 17 (46%) perforations healed spontaneously & 20 (54%) became chronic in spite of the presenting episode being the only episode suffered by the patient.

**CONCLUSION:** Adults with AOM commonly present with earache, ear discharge & diminished hearing. The percentage of spontaneous perforation is higher in comparison with children & spontaneous healing of perforation is poorer than in children. More females presented with AOM compared to males.

### REFERENCES:

1. Culpepper L, Fromm J, Bartelds A, Bowers P, Bridges-Webb C, Grob P. Acute otitis media in adults: A Report the International Primary Care Network. *Journal of the American Board Practice* 1993; 6:333-9.

## ORIGINAL ARTICLE

2. Del Mar C, Glasziou P, Havem M. Are antibiotics indicated as initial treatment for children with acute otitis media? A meta-analysis. *BMJ* 1997; 314:1526.
3. Nederlands Huisartsen Genootschap (The Dutch College of General Practitioners). Acute otitis media 1992; 1-7.
4. Dowes PJD. Tympanoplasty reporting hearing results and hearing objective. *Clin Otolaryngol* 2004; 29: 612-617.
5. De Zinis R, Luca O, Gamba P, Balzanelle C. Acute Otitis Media And Facial Nerve Paralysis in Adults. *Otology and otoneurology* 2003; 24:113-7.
6. Van zuijlen, DiederickA, Schilder, Anne G.M et al. National differences in incidence of acute mastoiditis: relationship to prescribing patterns of antibiotics for acute otitis media? *Paediatric Infectious Disease Journal* 2001; 20: 140-144.
7. J Pukander. Clinical Features of Acute Otitis Media Among Children. *Acta Oto-laryngologica* 1983, Vol. 95, No. 1-4, Pages 117-122.
8. Rea P, Graham J. Acute otitis media in children. Gleeson M. Scott Brown's otorhinolaryngology, Head & Neck Surgery Vol. 1. 7<sup>th</sup> ed. Hodder Arnold; 2008. 921-922.

### AUTHORS:

1. Mukta Pagrani
2. Abhinav Srivastava
3. Chander Mohan

### PARTICULARS OF CONTRIBUTORS:

1. Assistant Professor, Department of E.N.T, Rohilkhand Medical College and Hospital, Bareilly, U. P, India.
2. Assistant Professor, Department of E.N.T, Rohilkhand Medical College and Hospital, Bareilly, U. P, India.
3. Professor and Head, Department of E.N.T, Rohilkhand Medical College and Hospital, Bareilly, U. P, India.

### NAME ADDRESS EMAIL ID OF THE CORRESPONDING AUTHOR:

Dr. Abhinav Srivastava,  
Assistant Professor,  
Department of ENT,  
Rohilkhand Medical College and Hospital,  
Bareilly, U. P., India.  
E-mail: drabhinav.srivastava@yahoo.co.in

Date of Submission: 18/04/2014.  
Date of Peer Review: 19/04/2014.  
Date of Acceptance: 24/04/2014.  
Date of Publishing: 06/05/2014.