

CASE REPORT

ANAESTHETIC MANAGEMENT IN A PATIENT WITH ARNOLD-CHIARI MALFORMATION TYPE I AND SYRINGOMYELIA

Kartika Balaji, R. Pratap, G. Vijayalaxmi, P. Kalyan Chakravarthy, J. Nagaraju

1. Senior Resident. Department of Anaesthesiology & Critical Care, GSL. Medical College. Rajahmundry.
2. Professor & HOD. Department of Anaesthesiology & Critical Care, GSL. Medical College. Rajahmundry.
3. Professor. Department of Cardiac Anaesthesiology, GSL. Medical College. Rajahmundry.
4. Assistant Professor. Department of Anaesthesiology, GSL. Medical College. Rajahmundry.
5. Post Graduate. Department of Anaesthesiology, GSL. Medical College. Rajahmundry.

CORRESPONDING AUTHOR:

Dr. S. Kartika Balaji,
Department of anaesthesia,
GSL Medical College, Lakshmipuram,
Rajahmundry.
E-mail: kartik1414@gmail.com

ABSTRACT: Syringomyelia is an unusual neurological condition characterised by the presence of cystic cavity in the spinal cord resulting in neurological manifestations. Here, we report a safe anesthetic management of patient with Arnold-Chiari malformation type I and syringomyelia posted for foramen magnum decompression.

INTRODUCTION: Arnold-Chiari malformation (ACM) is a developmental malformation characterised by downward displacement of cerebellar tonsils into spinal canal due to reduced capacity of the posterior fossa. ACM may be complicated by other malformations like Platybasia, basilar invagination and occipitalization although Syringomyelia (SM) is most commonly seen. [1] There are four types of ACM; types I – IV. Type I ACM manifests with headaches, neck pain, and mild co-ordination problems mostly asymptomatic and discovered on brain or cervical spine MRI scans. It has adult onset characterised by downward displacement of cerebellar tonsils and medulla through the foramen magnum. [2]

Syringomyelia is an unusual neurological condition characterised by the presence of fluid filled cystic cavity or syrinx within the spinal cord. Ollivies d' Angers (1827) coined the term syringomyelia from two greek words meaning "channel" and "marroin". [3] It has a prevalence of 8.4 per 100,000 and occurs more frequently in men than in women in the third or fourth decade of life. Rarely, it may develop in childhood or late adulthood. [4]

KEYWORDS: Arnold-Chiari malformations, Syringomyelia, Foramen magnum decompression
General anesthesia

CASE REPORT: A 32year-old woman came with complaints of weakness of bilateral upper and lower limbs since 3months; Paraesthesia of bilateral upper and lower limbs since 3 months and a history of headache since 1 month. Patient was conscious, coherent, well oriented to time and place with Glasgow coma scale (GCS) of 15/15. After thorough evaluation, MRI scan patient was diagnosed to have syringomyelia with ACM I. After preanesthetic evaluation, with informed consent patient was taken up for surgery.

Upon arrival at the operating theatre, intravenous access (IV) was secured via 18 gauze cannula. Monitoring with pulse oximetry, ECG and invasive blood pressure (IBP) was started.

CASE REPORT

For measurement of IBP, left radial artery was cannulated after performing modified Allens test. Premedication with 0.2mg glycopyrrolate, 4mg ondansetron, 50mg ranitidine hydrochloride, 2mg midazolam, 2mg butorphanol was given. The patient was pre-oxygenated for 3 minutes. Anesthesia was induced with thiopentone sodium 300mg IV and muscle relaxation achieved with vecuronium bromide 5mg IV. 3ml of 2% Xylocaine IV was given for attenuation of pressor response. Tracheal intubation was done with a cuffed endotracheal tube 7.5mm ID, fixation and placement was confirmed by auscultation. Patient was kept in prone position for surgery and care was taken to make sure that pressure related injuries do not occur due to positioning. Anesthesia was maintained with oxygen (O₂) and nitrous oxide (N₂O) and inhalational agent Isoflurane kept at 0.6-2 MAC. Volume controlled ventilation with respiratory rate of 14/min, tidal volume of 550ml was maintained during surgery and patient remained hemodynamically stable throughout the procedure. After dissection of the Posterior fossa and foramen magnum, posterior removal of the C1 arch was done, and the patient was kept back in supine position. After reversing the effect of neuromuscular blockade with neostigmine 2.5mg and glycopyrrolate 0.5mg the trachea was extubated following the extubation criteria.

Post-operative analgesia was maintained with Inj tramadol IV. Patient was put on O₂ inhalation at 4l/min via a face mask, was monitored for 48 hours before shifting to the ward. The postoperative course was uneventful with no neurological deterioration and the patient was discharged on the 5th postoperative day.

DISCUSSION: There are very few reports on anesthetic management in patients with syringomyelia and here we report our case with a successful outcome. Anesthetic management for patients with syringomyelia is general anesthesia to avoid cerebrospinal fluid (CSF) pressure fluctuations and intracranial pressure (ICP) elevations. [1]

Syringomyelia has been divided into two groups, those which communicating with CSF pathways (communicating syringomyelia) and those which do not communicate (non-communicating). [5] The communicating form is the most common where continuity between syrinx and subarachnoid space and its CSF exists. Most of the communicating syringomyelia are linked to congenital or acquired anomalies involving the foramen magnum of which ACM I is the commonest. [6] Non communicating syrinx can develop anywhere in the cord and the factors involved include hematoma, ischemia, venous obstruction, shearing stress with mechanical disruption and proteinaceous fluid secretion. It may also be idiopathic. [6,7]

Our patient had a non communicating syrinx from C2 to T1 and suspended sensory loss from C5 to T1 with thermo-analgesic dissociation.

In a classic case of syringomyelia; patient shows asymmetric loss of pain and temperature sensation in the upper limb (lateral spinothalamic tract), lower motor neuron signs in the hands (anterior horn cells), and upper motor neuron signs in the lower limbs (corticospinal tracts). Advanced disease is usually characterised by presence of posterior column signs. [6] Trophic changes may be striking particularly with development of gross osteoarthropathy (Charcot's joints). Autonomic neuropathy can be there in a coexisting syringomyelia. [8]

The problems that may arise during anesthetic management of these patients are:

1. Damage to the spinal cord due to raised intracranial pressure.
2. Tachyarrhythmias, widely fluctuating arterial pressure, sudden cardiac or respiratory arrest due to abnormalities in the autonomic nervous system.
3. Ventilation-perfusion abnormalities if respiratory muscles are involved.

CASE REPORT

4. Venous access may be limited due to trophic lesions in the skin.
5. Requires careful positioning of the patient due to disorganized joints and fixed flexion deformities.
6. Exaggerated responses to non-depolarizing muscle relaxants can be seen in some set of patients.
7. Impaired thermal regulation can also be a problem.
8. Careful prior airway assessment due to difficulty in intubation if associated with pregnancy. [9,10]

In our opinion, one of the most important goals during general anesthesia is to avoid aggravating the already disturbed craniospinal pressure relationship. Even in patients without clinical or radiological findings, it can be assumed that intracranial CSF pressure is relatively high as it is fundamental to the pathophysiology of syringomyelia. Spinal anesthesia is best avoided in the presence of co-existing chiari malformations, as there are case reports which described the onset of signs and symptoms upto 2 weeks after dural puncture. [11,12]

To conclude, general anesthesia may be used safely in patients with syringomyelia to avoid increase in ICP. Early diagnosis, surgery and proper measures helped us for the successful discharge of patient to home happily.

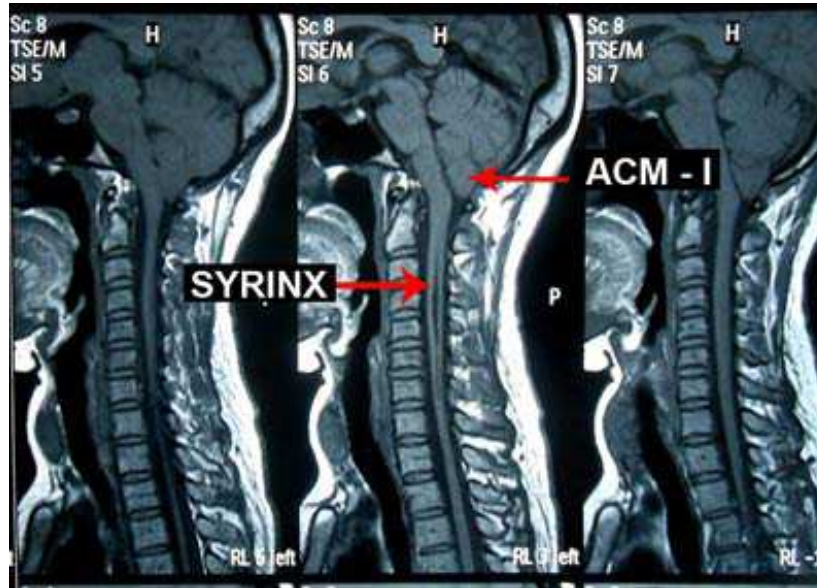
ACKNOWLEDGEMENT: Neurosurgeon Dr. Phani Kumar MS, Mch.

REFERENCES:

1. Chanshun Bao, Fubing Yang, Liang Liu, Bing Wang, Dingjun Li, YingjiangGu. Surgical treatment of Chiari I malformation complicated with syringomyelia. *Experimental and therapeutic medicine* 2013;5:333-37.
2. Ramsis F. Ghaly, Kenneth D. Candido, Ruben Sauer, Nebojsa Nick Knezevic. Anesthetic management during Cesarean section in a woman with residual Arnold-Chiari malformation Type I, cervical kyphosis, and syringomyelia. *Surg Neurol Int* 2012;3:26.
3. Madsen PW, Yeziarski RP, Holets VR. Syringomyelia: clinical observations and experimental studies. *J Neurotrauma* 1994;11:241-54.
4. Brewis M, Poskanzer DC, Rolland C. Neurological disease in an English city. *ActaNeurolScand* 1966;42:1-89.
5. Williams B. The distending force in the production of "communicating syringomyelia". *Lancet*;1969;2:189-93.
6. Walton JN. *Brain's disease of the Nervous System*, 9th Ed, Oxford, Oxford University Press,1985;412-16.
7. Williams B. On the pathogenesis of syringomyelia: a review. *J R Soc Med* 1980;73:798-806.
8. Nogues MA, Newman PK, Male VJ et al. Cardiovascular reflexes in syringomyelia. *Brain* 1982;105:835-49.
9. Lakshmi Jayaraman, NitinSethi, JayashreeSood. Anaesthesia for Caesarean section in a patient with Lumbar Syringomyelia. *Rev Bras Anesthesiol* 2011;61:4:469-73.
10. Bensghir Mustapha, K. Chkoura, M. ELhassani, R.Ahtil, H.Azendour, N.DrissiKamili. Difficult intubation in a parturient with syringomyelia and Arnold-Chiari malformation: Use of Airtaq™ laryngoscope. *Saudi J Anaesth* 2011;5:419-22.

CASE REPORT

11. Hullander RM, Bogard TD, Leivers D, Moran D, Dewan DM. Chiari I malformation presenting as recurrent spinal headache. *Anesthesia and Analgesia* 1992;75:1025-29.
12. Barton JJS, Sharpe JA. Oscillopsia and horizontal nystagmus with accelerating slow phases following lumbar puncture in the Arnold-Chiari malformation. *Annals of Neurology* 1993;33:418-21.



Syrinx-MRI-Images-labelled