

TREATMENT OF LUMBAR INTERVERTEBRAL DISC PROLAPSE BY TRADITIONAL LAMINECTOMY: DISCECTOMY AND BY INTER LAMINAR DISCECTOMY: FORAMINOTOMY: A COMPARITIVE STUDYAnanthula Krishna Reddy¹, V. Prashanth², Ashok Ohatker³, Saive Siddhartha⁴, K. Chandrashekar Rao⁵**HOW TO CITE THIS ARTICLE:**

Ananthula Krishna Reddy, V. Prashanth, Ashok Ohatker, Saive Siddhartha, K. Chandrashekar Rao. "Treatment of Lumbar Intervertebral Disc Prolapse by Traditional Laminectomy: Discectomy and by Inter Laminar Discectomy: Foraminotomy: A Comparitive Study". Journal of Evolution of Medical and Dental Sciences 2015; Vol. 4, Issue 85, October 22; Page: 14834-14841, DOI: 10.14260/jemds/2015/2110

ABSTRACT: Low back ache might not be lethal but it certainly makes up for in the misery it causes in the modern society. Intervertebral disc prolapse is one of the commonest causes for low back ache with sciatica affecting the young adults. Management of sciatica varies considerably. Patients are commonly treated conservatively. But in selected patients surgical intervention results in more rapid relief of symptoms and restoration of function. With advanced instrumentation, optics and technique, there has been a lot of improvement in the surgical management of lumbar disc prolapse. This led to a transition from the traditional technique of laminectomy and discectomy with wide exposure to a minimally invasive micro endoscopic discectomy. In this study we compare the functional outcome of surgical management of lumbar disc prolapse by Standard Laminectomy-discectomy with interlaminar discectomy - foraminotomy. Our study includes 25 patients with lumbar intervertebral disc prolapse, of which 14 underwent traditional laminectomy and discectomy and 11 underwent interlaminar discectomy and foraminotomy, in Gandhi Hospital, Secunderabad during November 2009 to January 2015. Many factors influence the outcome of lumbar disc surgery. Emphasis should be laid on proper patient selection, which is the Key to good results. We used the Japanese Orthopaedic Association low backache score to evaluate our results, as it is simple and assesses the patient's outcome both subjectively and objectively. In our study both the procedures have shown to be effective in the management of intervertebral disc prolapse. Surgery for lumbar disc disease with traditional laminectomy and discectomy can be an effective treatment but it results in disruption of posterior stabilizing structures of spine and subsequent complications and so is not indicated for a single level disc herniation. Interlaminar discectomy with foraminotomy can produce the same, if not better results with less post-operative morbidity. Though traditional laminectomy might result in disruption of posterior stabilizing structures, it still has a place in the treatment of cases of cauda equina syndrome and lumbar disc disease associated with canal stenosis, which certainly need decompressive laminectomy.

KEYWORDS: Disc Prolapse, Laminectomy, Discectomy, Foraminotomy.

INTRODUCTION: Low back ache is a common cause of significant morbidity in the population. Up to 70% of the population will experience back pain sometime in their life.^{1,2,3} However, clinically significant sciatica due to lumbar disc prolapse occurs in only about 4-6% of the population. The people usually affected are young adults. So low back pain affects the socio-economic status of a society significantly.^{1,2,3}

Management of sciatica varies considerably. Patients are commonly treated conservatively but a small proportion is referred to secondary care and may eventually undergo surgery if complaints

ORIGINAL ARTICLE

remain persistent for at least 6weeks. Surgical intervention may result in more rapid relief of symptoms and restoration of function.

There has been a lot of improvement in the surgical management of lumbar disc prolapse due to advances in instrumentation, optics and technique. This led to transition from the old technique of a long incision, wide exposure for laminectomy and discectomy to the minimally invasive micro endoscopic discectomy.

Surgery for lumbar disc disease with traditional laminectomy and discectomy can be an effective treatment but results in disruption of posterior stabilizing structures of spine and subsequent complications and so is not indicated for a single level disc herniation. Interlaminar discectomy with foraminotomy can produce the same, if not better results with less post-operative morbidity.

In this study we compare the functional outcome of surgical management of lumbar disc prolapse by Laminectomy - discectomy with interlaminar discectomy - foraminotomy.

MATERIALS AND METHODS: This study includes 25patients with lumbar intervertebral disc prolapse admitted to the department of Orthopaedics, Gandhi Hospital, Secunderabad during November 2009 to January 2015. The patients underwent radiological investigations (MRI) to confirm the diagnosis and to know the level of lesions.

While selecting the patients for surgery, patient's psyche, personality, family background, duration of illness, presenting symptoms and signs, functional disability and the effect of conservative treatment were evaluated.

Patients without neurological deficit or signs of sciatic nerve irritation, those with duration of symptoms less than 6weeks and patients with IVDP associated with structural scoliosis, spondylolisthesis, failed back syndrome/ recurrent disc herniation were excluded from our study.

The Key to good results in disc surgery is appropriate patient selection.^{4,5} Hence in our study we performed the surgery, only in whom:

1. Predominant unilateral leg pain persisted for at least 6 weeks.
2. The pain decreased by rest and analgesics but recurred to initial levels after a minimum of 6 to 8 weeks of conservative care.
3. Physical examination revealed signs of sciatic nerve irritation.
4. The clinical diagnosis of disc prolapse was confirmed by MRI.

When conservative treatment failed, we considered them for surgical management and the options were:

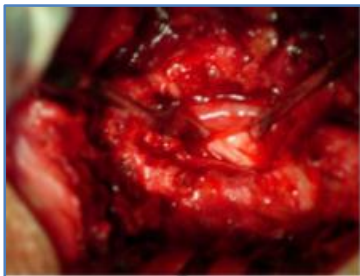
1. Standard laminectomy and discectomy.
2. Interlaminar discectomy and foraminotomy.

STANDARD LAMINECTOMY AND DISCECTOMY: A midline skin incision centring over the involved lumbar segment was made. Soft tissues were elevated subperiosteally from the spinous process and lamina. A window was made by incising the ligamentum flavum and nibbling the inferior margin of the lamina. The dura and the nerve root were retracted to identify the disc pathology. Nerve root was retracted medially so that the underlying extruded fragment or bulging posterior longitudinal ligament can be seen.

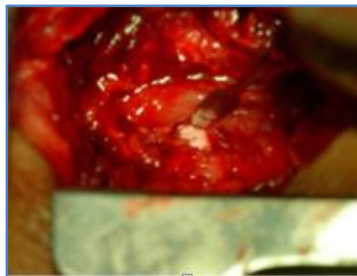
ORIGINAL ARTICLE

Occasionally the nerve root adhesions to the disc fragment or to the underlying ligamentous structures may require sharp dissection from these structures. Posterior longitudinal ligament should be carefully palpated to seek a defect if no extruded fragment is seen. If no obvious abnormality is detected the root should be followed around the pedicle or outside the canal or in the root axilla to search for the fragments that have migrated. Then the disc excision was performed.

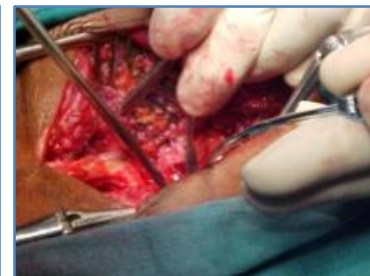INTERLAMINAR DISCECTOMY WITH FORAMINOTOMY: A standard vertical midline incision, centered over the appropriate level was made. The overlying muscles were retracted. The interlaminar space was identified on the affected side. Only the ligamentum flavum and, if necessary, a very small portion of lamina was excised to expose the affected disc space. The dural sac and the nerve root were retracted medially and disc excision was performed. After disc removal, the neural foramen was assessed and if necessary, a selective foraminotomy was performed. The spinal nerve should be gently moved to the side, and any remaining bone compressing the nerve should be removed. In this process the root should be followed around the pedicle or even outside the canal in search of fragments that have migrated far laterally and also in the root axilla for the fragments that have migrated inferiorly.



LAMINECTOMY



DISCECTOMY



INTER-LAMINAR

RESULTS: The study includes 25 patients operated for lumbar intervertebral disc prolapse of which 14 underwent traditional laminectomy and discectomy and 11 underwent interlaminar discectomy and foraminotomy. All patients were available for follow up for this prospective analysis. The minimum follow up duration was 6 months. The age of the patients varied from 21-65 years with mean age of 36.3 years. In our study there were total of 16 males and 9 females. Majority of the patients were hardworking agricultural labourers.

Majority of the cases came with complaints of both low back ache and radicular pain. The duration of symptoms varied from 2 months to 2 years with mean duration of 8.2 months. Most of the patients had a positive SLRT along with neurological deficit. Out of the 25 cases, 20 cases had unilateral sciatica and 5 had bilateral. In unilateral cases, left sciatica was more common. 16 of the patients in the study had SLRT between 200-40° and 9 had SLRT between 40°-60° distributed almost equally in both the groups.

ORIGINAL ARTICLE

Distribution of Pre-operative JOA score:

JOA pre-op score	Laminectomy		Foraminotomy	
	No. of patients	%	No. of patients	%
0-5	5	35.7	1	9
6-10	9	64.2	10	91
11-15	0	0	0	0

JOA pre op score of 6-10 was found to be common in both the study groups.

The commonest level of disc prolapse was found to be L4-L5 in both the groups. The second most common level involved was L5- S1.

Distribution of Post op JOA score:

JOA post-op score	Laminectomy		Foraminotomy	
	No. of patients	%	No. of patients	%
0-5	0	0	0	0
6-10	2	14.2	0	0
11-15	12	85.7	11	100

JOA score after 6 months of follow up in both the groups was found to be 11-15, signifying considerable improvement with both modes of surgical treatment.

Distribution of Surgical outcome on the basis of JOA score:

Surgical outcome	Laminectomy		Foraminotomy	
	No. of patients	%	No. of patients	%
Excellent	0	0	1	9
Good	5	35.7	9	82
Fair	8	57.1	1	9
Poor	1	7.1	0	0

Treatment outcome on the basis of JOA score was found to be fair to good in 13(93%) patients in the laminectomy group and one had poor outcome. In foraminotomy group fair to good outcome was seen in 10(91%) patients and one patient had excellent outcome.

Nearly all patients had relief from low back ache and radicular pain on 6 months follow up. 4 patients in laminectomy group and 1 patient in foraminotomy group complained of occasional low back pain.

We had dural tear in one case of laminectomy, which was repaired intra-operatively. A case of superficial wound infection was noted in foraminotomy group, which subsided with appropriate antibiotics for 3weeks.

DISCUSSION: Low back ache might not be lethal but it certainly makes up for in the misery it causes in the modern society. Low back pain has become one of the most common musculoskeletal disorders, with a major impact on health care costs and is a major source of disability.⁶

ORIGINAL ARTICLE

Intervertebral disc prolapse is one of the commonest causes for low back ache. The results of good outcome after lumbar disc excision varies in literature from 46 to 97%.^{7,8,9,10} There are a considerable number of failed back surgeries too which may require revision surgery. The recurrence rate for lumbar disc excision varies from 6% to 11% in various studies.¹¹

This implies that there are many factors which influence the outcome of lumbar disc surgery. Therefore emphasis should be laid on proper patient selection. For a great majority of patients with sciatica due to disc prolapse, conservative treatment provides satisfactory relief from symptoms. Lumbar disc herniation shows a favorable response to conservative treatment even in the presence of some neurological deficit.¹²

Hence any surgical intervention without an appropriate conservative trial ends in not only unnecessary surgery but also in poor outcome.¹³ However a protracted conservative regimen in the presence of severe radicular symptoms should be avoided since this increases morbidity and reduces the chances of a successful outcome.

It is therefore the clinician's task to select the proper patients for surgery.^{10,14} with appropriate indications, who are expected to have symptomatic relief with limited risk.

Better investigative modalities (Myelography/CT/MRI) have led to accurate diagnosis and visualisation of disc lesions, thus guiding the surgeon in planning a precise surgical correction, preventing unnecessary exploration of uninvolved levels.¹⁵ Results of lumbar disc surgery are excellent when there is agreement between clinical presentation and imaging studies.

In our study we used the Japanese Orthopaedic Association low backache score to evaluate our results. This score was used as it is simple which assesses the patient's outcome both subjectively and objectively.

In our study, there was highest incidence of disc prolapse in the 31-40years age group and most common level involved was L4-L5 followed by L5-S1 which was in accordance with other studies.

A good to fair outcome was obtained in 93% of the cases of laminectomy group and in 91% of the cases in the foraminotomy group, which is comparable to other studies. This could probably be attributed to the proper selection of cases.

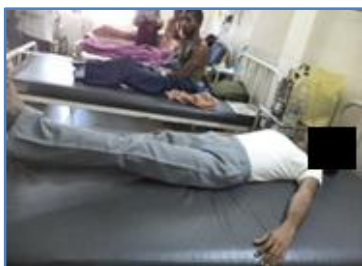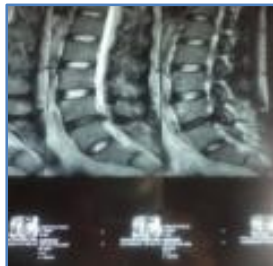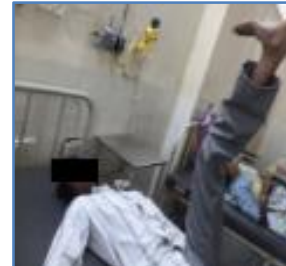Apart from one case of intra-operative dural tear and one case of superficial wound infection, we didn't come across with other complications such as discitis, worsening of neurological deficit, nerve root injury, pulmonary embolism, retroperitoneal injury, vascular injury etc. as reported in other studies.

Surgery for lumbar disc disease with traditional laminectomy and discectomy can be an effective treatment and but is not indicated for a single level disc herniation. Interlaminar discectomy with foraminotomy can produce the same, if not better results with less post-operative morbidity.

In our study both Laminectomy-discectomy and Interlaminar discectomy- foraminotomy have shown to be effective in the management of intervertebral disc prolapse. Though traditional laminectomy might result in disruption of posterior stabilizing structures of spine and subsequent complications, it still has a place in the treatment of cases of cauda equina syndrome and lumbar disc disease associated with canal stenosis, which certainly need decompressive laminectomy.

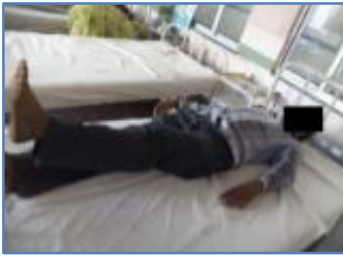BIBLIOGRAPHY:

1. Campbell Operative orthopedics 11th ed, Vol. 2, chapter 34-41, page 1729-2328.
2. Abramovitz ZN, Neff S. Lumbar Disc Surgery: Results of prospective lumbar discectomy study of joint section on disorders of spine of peripheral nerves of American Association of Neurological surgeons and Congress of neurological surgeons. Neurosurgery 29: 301 – 308, 1991.
3. Finesson BE. Lumbar disc excision – Schidesk H.K., Sweet W.H. (eds). Operative Neurosurgical Technique, 3rd Ed., 1905 – 1924, 1995.
4. Rothman R. New developments in lumbar disc surgery. Orthop.Rev.1975, 4:23-30.
5. Spengler DM, Freeman CW. Patient selection for lumbar discectomy: An objective approach. Spine 1979, 4:129-34.
6. Kraemer, Juergen et al, “Epidemiology”. Chapter-1, the lumbar spine, Vol.I, 2nd Edn. Weisel, Sam W. et al, Philadelphia: W.B. Saunders Company, 1996:1-42pp.
7. Junge A, J. Dvorak, and S. Ahrens, 1995: “Predictors of lumbar disc surgery outcomes”. Spine, 20(4): 460-468.
8. Pappas T.E., T. Harrington and V. K. H. Sonntag, 1992: “Outcome analysis in 654 surgically treated lumbar disc herniations”. Neurosurgery, 30(6): 862-866.
9. Davis R.A., 1994: “A long-term outcome analysis of 984 surgically treated herniated lumbar discs”. J. Neurosurg, 80: 415-421.
10. Daneymez M, Sali A, Kahraman S, Beduk A, Seber N. Outcome analysis in 1072 surgically treated lumbar disc herniations. Minim Invasive. Neurosurgery 1999, 42(2):63-8.
11. Morgan-Hough C.V.J., P.W. Jones and S. M. Eisenstein, 2002: “Primary and revision lumbar discectomy: A 16-year review from one centre”. J Bone Joint Surg Br, 85-B (6):871-874.
12. Weber H.: Lumbar disk herniation – A controlled prospective study with 10 years of observation. Spine 8: 131 – 140, 1983.
13. Simeone, Frederick A, “Lumbar disc disease”. Chapter-387, Neurosurgery, Vol. III, 2ndEdn. Edt. Wilkins, Robert H. and Setti S. Rengachary, New-York; McGraw Hill 1996: 2805-3816pp.
14. McCulloch JA. Focus issue on lumbar disc herniation: macro and microdiscectomy. Spine 1999, 21(24 Suppl.):455-65.
15. Godersky J.C., D.L. Erickon and E.L. Seljeskog, 1984: “Extreme lateral disc herniation: Diagnosis by computed tomographic scanning”. Neurosurgery, 14(5): 549-552.

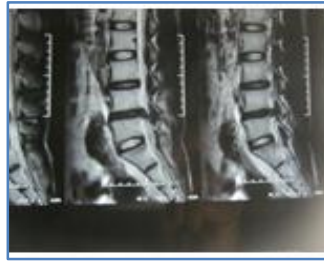
Case 1: Laminectomy-discectomy*Preoperative SLRT**MRI image**Post - op SLRT*

Case 2: Laminectomy-discectomy

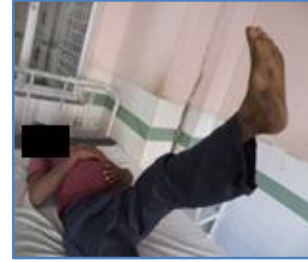Preoperative SLRT



MRI image

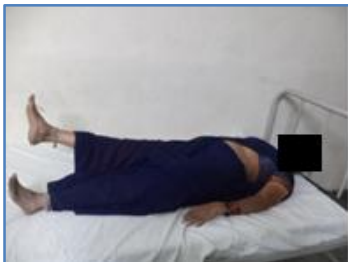

Post - op

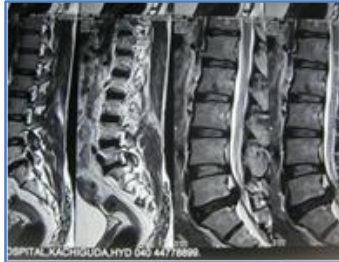

Case 3: Laminectomy-discectomy

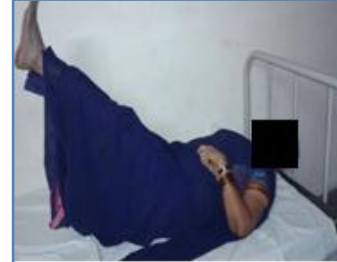Preoperative SLRT



MRI image

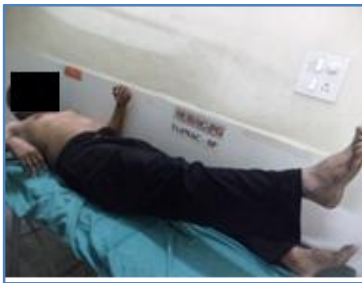

Post - op

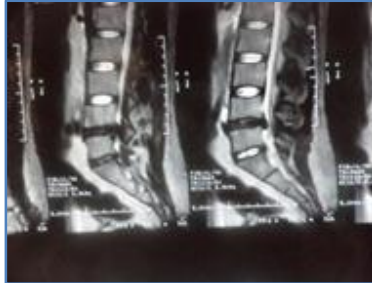

Case 4: Interlaminar discectomy-foraminotomy

Preoperative SLRT



MRI image

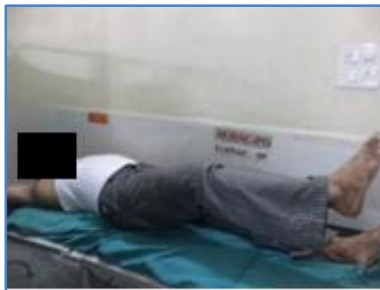

Post - op



Case 5: Interlaminar discectomy-foraminotomy

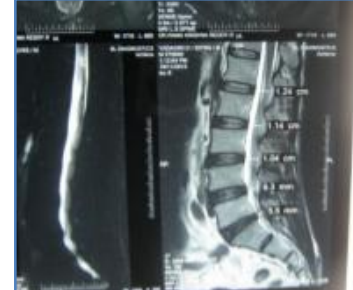Preoperative SLRT

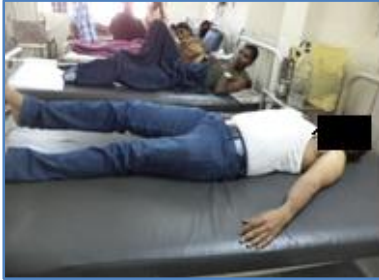
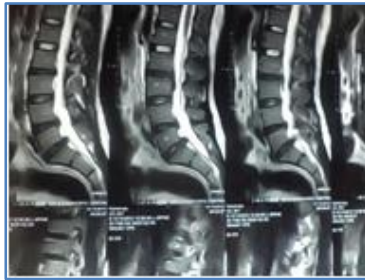
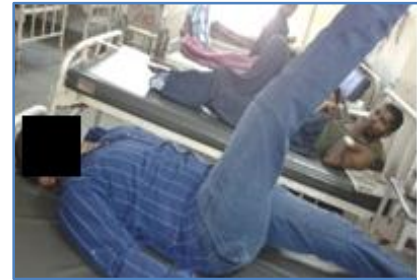MRI image



Post - op



Case 6: Interlaminar discectomy-foraminotomy**Preoperative SLRT****MRI image****Post - op****AUTHORS:**

1. Ananthula Krishna Reddy
2. V. Prashanth
3. Ashok Ohatker
4. Saive Siddhartha
5. K. Chandrashekar Rao

PARTICULARS OF CONTRIBUTORS:

1. Assistant Professor, Department of Orthopaedics, Gandhi Hospital, Secunderabad, Telangana State.
2. Associate Professor, Department of Orthopaedics, Gandhi Hospital, Secunderabad, Telangana State.
3. Professor, Department of Orthopaedics, Gandhi Hospital, Secunderabad, Telangana State.

FINANCIAL OR OTHER**COMPETING INTERESTS:** None

4. Senior Resident, Department of Orthopaedics, Gandhi Hospital, Secunderabad, Telangana State.
5. Assistant Professor, Department of Orthopaedics, Gandhi Hospital, Secunderabad, Telangana State.

NAME ADDRESS EMAIL ID OF THE CORRESPONDING AUTHOR:

Dr. Ananthula Krishana Reddy,
C/o. Bhuvana Hospital,
H. No. 3-13/3, Peerjadiguda,
Opposite Uppal Bus Depot,
Hyderabad, Telangana.
E-mail: kr_dr@ymail.com

Date of Submission: 08/10/2015.
Date of Peer Review: 09/10/2015.
Date of Acceptance: 12/10/2015.
Date of Publishing: 21/10/2015.