

**HYDATID CYST IN LUNG AND LIVER**Mani Krishna<sup>1</sup>, Sheetal G. Gole<sup>2</sup>, Gautam N. Gole<sup>3</sup>**HOW TO CITE THIS ARTICLE:**

Mani Krishna, Sheetal G. Gole, Gautam N. Gole. "Hydatid CYST in Lung and Liver". Journal of Evolution of Medical and Dental Sciences 2015; Vol. 4, Issue 72, September 07; Page: 12542-12547, DOI: 10.14260/jemds/2015/1806

**ABSTRACT:** Hydatid cyst is especially prevalent in parts of Eurasia, north and east Africa, Australia, South America. Hydatid disease is a zoonotic infection caused by adult or larval stages of the cestode *Echinococcus granulosus* and affects both humans and mammals. The infection is transmitted to dogs when they are fed on infected viscera of sheep or other ruminant during the home slaughter of animals. In the present case series four cases of hydatid cyst occurring at the lung and liver sites are discussed. The symptoms and signs may be caused by a toxic reaction to the parasite or by local and mechanical effects, depending on the location and nature of the cysts and the presence of complications. Early diagnosis and proper treatment will help to reduce the complication rate and prevent recurrence.

**KEYWORDS:** Hydatid cyst, *Echinococcus granulosus*, lung, liver.

**INTRODUCTION:** *Echinococcus granulosus* was first documented in Alaska but is distributed world-wide. It is especially prevalent in parts of Eurasia, north and east Africa, Australia, South America.<sup>[1]</sup>

Hydatid disease (Cystic echinococcosis) is a parasitic disease that affects both humans and mammals more commonly dogs, horse, sheep and rodents. Cystic echinococcosis develop when human ingest egg of *Echinococcus granulosus* which are shed in the faeces of dogs harboring adult stages of this tapeworm. Several strains of *Echinococcus granulosus* have been identified and all but two are noted to be infective in humans.

The infection is transmitted to dogs when they are fed on infected viscera of sheep or other ruminant during the home slaughter of animals.

In its domestic transmission cycle, *E. granulosus* requires two host type, a definitive host and an intermediate host. Dogs are definitive hosts of the adult tapeworm and ruminants (Particularly sheep and goats) are intermediate hosts. Human are accidental intermediate hosts and are not able to transmit the disease.

Human ingest egg through direct contact with definitive hosts or indirectly through food, water or soil contaminated with egg. The larval stage that emerges from the egg gives rise to a hydatid cyst. The larval stage results in the formation of echinococcal cysts in intermediate hosts.

A cyst slowly enlarges, and signs and symptoms of disease vary according to its location and size in the body, duration of the development of the cyst and the cyst type. Cyst are found mostly in the liver and lung, although other organs may be affected.<sup>[1]</sup>

A cyst can be diagnosed on the basis of clinical, ultrasound (US), Contrast enhanced computed tomography (CECT), Magnetic resonance imaging (MRI), immunoelectrophoresis (IE), and histopathology.

**MATERIALS AND METHODS:** Four cases of hydatid cyst are discussed. In all the 4 cases formalin-fixed tissue sections were stained with hematoxylin and eosin.

**RESULTS: Case Studies:**

**Case 1:** An 11-year-old girl presented with pain over the right side of abdomen. On respiratory examination, breath sounds were reduced on right lower chest. Except for a slight rise in the SGOT, SGPT and serum alkaline phosphatase, all the other hematological and biochemical parameters were normal. US abdomen showed 2 thin walled cystic lesions in the liver measuring 10×9×3.4cm and 8.5×8.0×6.5cm. CECT chest showed 1 thin walled cystic lesion in right lower lobe of lung measuring 7×6.4×5.2cm. Radiological findings were suggestive of hydatid cysts.

**Case 2:** A 42-year-old male presented with right sided chest pain. On respiratory examination, breath sounds were reduced on right side of the chest. Except for raised serum lactate dehydrogenase (LDH) levels, all other hematological and biochemical parameters were normal. CECT chest showed a well-defined fluid collection/cystic lesion of size 6.3×4.5×3.7cm in right cardiophrenic angle in relation to the pericardium. Radiological findings were suggestive of a pericardial cyst.

**Case 3:** A 22-year-old male presented with left sided chest pain. On respiratory examination, breath sounds were reduced on left side of the chest. Except for raised SGOT, SGPT and serum alkaline phosphatase, all other hematological and biochemical parameters were normal. CECT chest showed a cystic lesion of size 11.5×7.5×3.5cm in the lower lobe of left lung. Radiological findings were suggestive of a hydatid cyst.

**Case 4:** A 30-year-old female presented with lump right side abdomen. Except for a slightly raised serum alkaline phosphatase, all other hematological and biochemical investigations were normal. US abdomen showed two thin walled cystic lesions in the liver right upper lobe. Radiological findings were suggestive of hydatid cysts.

Patients suffering from chest pain and right side abdomen pain come to OPD. Case 1, 3 and 4 had increased alkaline phosphatase. Case 1 and 3 also had increased SGOT and SGPT. But in case 2, serum LDH levels were also raised.

All other hematological and biochemical investigations were within normal limits. Radiological findings were suggestive of hydatid cysts except in case 2. One out of four cases was positive for serology (ELISA).

Except for case 2, the provisional diagnosis of hydatid disease was made on the basis of clinical and radiological examination. In case 2, pericardial cyst was the radiological diagnosis. All 4 patients underwent surgery and the cysts were excised and sent for histopathological examination. In all the 4 cases, histopathology revealed features of hydatid cyst. Post-operatively, all the patients had a good recovery and were put on albendazole.

Considering the morphological gross findings, all 4 cases showed pearly glistening white, opaque, unilocular cysts with smooth outer and inner surfaces (Figures 1, 2). In case 3, a part of lung measuring 8×5×3.5cm having a cystic cavity containing the above described cyst was sent for histopathology (Figure 3).

Microscopic examination showed histological features of hydatid cyst comprising of acellular, lamellated fibrous and chitinous wall with daughter cysts having invaginated morphology along with scolex and germinal lining (Figures 4, 5).

## ORIGINAL ARTICLE

CASE NO.	AGE (Years)	SEX	SITE	NUMBER OF CYSTS	
				LIVER	LUNG
1	11	Female	Lung and Liver	2 (Right lobe)	1 (Right lower lobe)
2	42	Male	Lung	-	1 (Right lower lobe)
3	22	Male	Lung	-	1 (Left lower lobe)
4	30	Female	Liver	2 (Both lobes)	-

**Table 1:** Summarizes the different modes of presentation with the age and sex of our cases

**Fig. 1, 2:** Gross pictures showing pearly glistening white, opaque, unilocular cysts with smooth outer and inner surfaces.

**Fig. 3:** Gross picture showing a part of lung with a cystic cavity containing cyst having pearly glistening white, opaque smooth outer and inner surfaces.

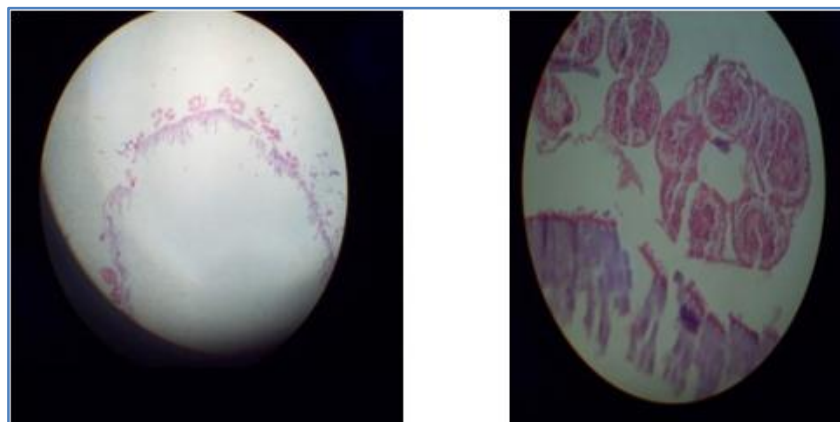


**Fig. 1 & 2**



**Fig. 3**

**Fig. 4, 5:** Photomicrograph (4X, 40X) revealing fibrous and chitinous wall and attached daughter cyst with invaginated morphology having scolex and germinal lining.



**Fig. 4 & 5**

## ORIGINAL ARTICLE

---

**DISCUSSION:** Hydatid disease is a zoonotic infection caused by adult or larval stages of the cestode *Echinococcus granulosus*, which is a small, 5-mm-long tapeworm. Human infection by *Echinococcus granulosus* occurs most commonly in sheep- and cattle-raising areas where dogs assist in herding.<sup>[2]</sup> Human beings are usually infected as intermediate hosts when they ingest egg-contaminated food or water. Hydatid cysts grow at a rate of about 1–5cm/year and a long latent period is typical.<sup>[3]</sup>

Human Echinococcosis is a zoonotic infection caused by the tapeworm of the genus *Echinococcus*. Incidence in endemic areas ranges from 1-220 cases per 100,000 inhabitants.<sup>[2,4]</sup> Infestation by hydatid disease in humans most commonly occurs in the liver (55-70%) followed by the lung (18-35%). It may present in an unusual manner in this usual sites.

Human beings are usually infected as intermediate hosts when they ingest egg-contaminated food or water. More than 50% of all human *E. granulosus* infections involve the liver.<sup>[5]</sup> Additional common sites for hydatid cysts are the lungs, spleen, kidneys, heart, bone and brain.<sup>[6]</sup>

Hepatic hydatid disease causes highly variable symptoms and signs, and can be found incidentally in an asymptomatic patient. The symptoms and signs may be caused by a toxic reaction to the parasite or by local and mechanical effects, depending on the location and nature of the cysts and the presence of complications. Early diagnosis and proper treatment will help to reduce the complication rate and prevent recurrence.<sup>[7]</sup>

The hydatid cyst gradually enlarges in the liver parenchyma and may cause symptoms such as dull pain in the right upper quadrant, hepatomegaly, and formation of a palpable mass. Daughter cyst formation may develop from the inner germinal layer in the cyst cavity or exogenously. This may explain why there are 2 or more cysts in the livers of certain patients, as was seen in our case 1 and 4. The cyst may also rupture into the bile ducts and release daughter cysts, resulting in biliary colic and jaundice; Infection is another complication, which occurs when both the pericyst and the endocyst perforate, allowing bacteria to pass easily into the cyst.

Infection usually manifests as a hepatic abscess. Rarely, the cyst ruptures into the bronchial tree causing hydatidemia. The presence of intraperitoneal hydatidosis accompanying hepatic disease is usually due to micro perforations or contamination during previous surgery. However, direct perforation of a liver cyst into the peritoneal cavity may occur, resulting in acute abdominal pain and systemic anaphylactic reactions. Thoracic involvement occurs in 0.6% to 16% of cases of hepatic hydatid disease.<sup>[2]</sup>

In theory, there are three treatment options for hepatic cystic echinococcosis: chemotherapy, surgery, and percutaneous drainage or a combination of these therapies.<sup>[8,9]</sup> However, the use of chemotherapeutic agents alone, such as mebendazole or albendazole, is controversial because of their limited efficacy. These antiparasitic drugs are often administered as adjuvant therapy during surgery or percutaneous treatment.

With the advent of PAIR (Puncture, Aspiration, Injection, Reaspiration) technique, treatment of hydatid cyst is simplified to a large extent.<sup>[10]</sup> Although certain types of hydatid cysts are successfully treated by PAIR, surgery remains the treatment of choice.<sup>[3,7]</sup>

If a human, becomes infected, there are variety of methods for treatment. However in recent years, less invasive treatments have been developed such as cyst puncture, aspiration of the liquids, the injection of chemicals, and then re-aspiration. Benzimidazole-based chemotherapy is also a new treatment option.<sup>[11]</sup> The most common treatment in the past years has been surgical removal of the hydatid cysts.<sup>[12]</sup>

## ORIGINAL ARTICLE

---

**CONCLUSION:** Hydatid disease of the liver and lung though a common parasitic disease, has a considerable morbidity. The precaution that can be taken is that humans should avoid handling fecal matter of canines and avoid consuming infected animals and home slaughtering animals.

Treatment comprises mainly surgical intervention or percutaneous treatment and or high dose, long term therapy with chemotherapeutic agents such as mebendazole or albendazole alone or in combination with praziquantel. Benzimidazol is also a new treatment option.

Surveillance in animals is difficult because the infection is asymptomatic in livestock and dogs, and not recognized or prioritized by communities or local veterinary services.

On the basis of biochemical, radiological and histopathological findings in all cases can suggest that pathological study could be used as more reliable tool then serology test.

### REFERENCES:

1. McManus DP, Zhang W, Li J, Bartley PB. Echinococcosis. *Lancet*. 2003; 362: 1295–1304.
2. Safioleas MC, Misiakos EP, Kouvaraki M, Stamatakos MK, Manti CP, Felekouras ES. Hydatid Disease of the Liver A Continuing Surgical Problem. *Arch Surg*. 2006; 141: 1101-1108.
3. Battyányi I, Herbert Z, Rostás T, Vincze A, Fülöp A, Harmat Z et al. Successful percutaneous drainage of a giant hydatid cyst in the liver. *World J Gastroenterol*. 2006; 12(5): 812-814.
4. Ashok KB: Old Disease...New Location...Surgeons Be Alerted. *International Journal of Collaborative Research on Internal Medicine & Public Health*. 2011; 3(4): 328-332.
5. Akhan O, Dincer A, Saatci I, Gulekon N, Besim A. Spinal intradural hydatid cyst in a child. *Br J Radiol*. 1991; 64: 465-466.
6. Akhan O, Bilgic S, Akata D, Kiratli H, Ozmen MN. Percutaneous treatment of an orbital hydatid cyst: A new therapeutic approach. *Am J Ophthalmol*. 1998; 125: 877-879.
7. Sayek S, Tirnaksiz B, Dogan R. Cystic Hydatid Disease: Current Trends in Diagnosis and Management. *Surg Today*. 2004; 34: 987–996.
8. Yogci G, Ustunsoz B, Kaymakcioglu N, Bozlar U, Gorgulu S, Simesk A, et al. Results of surgical, laparoscopic, and percutaneous treatment for hydatid disease of the liver. 10 years experience with 355 patients. *World J surg*. 2005; 29: 1670-1679.
9. Smego RA Jr, Bhatti S, Khaliq AA, Beg MA. Percutaneous aspiration-injection-reaspiration drainage plus albendazole or mebendazole for hepatic cystic echinococcosis: A metaanalysis. *Clin Infect Dis*. 2003; 37: 1073-1083.
10. Chiodini P. Parasitic infections. In: Russell RC, Williams NS, Christopher JK, editors. *Balstrode. Bailey and Love's short practice of surgery*. 24<sup>th</sup> ed. London: Hodder Arnold; 2004; 167-168.
11. Eckert, J. and P. Deplazes. Biological, Epidemiological, and Clinical Aspects of Echinococcosis, a Zoonosis of Increasing Concern. *Clinical Microbiology Reviews*. 2004; 17: 107-135.
12. Craig, P.S., D.P. McManus, M.W. Lightowlers, J.A. Chabalgoity, H.H. Garcia, C.M. Gavidia et al. Prevention and control of cystic echinococcosis. *The Lancet* 2007; 385-395.

## ORIGINAL ARTICLE

---

### **AUTHORS:**

1. Mani Krishna
2. Sheetal G. Gole
3. Gautam N. Gole

### **PARTICULARS OF CONTRIBUTORS:**

1. Associate Professor, Department of Pathology, Rural Institute of Medical Sciences & Research, Saifai, Etawah, Uttar Pradesh.
2. Associate Professor, Department of Pathology, Shaheed Hasan Khan Mewati Government Medical College, Nalhar, Mewat Haryana.

### **FINANCIAL OR OTHER**

**COMPETING INTERESTS:** None

3. Professor, Department of General Surgery, Shaheed Hasan Khan Mewati Government Medical College, Nalhar, Mewat, Haryana.

### **NAME ADDRESS EMAIL ID OF THE CORRESPONDING AUTHOR:**

Dr. Mani Krishna,  
Associate Professor,  
Department of Pathology,  
Rural Institute of Medical Sciences & Research,  
Saifai, Etawah, Uttar Pradesh.  
E-mail: drmanikrishna@gmail.com

Date of Submission: 21/08/2015.  
Date of Peer Review: 22/08/2015.  
Date of Acceptance: 02/09/2015.  
Date of Publishing: 05/09/2015.