

## CASE REPORT

---

### DEVELOPMENTAL DYSPLASIA OF THE HIP AT SEVEN YEARS OF AGE TREATED WITH OPEN REDUCTION AND FEMORAL DEROTATION OSTEOTOMY AND PEMBERTON ACETABULOPLASTY: A CASE REPORT

Somashekar<sup>1</sup>, J. N.Sridhara Murthy<sup>2</sup>, Rakesh Mohan R<sup>3</sup>, Yathish R<sup>4</sup>, Arun Kumar<sup>5</sup>

#### HOW TO CITE THIS ARTICLE:

Somashekar, J. N.Sridhara Murthy, Rakesh Mohan R, Yathish R, Arun Kumar. "Developmental Dysplasia of the Hip at Seven Years of Age Treated with Open Reduction and Femoral Derotation Osteotomy and Pemberton Acetabuloplasty: A Case Report". Journal of Evolution of Medical and Dental Sciences 2014; Vol. 3, Issue 10, March 10; Page: 2668-2674, DOI: 10.14260/jemds/2014/2190

**INTRODUCTION:** DDH includes a spectrum of disorders affecting a developing hip joint, varying from an occult dysplasia to frank dislocation. Since the hip joint at birth is purely cartilaginous the chances of missing this condition is very high. High degree of suspicion is essential to make sure that cases are detected early. Difficulty in changing the diapers may be any early indicator of occult dysplasia.

**METHOD:** A 7year old girl presented to us in April 2012 with pain in left hip joint. On examination the child had Trendelenburg gait, exaggerated lumbar lordosis, shortening of left lower limb (fig. 1), telescoping and Galleazi/Alli's sign (fig. 2) was positive. Patient had no fixed deformities but had restriction of abduction in left hip joint. Provision diagnosis of DDH was made and X-rays (fig. 3) were done. Imaging revealed break in the shentons line, capital femoral epiphysis was atrophic and displaced to upper-outer quadrant of reference lines. Acetabular dysplasia was noted and Acetabular index was calculated and found to be 45°.

Since it was possible to achieve concentric reduction of the hip joint and the age of the child was 7 years we had treatment options of Salter's osteotomy and Pemberton's Acetabuloplasty as illustrated in the table 1.

We decided to go ahead with Pemberton's acetabuloplasty as it was more advantageous than the other procedure as mentioned in table 2.

Patient was operated under general anesthesia. With an anterior iliofemoral incision left hip joint approached similar, osteotomy performed starting from a point midway between ASIS and AIIS.<sup>1</sup>A curvilinear osteotomy done along the superior margin of acetabulum, ending just short of the iliopubic limb of triradiate cartilage. Osteotomy is not done if full thickness and the plane of cleavage is parallel to the roof of the acetabulum.

Pemberton Acetabuloplasty completed and a bone graft inserted into the osteotomy site and stabilized with Reconstruction plate and screw. Femur was approached through a classical lateral approach, subtrochanteric osteotomy done and head internally rotated by 30 degrees and stabilized with Dynamic compression Plate and Screws. The patient was put in one and half spica for 3 weeks, followed by abduction cast for the next 3 weeks.

Postoperative period was uneventful. Patient was mobilized with nonweight bearing hip exercise for 6 weeks and graduated weight bearing started from 7<sup>th</sup> week reaching full weight bearing by 12 weeks. No residual defect or any obvious complication or complaint was recorded.

## CASE REPORT

TYPE OF OSTEOTOMY	COMMENTS
<b>With Concentric Reduction</b>	
<b>Younger than 8 yr. of age</b>	
Salter	Redirects acetabulum
Pemberton	Restructures acetabulum, decreases volume
<b>8-15 yr. of age (triradiate open)</b>	
Double innominate (Sutherland)	Greater redirection of acetabulum
Dega	Restructures acetabulum
<b>Older than 15 yr. of age (triradiate closed)</b>	
Triple innominate	Greater redirection of acetabulum
Ganz (Bernese)	Maximum acetabular redirection; achieves stable pelvis; difficult
Spherical (Wagner, Eppright)	Maximum acetabular redirection; difficult
<b>Without Concentric Reduction</b>	
Shelf (Staheli)	
Chiari	

**Table 1**

	<b>Pemberton's Pericapsular Acetabuloplasty<sup>1</sup></b>	<b>Salter's Osteotomy<sup>2,3</sup></b>
Skill Level	Technically more demanding	Procedure is easier to perform
Degree of Correction achieved	Greater	Limited
Hinge for osteotomy	Tri-Radiate cartilage	Pubic symphysis
Internal fixation after osteotomy	Not always required	Must be done
Volume of Acetabulum	Reduced	Maintained
Acetabular Cavity	Restructured/ Reconstructed	Redirected

**Table 2**

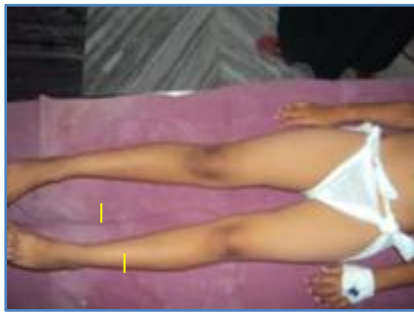**DISCUSSION:** Hip joint develops normally congruous to both the components. Normal acetabular development depends on a normally placed femoral head. Reduction should be gentle and the joint should not be placed under strain.<sup>4</sup> Some time closed reduction can be done but maintenance of the reduction without strain is not possible. If reduced under strain it can lead to necrosis of the head or dislocation occurs again specially during movement of extension and external rotation of the hip. At higher age closed reduction is not possible at all.<sup>4</sup> Nomay et al presumed that after open reduction of the hip, the acetabulum which is shallow will remodel around the femoral head in response to pressure exerted by the femoral head.<sup>5,6</sup> Usually this results in gradual deepening of the acetabulum and improved coverage of the femoral head. But many times this remodeling is incomplete and the

## CASE REPORT

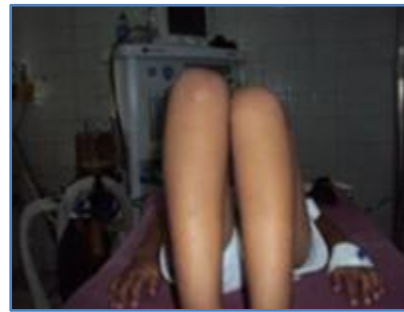acetabulum remains shallow and the roof remains inclined. Salter and Pemberton are two recommended osteotomies to reposition the acetabulum after correct reduction in age groups younger than 8 years.<sup>7,8</sup> Salter osteotomy redirect the acetabulum while Pemberton reshapes the acetabulum. Pemberton osteotomy repositions the acetabulum to improve anterior and lateral head coverage.<sup>2,3</sup> Osteotomy begins at AIIS and proceeds inferior and posterior to enter the tri-radiate cartilage.

The osteotomy hinges around the tri-radiate cartilage which decreases the volume of the acetabulum and is especially recommended for wide acetabulum and when more than 15 degree change in the acetabular index is required.<sup>9,10</sup>

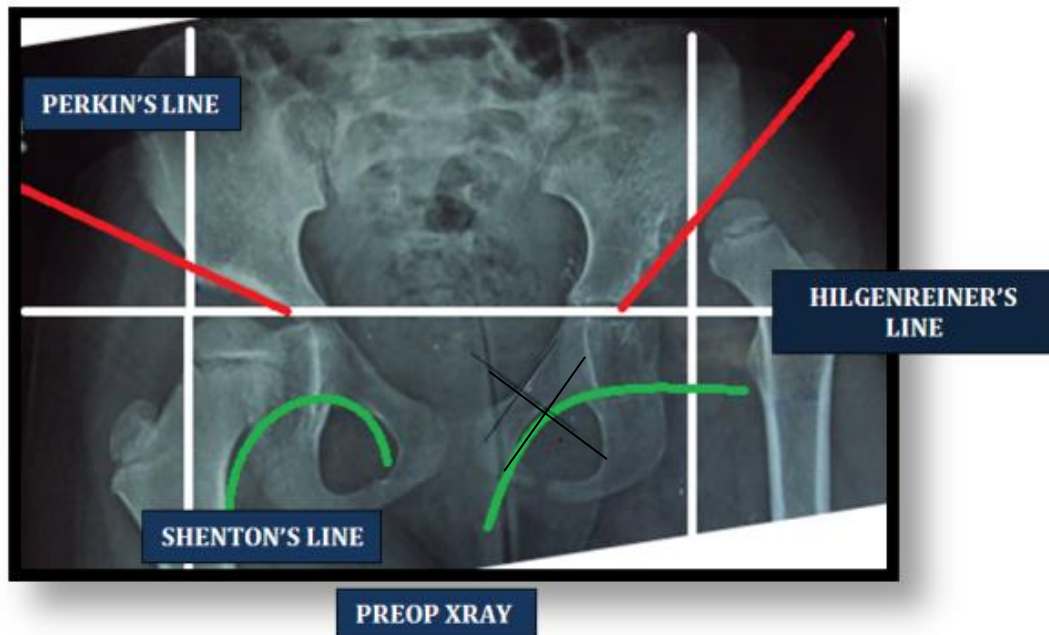
Present child at end of 1 year 6 months had full range of motion without of any residual pain or discomfort. Gait had improved significantly; child is able to do all routine activities.



LIMB LENGTH DISCREPANCY

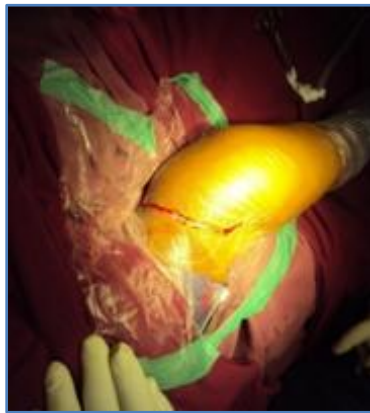


GALLEAZZI'S TEST/ ALLI'S SIGN

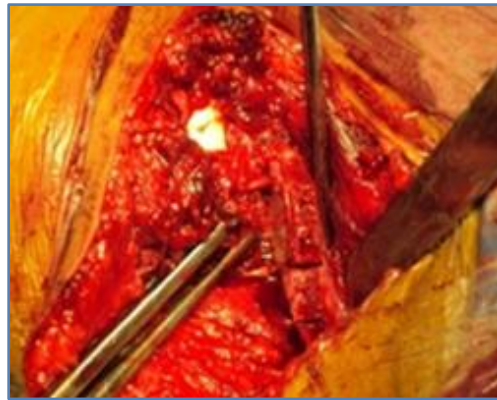


## CASE REPORT

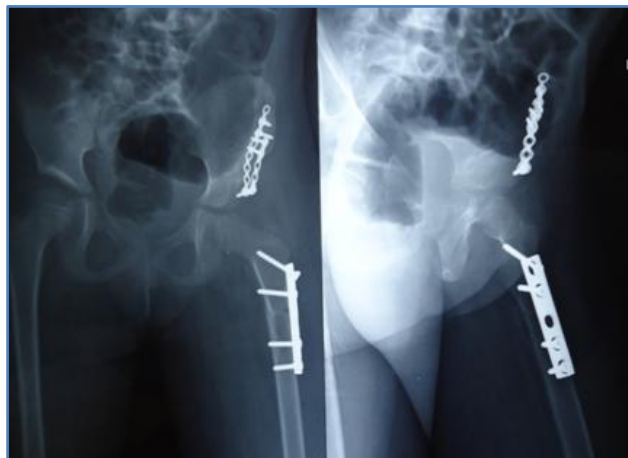
---



**SURGICAL INCISION**



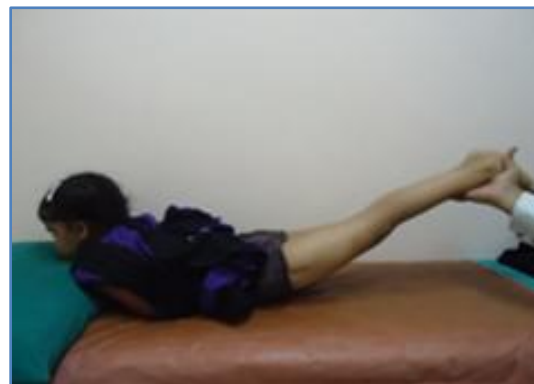**INTRAOPERATIVE -GRAFT PLACEMENT**



**POST OP X-RAY**



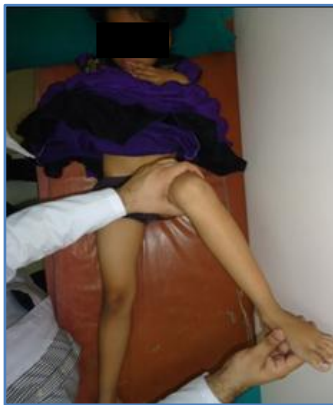**FLEXION**



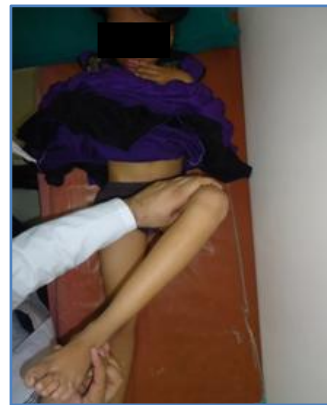**EXTENSION**

## CASE REPORT

---



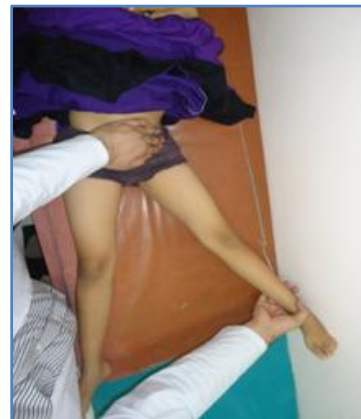**INTERNAL ROTATION**



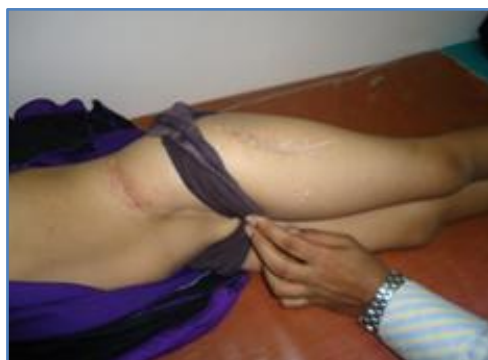**EXTERNAL ROTATION**



**ADUCTION**

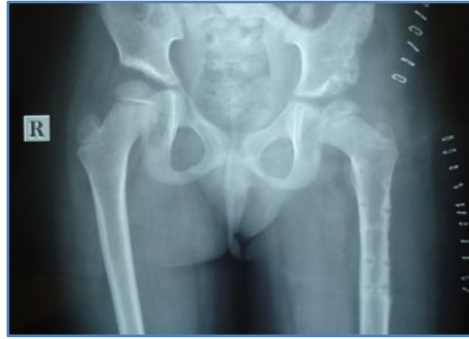

**ABDUCTION**

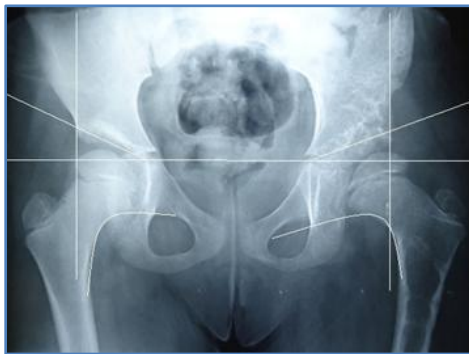

**SURGICAL SCAR**

## CASE REPORT



**IMMEDIATE POST IMPLANT REMOVAL, TOTAL 1 YEAR AFTERSURGERY**



**FOLLOW UP XRAY**

- CAPITAL FEMORAL EPIPHYSIS WELL CONTAINED, OCCUPYING THE INNER LOWER QUADRANT.
- FEMORAL HEAD & ACETABULAR CAVITY REMODELLING WELL
- ACETABULAR INDEX REDUCED

**CONCLUSION:** Triradiate cartilage if used as a hinge instead of pubic symphysis yields greater degree of acetabular correction with good stability and excellent functional outcome.

Pemberton's acetabuloplasty restructures the acetabulum whereas salter's osteotomy only redirects the existing acetabular cavity hence pemberton's is a preferred procedure.

In our center earlier we were using Salter osteotomy for most cases of DDH presenting beyond 3 years of age. With the present case treated with Pemberton acetabuloplasty resulted in a good reduction of the acetabular head and excellent functional outcome. We thus strongly recommend Pemberton acetabuloplasty over Salter osteotomy. Hoping to continue the use of this procedure and produce similar results in the future endeavors.

### REFERENCES:

1. Pemberton, P. A. Pericapsular osteotomy of the ilium for treatment of congenital subluxation and dislocation of the hip. *Journal of Bone and Joint Surgery* 1965, 47-A, 65-86.
2. Salter R. B. Innominate Osteotomy in the Treatment of Congenital Dislocation and Subluxation of the Hip. *J. Bone and Joint Surg.*, 43-B (3): 518-539, 1961.

## CASE REPORT

3. Salter R. B. and Dubos J.-P. The First Fifteen Years' Personal Experience with Innominate Osteotomy in the Treatment of Congenital Dislocation and Subluxation of the Hip. Clin. Orthop. 98: 72-103, 1974.
4. Birnbaum K, Pastor A, Prescher A et al. Complications of Chiari and Salter osteotomies: a cadaver study. Surg Radiol Anat 2000; 22:225.
5. Lipton GE, Bowen JR. A new modified technique of triple osteotomy of the innominate bone for acetabular dysplasia. Clin Orthop Relat Res 2005; 434:78.
6. Luhmann SJ, Bassett GS, Gordon JE et al. Reduction of a dislocation of the hip due to developmental dysplasia: implications for the need for future surgery. J Bone Joint Surg 2003; 85A:239.
7. Wada A, Jufii T, Takamura K et al. Pemberton osteotomy for developmental dysplasia of the hip in older children. J Pediatr Orthop 2003; 23.
8. Saleh JM, O'Sullivan ME, O'Brien TM. Pelvic remodeling after Salter osteotomy. J Pediatr Orthop 1995; 15: 342-345.
9. Tavares JO. Modified Pemberton acetabuloplasty for the treatment of congenital hip dysplasia. J Pediatr Orthop. 24:5012004.
10. Wada A, Jufii T, Takamura K et al. Pemberton osteotomy for developmental dysplasia of the hip in older children. J Pediatr Orthop. 23:508 2003.
11. Wu K W, Wang T M, Huang S C et al. Analysis of osteonecrosis following Pemberton acetabuloplasty in developmental dysplasia of the hip: long-term results. J Bone Joint Surg. 92A:2083 2010.

### AUTHORS:

1. Somashekar
2. J. N. Sridhara Murthy
3. Rakesh Mohan R.
4. Yathish R.
5. Arun Kumar

### PARTICULARS OF CONTRIBUTORS:

1. Associate Professor, Department of Orthopaedics, KIMS, Bangalore.
2. Professor and HOD, Department of Orthopaedics, KIMS, Bangalore.
3. III Year Post Graduate, Department of Orthopaedics, KIMS, Bangalore.
4. Assistant Professor, Department of Orthopaedics, KIMS, Bangalore.

5. Senior Resident, Department of Orthopaedics, KIMS, Bangalore.

### NAME ADDRESS EMAIL ID OF THE CORRESPONDING AUTHOR:

Dr. Rakesh Mohan R,  
#27, Rajasree Bhavan,  
1<sup>st</sup> Cross, Bharathi Layout,  
S. G. Palaya, Bangalore – 560029,  
Karnataka.  
E-mail: drrakeshmohan@gmail.com

Date of Submission: 27/01/2014.

Date of Peer Review: 28/01/2014.

Date of Acceptance: 18/02/2014.

Date of Publishing: 10/03/2014.