

TUBERCULOSIS IN LACTATIONAL ABSCESS - STUDY AT A TERTIARY CARE CENTER

Vivek Shetty¹, Reshmina C. D'Souza², Rakesh Rai³, Pooja Y. Gandhi⁴, Sunil H. Sudarshan⁵, P.S. Aithala⁶, Priyatham Kamath⁷, Aaron Marion Fernandes⁸,

HOW TO CITE THIS ARTICLE:

Vivek Shetty, Reshmina C. D'Souza, Rakesh Rai, Pooja Y. Gandhi, Sunil H. Sudarshan, P.S. Aithala, Priyatham Kamath, Aaron Marion Fernandes, "Tuberculosis in Lactational Abscess - Study at A Tertiary Care Center". Journal of Evolution of Medical and Dental Sciences 2014; Vol. 3, Issue 02, January 13; Page: 513-517, DOI:10.14260/jemds/2014/1858

BACKGROUND: Tuberculosis of the breast is a very rare occurrence accounting for approximately 4% of all breast lesions in countries where tuberculosis is rampant¹. Tuberculosis of breast is a disease seen in young lactating multiparous women. Tuberculosis of breast has varied presentation ranging from an abscess or a painless breast mass. India is a country which is endemic for tuberculosis; hence early diagnosis of tuberculosis is needed so that effective anti-tuberculous therapy can be started and the disease can be eradicated. **AIMS:** In view of the above said we considered to study the varied presentations of lactational abscess and to highlight the importance of tuberculosis as a cause of breast abscess in lactating mothers. **METHODS AND MATERIAL:** This is a prospective study done between over a period of 1 year from between January 2011 to December 2011 chosen by purposive sampling technique. The patients who met the inclusion and exclusion criteria were subjected to a thorough anesthetic workup and then the drainage was done using Hiltons method, the pus was sent for culture and abscess wall contents and the cavity tissue for histopathological examination. The collected data was analyzed. **Statistical Analysis:** Percentage and frequency were used for statistical analysis. **RESULTS:** Out of the 55 patients the commonest age group was between 21- 30 years (32%) and symptom was mastalgia (100%). Both patients (100%) responded well to 6 months of anti-tuberculosis treatment with disappearance of axillary lymph nodes. **CONCLUSION:** Lactational abscess can be one of the presentations of tuberculosis of breast. In an endemic area careful evaluation of the lactational abscess has to be done so that early diagnosis of can be done and effective anti-tuberculous therapy can be given.

KEY WORDS: Tuberculous abscess, lactational abscess

INTRODUCTION: Tuberculosis disease of the breast is a very rare occurrence. Tuberculosis of the breast is a disease that commonly affects young lactating multiparous women. Tuberculosis of breast has varied presentation ranging from an abscess or a painless breast mass. India is a country which is endemic for tuberculosis; hence early diagnosis of tuberculosis is needed so that effective anti-tuberculous therapy can be started and the disease can be eradicated.

METHODS AND METHODS: This was a prospective study conducted, after obtaining an ethical clearance for the study. All consenting patients who presented with lactational breast abscess were chosen using purposive sampling technique after they met the predefined criteria which excluded patients who had evidence of undergoing prior treatment for tuberculosis, or patients who had people in their family or workplace who were being treated for or had already completed treatment for any type of tuberculosis.

ORIGINAL ARTICLE

History was taken and clinical examination was done to see who was fit for anesthesia. Patients chosen were explained the advantages and disadvantages and the complications of the procedure. Patients were prepared for the procedure as follows. They were kept nil by mouth for a minimum of 4 hours prior to surgery. A third generation cephalosporin was given an hour before and 6 hours after the procedure. The drainage procedure was done using Hiltons method, the pus was sent for culture and abscess wall contents and the cavity tissue for histopathological examination. Following the procedure adequate hemostasis was confirmed, if any bleeding points were noted they were controlled using cautery. Postoperatively analgesic was given orally for two days then only when needed. The culture report was traced and when it came the antibiotics were changed accordingly keeping in mind the lactational period and breast feeding status of the period. The collected data was analyzed by percentage and frequency was used for statistical analysis.

RESULTS: Out of the 55 patients in our study, the demographic evaluation revealed, forty one patients were from rural and fourteen were from urban areas. The patients fell in the age range 18 to 38 years with a mean of; the commonest age group was between 21- 30 years (32%). The symptoms with which the patients presented were fever (68%), mastalgia (100%). Two patients had multiple axillary nodes enlarged, non-matted. *Staphylococcus aureus* (38 patients, 69%) was the most common organism causing abscess followed by streptococcus (8 patients, 14%). Tuberculosis was diagnosed as the cause in two patients both by histology in them one patient had AFB bacilli in the gram stain. Both these patients were above 30 years and were multiparous. They presented at 7 and 8 months post-partum respectively. They were asked to discontinue the breast feeding and were started on anti- tubercular therapy which they both tolerated well. Patients are on follow up since 2 years with no recurrence or evidence of tuberculosis elsewhere in the body. The children are also healthy and doing well.

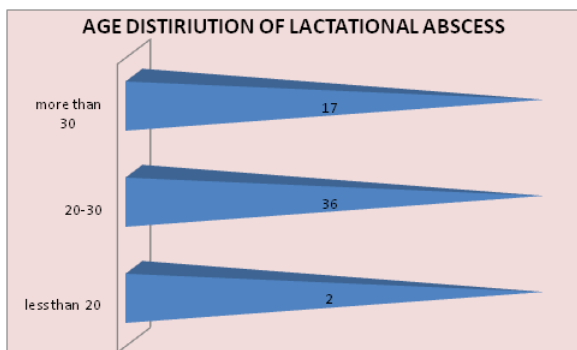


Fig. 1: Age Distiriuion of Lactational Abscess

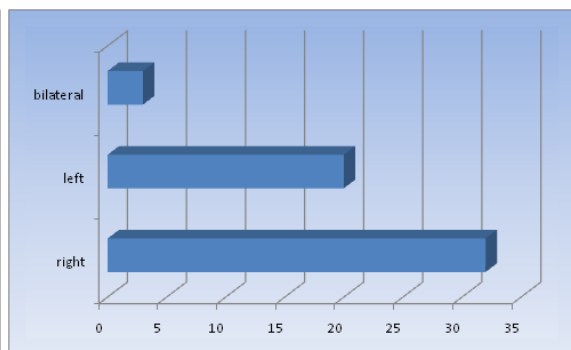


Fig. 2: Laterality Of Breast Abscess

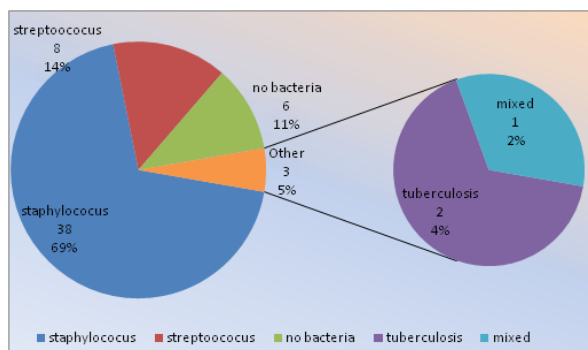


Fig. 3: Microbiological profile of Breast Abscess

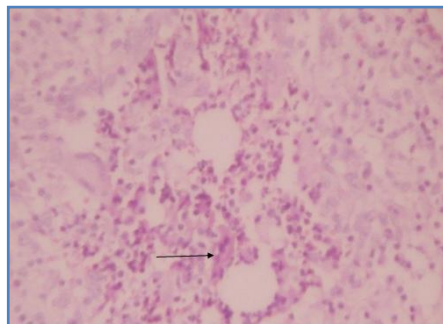


Fig. 4: microscopic view of tuberculosis, arrow at the langhans cell

DISCUSSION: Sir Astley Cooper has the credit of reporting the first case of tuberculosis of breast which he called the 'scrofulous swelling of the bosom'¹. Tuberculosis disease of the breast also called mammary tuberculosis is a very rare occurrence². Mammary tuberculosis accounts for approximately 4% of all breast lesions in countries where tuberculosis is rampant³. Tuberculosis disease is also seen in young lactating multiparous women⁴. Mammary tuberculosis has varied presentation ranging from an abscess or a painless breast mass. Tuberculosis of the breast has been classified clinically as (a) nodulocaseous tubercular mastitis, (b) disseminated/confluent tubercular mastitis, and (c) tubercular breast abscess.⁵ Breast TB is classified mammographically and pathologically into a nodular form, a disseminated form, and a sclerosing form^{6,7}. India is a country which is endemic for tuberculosis⁸. Mammary tuberculosis is a paucibacillary disease and so the routinely done microscopy, culture and nucleic acid amplification tests such as polymerase chain reaction techniques do not have the same diagnostic utility as they do in pulmonary tuberculosis^{9,11}. In our study the commonest age group was 21-30 years in contrast to a study by Bharat et al¹² in which the lactational abscess were seen more commonly above 30 years in the lactational breast. In another study they showed that mammary tuberculosis was common on right side, with the disease affecting the right breast in eleven patients (55%) and the left breast in nine patients (45%) which is comparable to our study¹³. Breast feeding is not absolutely contraindicated in tuberculosis and anti-tubercular therapy is indicated in breast tuberculosis¹⁴⁻¹⁶.

CONCLUSION: Lactational abscess can be one of the presentations of tuberculous of breast. In an endemic area careful evaluation of the lactational abscess have to be done so that early diagnosis of can be done and effective anti-tuberculous therapy can be given

ACKNOWLEDGMENTS:

1. To all the unit heads of the surgical units for supporting in conducting the study.
2. To the administration of the institution for allowing to conduct the study.
3. To the anaesthesia and general surgical residents for their prompt services whenever required.
4. To the pathologists and microbiologist for their advice and support.

REFERENCES:

1. Cooper A. Illustrations of the diseases of breast: Part I. London: Longman, Rees Orme, Brown and Green; 1829. p. 73.
2. Kalac N, Ozkan B, Bayiz H, Dursun AB, Demirag F. Breast tuberculosis. *Breast* 2002; 11: 346-9.
3. Tse GM, Poon CS, Ramachandram K, Ma TK, Pang LM, Law BK, et al. Granulomatous mastitis: A clinicopathological review of 26 cases. *Pathology*. 2004; 36:254-7.
4. BNK Kumar, Bhargav Pandya, D Das, PN Sheeramulu .Tubercular Breast Lesion a Great Mimicker of Carcinoma Breast.Nepalese Journal of Radiology 2013; 3(4):99-102.
5. Tewari M, Shukla HS. Breast tuberculosis: Diagnosis, clinical features, and management. *Indian J Med Res*. 2005; 122:103-10.
6. Baharoon S. Tuberculosis of the breast. *Ann Thorac Med*. 2008; 3:110-4.
7. Gupta R, Singal R, Gupta A, Singal S, Shahi S, Singal R. Primary tubercular abscess of the breast-an unusual entity. *J Med Life*. 2012; 5:98-100.
8. A Zumla, M Raviglione, R Hafner, C. F Reyn. Tuberculosis; *N Engl J Med* 2013; 368:745-755 February 21, 2013.
9. Sriram KB, Moffatt D, Stapledon R. Tuberculosis infection of the breast mistaken for granulomatous mastitis: A case report. *Cases J*. 2008; 1:273.
10. Morino GF, Rizzardi G, Gobbi F, Baldan M. Breast tuberculosis mimicking other diseases. *Tropical Doctor*. 2007; 37:177-8.
11. Harris SH, Khan MA, Khan R, Haque F, Syed A, Ansari MM. Mammary tuberculosis: Analysis of thirty-eight patients. *ANZ J Surg*. 2006; 76:234-7.
12. Bharat A, Gao F, Aft RL, Gillanders WE, Eberlein TJ, Margenthaler JA. Predictors of primary breast abscesses and recurrence. *World J Surg*. 2009 Dec; 33(12):2582-6.
13. da Silva B.B., Lopes-Costa P.V., Pires C.G., Pereira-Filho J.D., dos Santos A.R. Tuberculosis of the breast: analysis of 20 cases and a literature review. *Transactions of the Royal Society of Tropical Medicine and Hygiene*. 2009; 103:559-563.
14. WHO (Division of Child Health Development). Breastfeeding and maternal tuberculosis. 1998; 23:1-4. Available at: http://www.who.int/child-adolescent_health/publications/NUTRITION/Up_23.htm. Accessed on 1 Dec 2013.
15. ERS, WHO, IUATLD (Europe Region) Task Force. Tuberculosis management in Europe: Recommendations of a task force of the European Respiratory Society, the World Health Organization and the International Union against Tuberculosis and Lung Disease (Europe Region). *Eur Respir J* 1999; 14:978-92.s.
16. World Health Organization. Treatment of tuberculosis - guidelines for national programmes 3rd edition. WHO/CDS/TB/2003.313. WHO, Geneva, 2003.

AUTHORS:

1. Vivek Shetty
2. Reshmina C. D'Souza
3. Rakesh Rai
4. Pooja Y. Gandhi
5. Sunil H. Sudarshan
6. P.S. Aithala
7. Priyatham Kamath
8. Aaron Marion Fernandes

PARTICULARS OF CONTRIBUTORS:

1. Resident, Department of General Surgery, Father Muller Medical College.
2. Assistant Professor, Department of General Surgery, Father Muller Medical College.
3. Associate Professor, Department of General Surgery, Father Muller Medical College.
4. Resident, Department of OBG, BLDE Medical College.

5. Junior Consultant, Department of General Surgery, St. Marthas Hospital, Bangalore.
6. Professor & HOD, Department of General Surgery, Shrinivas Medical College.
7. Senior Resident, Department of General Surgery, Father Muller Medical College.
8. Resident, Department of General Surgery, Father Muller Medical College.

NAME ADDRESS EMAIL ID OF THE CORRESPONDING AUTHOR:

Dr. Reshmina C. D' Souza,
Assistant Professor
Father Muller medical college
Kankanady, Mangalore-575002
Email- dsouzareshmina@gmail.com

Date of Submission: 16/12/2013.
Date of Peer Review: 17/12/2013.
Date of Acceptance: 31/12/2013.
Date of Publishing: 11/01/2014