

REVIEW ARTICLE

RARE PRESENTATIONS OF PILOMATRICOMA: OUR EXPERIENCE IN A TERTIARY CARE HOSPITAL

Sunil S. Byadgi¹, Sachin Biradar², Dinesh L. Jadhav³, P. Shashikala⁴, S. B. Gejji⁵

HOW TO CITE THIS ARTICLE:

Sunil S. Byadgi, Sachin Biradar, Dinesh L. Jadhav, P. Shashikala, S. B. Gejji. "Rare Presentations of Pilomatricoma: Our Experience in a Tertiary Care Hospital". Journal of Evolution of Medical and Dental Sciences 2015; Vol. 4, Issue 53, July 02; Page: 9264-9271, DOI: 10.14260/jemds/2015/1345

ABSTRACT: Pilomatricoma/ Pilomatrixoma/ Benign calcifying tumor of Malherbe is an uncommon tumor of hair matrix origin, most commonly occurs in head and neck region and upper extremities. It has a wide morphological and clinical spectrum and can pose a diagnostic difficulty especially in cases with unusual clinical presentation. We report five cases of Pilomatrixoma, The diagnosis is made only after histopathology in both cases. In first case the women presented with swelling in the back of neck, clinically thought to be lipoma, no FNAC was done; excisional biopsy was done and sent for histopathology and report revealed to be Pilomatricoma. In second case the women presented with post hysterectomy, with pelvic abscess and incidentally during a midline incision was made a hard mass was felt after rectus sheath was dissected attached to peritoneum, sent for histopathology and revealed to be Pilomatricoma.

KEYWORDS: Pilomatricoma, Pilomatrixoma, Benign calcifying tumor of Malherbe.

INTRODUCTION: Pilomatrixoma or Pilomatricoma is a relatively uncommon benign tumor that originates from the matrix cells at the base of the hair.^[1] The most common location of this tumor is the head and neck region, followed by the upper extremities and rarely in the lower extremities.^[2,3] It presents as a solitary, slow-growing dermal or subcutaneous nodule; however, clinical diagnosis is often difficult or misdiagnosed.^[4,5] Histologic features of this tumor are well recognized, but cytological features often produce diagnostic difficulties.^[6]

CASE REPORTS:

CASE 1: 67 years old female patient presented to OPD with complaint of swelling behind nape of neck since 3 months, insidious in onset, initially it was small in size (pea nut) and gradually increased in size attained present size of 8*4, history of dull aching pain, no history of fever, known diabetic with history of hysterectomy 10 years back.

On inspection a solitary swelling just below the nape of neck about 8*4cm, oval in shape, upper border 15cm below from occipital protuberance surface is lobulated on palpation-no local raise of temperature, non-tender, surface nodular, variable in consistency, mobile in all direction, skin over the swelling pinch able.

- USG - Fibromatous lesion in posterior aspect of the neck.
- X-ray chest: soft tissue bulge at post aspect of the neck.
- Excision done under LA. After 1week and sent for histopathology, report revealed to be Pilomatricoma.

REVIEW ARTICLE

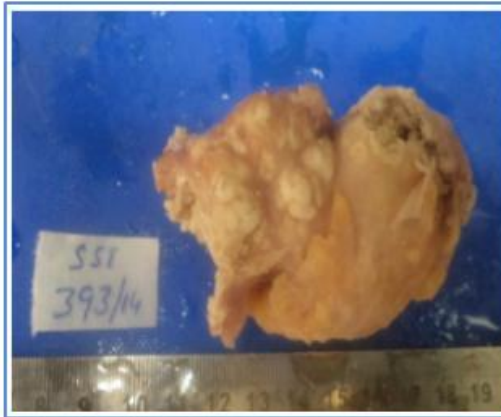


Fig. 1: Specimen-post processing

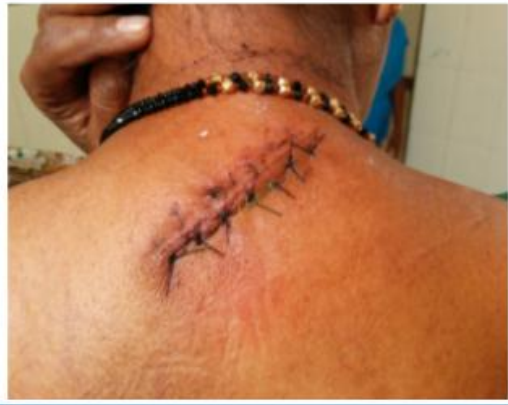

Fig. 2: Pic showing site of lesion

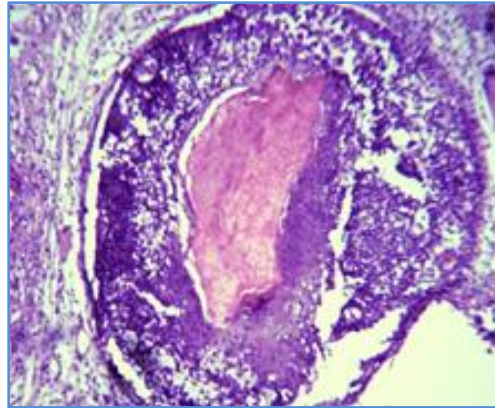


Fig. 3: Histopathology of specimen

CASE 2: 50 yrs old female patient by name XYZ presented to OPD with Chief Complaints of Pain abdomen since one week & Burning micturation since one week, Apparently healthy patient developed pain abdomen on right lower abdomen since one week, insidious in onset, gradually progressive, colicky type of intermittent pain. Pain aggravated since 2 days, there is no pain food relationship.

H/o fever since one week. Mild degree, intermittent fever without chills or rigor patient, Underwent hysterectomy 1 month back for Prolapse.

On examination Right hypochondriac and Right and left iliac fossa tenderness present Hypogastric tenderness, Right renal angle tenderness present, Soft to hard Mass felt in suprapubic, LIF,RIF and Umbilical region, diffuse, Bowel sounds present,

Simultaneously Gynecology Opinion Was Taken,

P/S Findings: Foul Smelling (Pus) discharge Present,

P/R Finding: Diffuse Mass Felt In Pouch of Douglas,

Working Diagnosis: Pelvic abscess.

REVIEW ARTICLE

USG:

1. Large heterogeneous pelvic collection posterior to bladder, about 7*8cm with multiple septations and internal echoes,? Infected pelvic collection.
2. Bilateral gross hydro Ureteronephrosis.
3. Post hysterectomy status.

After the routine investigations were normal patient was planned and posted for exploratory laparotomy and pelvic abscess drainage was done on 16/12/2014. Patient tolerated the procedure well, post-operative period was uneventful

Intra-operative Findings: A midline incision is taken for laparotomy and after skin and subcutaneous tissue are incised a soft to hard mass was felt during dissection just below umbilicus, it was sent for histopathological analysis. And HPE report came as Pilomatricoma.

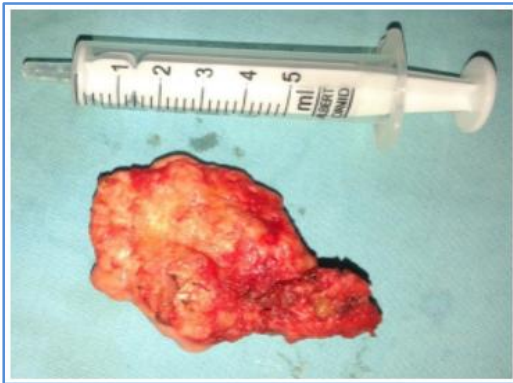

Fig. 4: specimen from intrabdominal

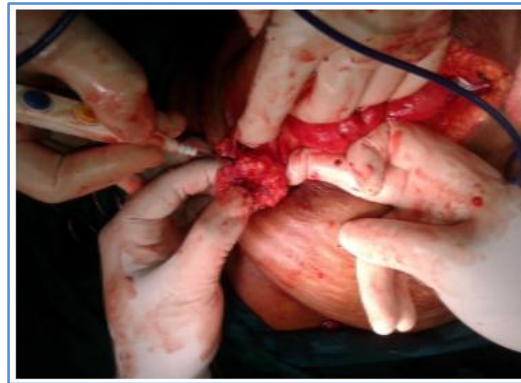


Fig. 5: Intraoperative picture location

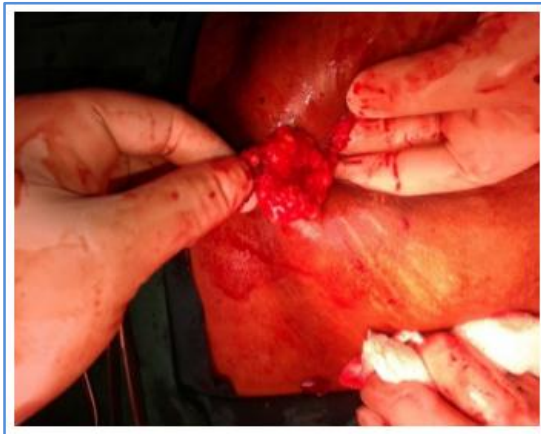

Fig. 6: Intraoperative picture

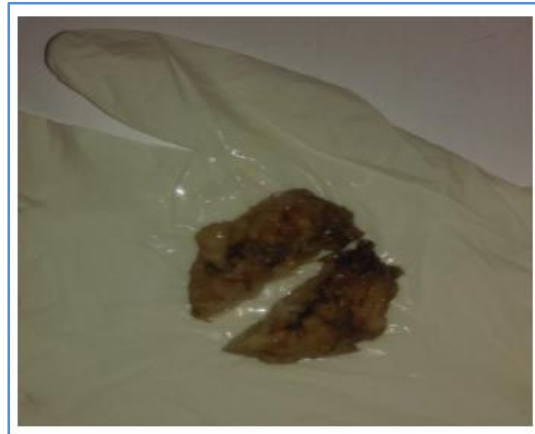

Fig. 7: Specimen after processing

REVIEW ARTICLE

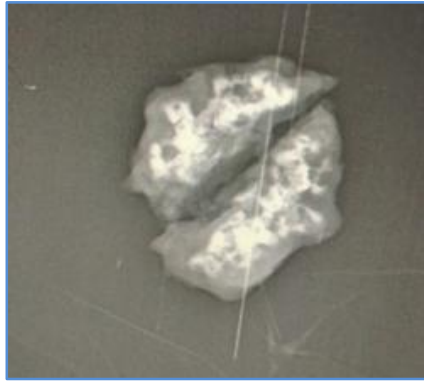


Fig. 8: X-ray of specimen showing specks of calcification

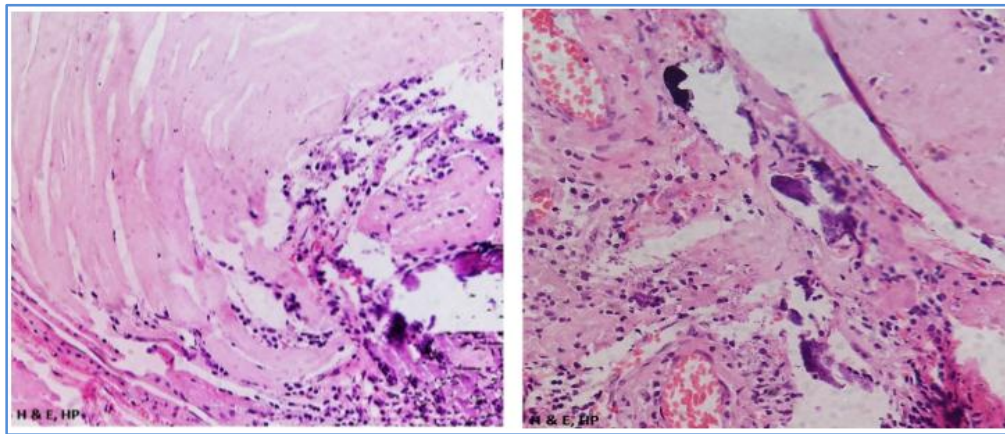


Fig. 9 & 10: Histopathology of the specimen h & e, high power (showing basaloid cells solid nests of basaloid cells with the formation of ghost cells with foreign-body giant-cell reaction, and calcification) case 3.

45 year old female patient presented to OPD with complaint of swelling over lateral side neck since 3 months, insidious in onset, initially it was small in size and gradually increased in size attained present size of 6*4, history of dull aching pain, no history of fever.

On inspection: A solitary swelling over the lateral side neck about 6*4cm, spherical in shape, upper border 4cm below from angle from angle mandible.

On palpation: No local raise of temperature, Non-tender, Nodular surface, Variable in consistency, Mobile in all direction, Skin over the swelling pinch able.

- Excision done under LA. After 1 week and sent for histopathology, report revealed to be Pilomatricoma.

CASE 4: 30 years old Male patient presented to OPD with complaint of swelling over left forearm since 8 months, insidious in onset, initially it was small in size and gradually increased in size attained present size of 8*4, no history of pain, no history of fever.

REVIEW ARTICLE

On Inspection: A solitary swelling over the left forearm 8*4cm, Oval in shape, Upper border 4 cm below from angle from medial epicondyle.

On Palpation: No local raise of temperature, Non-tender, Nodular surface, Variable in consistency, Mobile in all direction, Skin over the swelling pinch able.

Excision done under short GA, Intra operatively the mass was densely adherent to the surrounding tissue and sent for histopathology, Report revealed to be Pilomatricoma.

CASE 5: 35 year old Female patient presented to OPD with complaint of swelling over right arm since 6 months, insidious in onset, the swelling was associated with discharge, serosanguinous, initially it was small in size and gradually increased in size attained present size of 4*4, history of dull aching pain, history of fever.

On Inspection: A solitary swelling over right arm about 4*4 cm, oval in shape, upper border 4 cm below from angle from angle mandible.

On Palpation: No Local raise of temperature, Non-tender, Nodular surface, Variable in consistency, Mobile in all direction, Skin over the swelling pinch able.

Excision done under short GA. After 1 week and sent for histopathology, report revealed to be Pilomatricoma.

DISCUSSION WITH LITERATURE REVIEW: Pilomatrixoma is a relatively uncommon benign tumor of hair matrix differentiation, first described by Malherbe as benign calcifying epithelioma, as a tumor of the sebaceous gland.^[7] Later on, the term was changed to “Pilomatrixoma” because of its histogenesis from hair matrix cells.^[1] The most common sites involved in this tumor are the head and neck region, followed by the upper extremities, trunk, and the lower extremities.^[2,3,8] This tumor usually occurs in children younger than 10 years of age and also in the second decade of life.^[9] They are more commonly seen in women.

Though pilomatricoma can develop at any age, it demonstrates bimodal peak presentation during the first and sixth decades of life, however, 40% of cases occur in patients younger than 10 years of age and 60% of cases occur within the first two decades of life.^[10]

Clinically, this tumor presents as a soft to firm subcutaneous mass with intact overlying skin with average size 1.6cm.^[8] Correct clinical diagnosis is very rare and differential diagnosis includes epidermal cyst, dermoid cyst, cysticercosis, sebaceous cyst, sebaceous adenoma or carcinoma, capillary hemangioma, chalazion, rhabdomyosarcoma, and so on.^[2,8,11]

Pilomatricomas usually are asymptomatic (pain appears only with associated inflammation and ulceration); deeply seated, firm, non-tender subcutaneous masses adherent to the skin but not fixed to the underlying tissue. Stretching of the skin over the tumor shows the “tent sign” with multiple facets and angles, a pathognomonic sign for pilomatricoma.^[12] In addition, pressing on one edge of the lesion causes the opposite edge to protrude from the skin like a “teeter- totter”. Both these “tent sign” and “teeter- totter sign” are the most helpful clinical clues to the diagnosis of pilomatricoma.

Another characteristic feature of PMC is the blue red discoloration of the overlying skin which definitely excludes the possibility of epidermal inclusion or dermoid cyst. This characteristic clinical

REVIEW ARTICLE

feature was overlooked in both these cases. Another feature overlooked in the first case was that the lesion was adherent to the skin but otherwise not fixed to the underlying tissues.

FNA of the lesion commonly reveals basaloid cells, squamous cells, anucleate squames, shadow cells, foreign-body giant cells, polymorphs, and calcification in variable frequencies.^[8]

As all these findings are not present in a single case, cytological misdiagnosis is common and includes epidermal inclusion cyst, adnexal tumor, squamous cell carcinoma, basal cell carcinoma, mucoepidermoid carcinoma, or even round-cell tumor.^[8,13,14]

Four distinct morphological stages of pilomatricoma are defined as: (a) early: small and cystic lesions, (b) fully developed: large and cystic, (c) early regressive: foci of basaloid cells, shadow cells and lymphocytic infiltrate with multinucleated giant cells, (d) late regressive: numerous shadow cells, absence of basaloid and inflammatory cells, calcification and ossification may be present. Based on these criteria both our cases fit in the early regressive stage.^[15]

Since spontaneous regression is never observed and malignant transformation is rare, the standard treatment of pilomatricoma is complete surgical excision. Recurrence after surgery is rare, with an incidence of 0% to 3%.^[16] Malignant transformation to a pilomatrix carcinoma should be suspected in cases with repeated local recurrences.^[16]

When aspirates contain mainly nucleated squamous cells and squames, it leads to a wrong diagnosis of epidermal inclusion cyst. Predominance of basaloid cells can give a misdiagnosis of basal cell carcinoma or even round-cell tumor. In aspirates of pilomatrixoma, the presence of foreign-body giant cells is also variable. Moreover, they can be found in other lesions such as epidermal inclusion cysts, ruptured benign cysts, and panniculitis to squamous cell carcinoma.^[8]

Extreme calcification in pilomatrixoma may yield only calcified material and proper diagnosis may not be possible. Histopathologic examination provides the correct diagnosis and shows solid nests of basaloid cells with the formation of ghost cells with foreign-body giant-cell reaction, calcification, and ossification in some cases.

One of our patients presented with swelling on nape of neck. Clinical diagnosis of Lipoma/calcified sebaceous cyst was given. In our case, FNAC was not done, USG revealed-Fibromatous lesion in posterior aspect of the neck. X-ray chest: soft tissue bulge at post aspect of the neck. Histopathology confirmed the diagnosis.

The second case was an incidental finding and noticed during exploratory laparotomy for pelvic abscess.

In our second case, the site of the lesion, which was very uncommon, and it was completely asymptomatic and hence missed clinically. Knowledge of the morphological spectrum of characteristic cellular components helps in correct preoperative diagnosis of pilomatrixoma by FNAC and helps in proper patient management.

Our subsequent cases were again side of neck, forearm and arm, which is thought to be the common site of pilomatricoma.

CONCLUSION: Lastly, we have presented this case because of the rare location of the tumor and the malignant clinical presentation. In conclusion, although there have been case reports in the literature describing the clinical features and addressing the main differential diagnoses and diagnostic pitfalls of pilomatricoma, this lesion continues to cause difficulty in clinical diagnosis.

The main purpose of this article is to raise awareness among clinicians and illustrate the value of careful clinical screening, which can render definitive diagnosis of early, asymptomatic and

REVIEW ARTICLE

clinically unsuspected cases of pilomatricoma. This case also highlights the role of histopathology in arriving at a correct preoperative diagnosis.

REFERENCES:

1. Forbis R, Jr, Helwig EB. Pilomatrixoma (calcifying epithelioma) Arch Dermatol. 1961; 83: 606–18. [PubMed: 13700704]
2. Yap EY, Hohberger GG, Bartley GB. Pilomatrixoma of the eyelids and eyebrows in children and adolescents. Ophthal Plast Reconstr Surg. 1999; 15: 185–9.
3. Cypel TK, Vijayasekaran V, Somers GR, Zuker RM. Pilomatricoma: Experience of the hospital for sick children. Can J Plast Surg. 2007; 15: 159–61. [PMCID: PMC2687500] [PubMed: 19554149]
4. Kumaran N, Azmy A, Carachi R, Raine PA, Macfarlane JH, Howatson AG. Pilomatrixoma – Accuracy of clinical diagnosis. J Pediatr Surg. 2006; 41: 1755–8. [PubMed: 17011283]
5. Roche NA, Monstrey SJ, Matton GE. Pilomatricoma in children: Common but often misdiagnosed. Acta Chir Belg. 2010; 110: 250–4. [PubMed: 20514848]
6. Wang J, Cobb CJ, Martin SE, Venegas R, Wu N, Greaves TS. Pilomatrixoma: Clinicopathologic study of 51 cases with emphasis on cytologic features. Diagn Cytopathol. 2002; 27: 167–72. [PubMed: 12203865]
7. Peterson WC, Jr, Hult AM. Calcifying Epithelioma of Malherbe. Arch Dermatol. 1964; 90: 404–10. [PubMed: 14184485]
8. Bansal C, Handa U, Mohan H. Fine needle aspiration cytology of pilomatrixoma. J Cytol. 2011; 28: 1–6. [PMCID: PMC3083527] [PubMed: 21552399]
9. Sivakumar S. Pilomatrixoma as a diagnostic pitfall in fine needle aspiration cytology: A case report. Acta Cytol. 2007; 51: 583–5. [PubMed: 17718128]
10. Moehlenbeck FW. Pilomatrixoma (calcifying epithelioma). A statistical study. Arch Dermatol. 1973; 108: 532–4. [PubMed: 4745286]
11. Ali MJ, Honavar SG, Naik MN, Vemuganti GK. Malherbe's calcifying epithelioma (Pilomatrixoma): An uncommon periocular tumor. Int J Trichology. 2011; 3: 31–3. [PMCID: PMC3129122] [PubMed: 21769234]
12. Graham JL, Merwin CF. The tent sign of pilomatricoma. Cutis. 1978; 22: 577–80. [PubMed: 729402]
13. Lemos MM, Kindblom LG, Meis-Kindblom JM, Ryd W, Willén H. Fine-needle aspiration features of pilomatrixoma. Cancer. 2001; 93: 252–6. [PubMed: 11507698]
14. Agrawal L, Kaur P, Singh J, Singh N. Pilomatrixoma misdiagnosed as round cell tumor on fine-needle aspiration cytology. Indian J Cancer. 2010; 47: 483–5. [PubMed: 21131775]
15. Ishita Pant, Sanjeev Chandra Joshi, Gurjeet Kaur, and Gokula Kumar. Pilomatricoma as a diagnostic pitfall in clinical practice: report of two cases and review of literature. Indian J Dermatol. 2010 Oct-Dec; 55(4): 390–392. [PubMed: 3051306]
16. Goufman DB, Murrell GL, Watkins DV. Pathology forum. Quiz case 2. Pilomatricoma (calcifying epithelioma of Malherbe) Arch Otolaryngol Head Neck Surg. 2001; 127: 218–20. [PubMed: 11177046]

REVIEW ARTICLE

AUTHORS:

1. Sunil S. Byadgi
2. Sachin Biradar
3. Dinesh L. Jadhav
4. P. Shashikala
5. S. B. Gejji

PARTICULARS OF CONTRIBUTORS:

1. Professor, Department of General Surgery, S. S. Institute of Medical Sciences and Research Centre, Davanagere.
2. Post Graduate, Department of General Surgery, S. S. Institute of Medical Sciences and Research Centre, Davanagere.
3. Associate Professor, Department of General Surgery, S. S. Institute of Medical Sciences and Research Centre, Davanagere.

FINANCIAL OR OTHER

COMPETING INTERESTS: None

4. Professor & HOD, Department of Pathology, S. S. Institute of Medical Sciences and Research Centre, Davanagere.
5. Professor & HOD, Department of General Surgery, S. S. Institute of Medical Sciences and Research Centre, Davanagere.

NAME ADDRESS EMAIL ID OF THE CORRESPONDING AUTHOR:

Dr. Sachin Biradar,
Department of General Surgery,
S. S. Institute of Medical Sciences and
Research Centre, Jnanashankara,
NH-4 Bypass Road, Davanagere-577005.
E-mail: healers.llch@gmail.com

Date of Submission: 23/05/2015.

Date of Peer Review: 25/05/2015.

Date of Acceptance: 24/06/2015.

Date of Publishing: 01/07/2015.