

# CASE REPORT

## NASOLABIAL CYST: A CASE REPORT

V. S. Sharma<sup>1</sup>, M. V. Subba Rao<sup>2</sup>, Venkata Ramana<sup>3</sup>, Jagannath Prasad<sup>4</sup>, Pravin Tez<sup>5</sup>

### HOW TO CITE THIS ARTICLE:

V. S. Sharma, M. V. Subba Rao, Venkata Ramana, Jagannath Prasad, Pravin Tez. "Nasolabial CYST: A Case Report". Journal of Evolution of Medical and Dental Sciences 2015; Vol. 4, Issue 56, July 13; Page: 9855-9858, DOI: 10.14260/jemds/2015/1425

**ABSTRACT:** Nasolabial cyst is a rare nonodontogenic, soft-tissue cyst occurring in the sublabial area and anterior maxillary region. The cyst is derived from epithelial cells retained in the mesenchyme after fusion of the medial and lateral nasal processes and the maxillary prominence during fetal life due to the persistence of epithelial remnants from the nasolacrimal duct extending between the lateral nasal process and the maxillary prominence. The patient usually presents with a slowly enlarging asymptomatic swelling. They are usually diagnosed in early stages because of cosmetic problems. In our paper we report a nasolabial cyst of a 62-year-old female and discuss the diagnosis, differential diagnosis, treatment and review of literature.

**KEYWORDS:** Nasolabial cyst, Odontogenic cyst, Non-odontogenic cyst, Nasopalatine cyst, Palatine cyst.

**INTRODUCTION:** Nasolabial cysts are very rare nonodontogenic soft-tissue lesions of nasal vestibule, fossa canina, and sublabial region. The lesions cause painless swelling in sublabial fold, upper lip, face and cause nasal obstruction. Pain can occur if the cyst becomes infected. The incidence of the cyst is 0.7% in overall chin cysts.<sup>[1]</sup> The initial diagnosis, and treatment is usually made in early stages because the lesion causes cosmetic problems; very rarely it becomes large in dimensions.

**CASE REPORT:** A 62-years-old female was admitted to the ENT Department with complaints of a swelling in the right side of face adjacent to the nose from past 4 years which was insidious in onset and slowly progressing in size and was associated with obstruction in the right nostril. There was no history of bleeding, discharge from nose, pain, fever or h/o tooth extraction. The past medical history was insignificant.

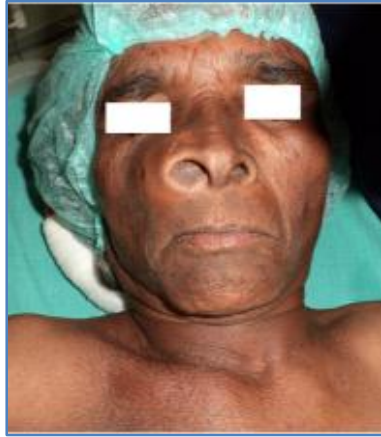On otolaryngologic examination, there was a swelling of size 5cms x 4cms corresponding to the anatomic location of the nasolabial fold extending into the right nasal cavity. The swollen area was presenting in the sublabial region, intraorally which was firm and nontender on palpation. The floor of nasal cavity was swollen which narrowed the nasal passage. (Figure 1 )

Palate and teeth were normal. Findings on blood and serum biochemistry were within normal limits. The CT scan revealed a cyst in nasolabial area (Figure 2).

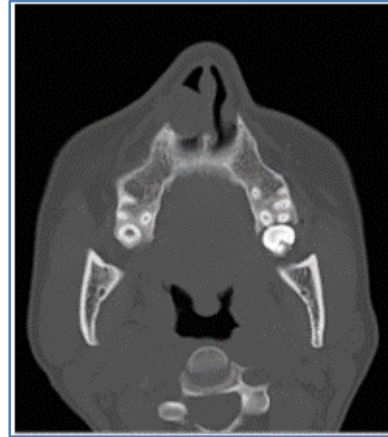## CASE REPORT

**Figure 1:** Preoperative view of the lesion in nasolabial fold.

**Figure 2:** CT scan of the lesion showing hypodense cystic lesion superficial to anterior wall of maxilla extending into the nasal cavity. There is no evidence of bony erosion.



**Fig. 1**

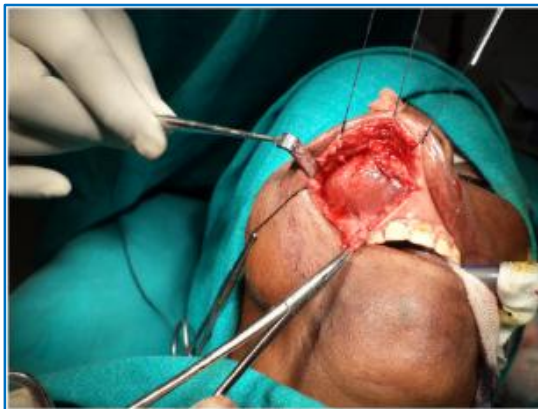

**Fig. 2**

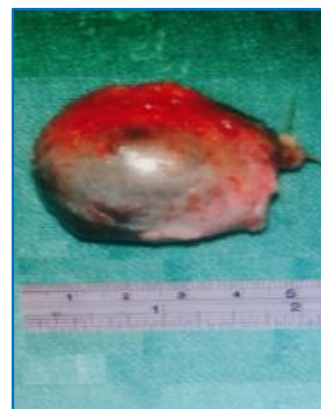Under general anaesthesia a sublabial incision (Figure 3) was made. The cyst was dissected free from the surrounding structures and excised (Figure 4) and the wound was closed in layers. There were no postoperative complications. The histopathological examination revealed nasolabial cyst. (Figure 5). The patient came for follow up after 4 weeks and found to have free nasal passage and sublabial incision healed well. (Figure 6)

**Figure 3:** Cyst being enucleated with a Sublabial incision.

**Figure 4:** Post-surgical photograph showing Excised specimen.



**Fig. 3**

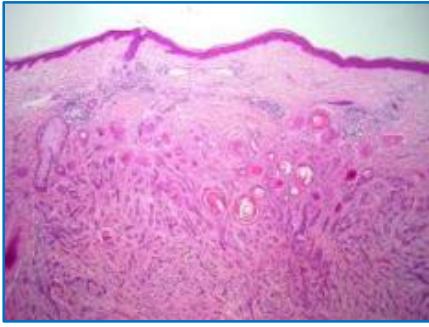


**Fig. 4**

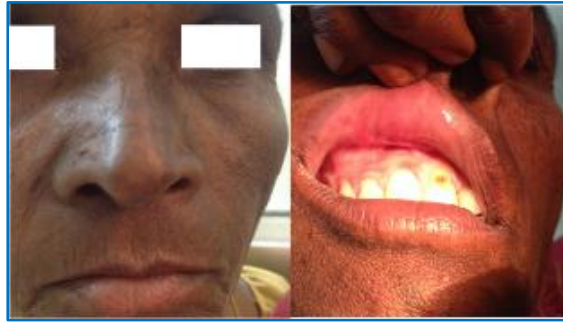**Figure 5:** Histopathology report showed cyst wall lined by flattened epithelium foci showing abundant eosinophilic material suggestive of a cyst.

**Figure 6:** Showing post-operative picture during follow up after 4 weeks.

## CASE REPORT



**Fig. 5**



**Fig. 6**

**DISCUSSION:** Nasolabial cysts were first described by Zuchercandl in 1892<sup>[2]</sup> they are non odontogenic masses that can be seen in the maxillofacial area. In the literature, the lesions are named as nasolabial cyst, nasoalveolar cyst and Klestadt's tumour<sup>[2]</sup> The lesion is sub mucosal and extraosseous, it expands via the gingivobuccal sulcus and expands all the soft-tissues outwards. Usually the cysts are seen in the 4th-5th decade of lifetime. The incidence of bilateral cyst is 10% in the literature.<sup>[3]</sup> The Nasolabial cyst is formed embryologically by detention cells from the inferior nasolacrimal channel endodermal cells<sup>[4]</sup> Exposure to trauma accelerates the formation of the cyst.

**The differential Diagnosis of the cyst must be made with:**

1. Median alveolar cyst which is present as a cyst separating the upper central incisor teeth.
2. Median palatal cyst which lies between the palatine processes of the developing maxillae.
3. Nasopalatine cyst which is seen arising from tissues in the incisive canal or nests in the papilla palatine and present either on the palate or on the nasal floor.
4. Lateral alveolar cyst present at the line of fusion of maxillary and premaxillary elements of the palate, so as to cause separation of canine and lateral incisor teeth.
5. Dentigerous cyst usually arises from the follicle around an unerupted tooth.
6. Dental cyst which arise from epithelial remains in the periodontal membrane.

Other uncommon differential diagnosis of an nasolabial cysts could be cyst of maxilla, odontogenic cysts, periapical cysts, periapical granulomas, epidermal inclusion cyst, furunculosis of base of the nose, and neoplasms of base of the nose.<sup>[5]</sup> The safety of the teeth in the nasolabial region is clinically important in differentiating from the other lesions. Radiological examination is important in differential diagnosis of odontogenic and nonodontogenic cysts of the region. We expect no erosion of bone especially in the early stages of the disease.<sup>[6]</sup> The diagnosis of the lesion can be made by clinical, radiologic examination and histopathological examination.

The treatment can be made by surgical excision, injection of sclerozing materials in the cyst, and endoscopic marsupialization methods,<sup>[7]</sup> Excision of the cyst via the sublabial incision is the most preferred treatment modality with very low recurrence rate and cosmetic reasons. Sublabial incision is preferred to external incision especially for cosmetic reasons. Recurrence does not happen if the wall of the sac is completely removed. There is a reported case of malignant degeneration of the cyst in the literature.<sup>[8]</sup> The nasolabial cysts can be marsupialized transnasally under the guidance of nasal endoscopes<sup>[9]</sup> Nasolabial cyst must be kept in mind in differential diagnosis of nasal vestibule, nasal base, and sublabial area.<sup>[10]</sup>

# CASE REPORT

## REFERENCES:

1. El-Din K, el-Hamd A A. Nasolabial cyst: a report of eight cases and a review of the literature. *Journal of Laryngology and Otology*. 1999; 113(8): 747–749. [PubMed]
2. Kuriloff D B. The nasolabial cyst-nasal hamartoma. *Otolaryngology-Head and Neck Surgery*. 1987; 96(3): 268–272. [PubMed]
3. Barzilai M. Case report: bilateral nasoalveolar cysts. *Clinical Radiology*. 1994; 49(2): 140–141. [PubMed]
4. Nixdorf DR, Peters E, Lung KE. Clinical presentation and differential diagnosis of nasolabial cyst. *Journal of the Canadian Dental Association*. 2003; 69(3): 146–149. [PubMed]
5. Choi JH, Cho JH, Kang HJ, et al. Nasolabial cyst: a retrospective analysis of 18 cases. *Ear, Nose and Throat Journal*. 2002; 81(2): 94–96. [PubMed]
6. Hashida T, Usui M. CT image of nasoalveolar cyst. *British Journal of Oral and Maxillofacial Surgery*. 2000; 38(1): 83–84. [PubMed]
7. Su C-Y, Chien C-Y, Hwang C-F. A new transnasal approach to endoscopic marsupialization of the nasolabial cyst. *Laryngoscope*. 1999; 109(7): 1116–1118. [PubMed]
8. López-Ríos F, Lassaletta-Atienza L, Domingo-Carrasco C, Martinez-Tello FJ. Nasolabial cyst: report of a case with extensive apocrine change. *Oral Surgery, Oral Medicine, Oral Pathology, Oral Radiology, and Endodontics*. 1997; 84(4): 404–406. [PubMed]
9. Jae Yong L, Byoung Joon B, Jang Yul B, Hyuck Soon C, Byung Don L, Dong Wook K. Comparison of conventional excision via a sublabial approach and transnasal marsupialization for the treatment of nasolabial cysts: a prospective randomized study. *Clinical and Experimental Otolaryngology*. 2009: 85–89. [PMC free article][PubMed]
10. Choi JH, Cho JH, Kang HJ, et al. Nasolabial cyst: a retrospective analysis of 18 cases. *Ear, Nose and Throat Journal*. 2002; 81(2): 94–96. [PubMed]

## AUTHORS:

1. V. S. Sharma
2. M. V. Subba Rao
3. Venkata Ramana
4. Jagannath Prasad
5. Pravin Tez

4. Assistant Professor, Department of ENT, Medciti Institute of Medical Sciences, Medchal, Hyderabad.
5. Resident, Department of ENT, Medciti Institute of Medical Sciences, Medchal, Hyderabad.

## PARTICULARS OF CONTRIBUTORS:

1. Assistant Professor, Department of ENT, Medciti Institute of Medical Sciences, Medchal, Hyderabad.
2. Professor and HOD, Department of ENT, Medciti Institute of Medical Sciences, Medchal, Hyderabad.
3. Professor, Department of ENT, Medciti Institute of Medical Sciences, Medchal, Hyderabad.

## NAME ADDRESS EMAIL ID OF THE CORRESPONDING AUTHOR:

Dr. V. S. Sharma,  
# 85, Primrose,  
L & T Serene County,  
Gachibowli, Hyderabad-500032,  
Telangana.  
E-mail: sarma\_varanasi@yahoo.com

Date of Submission: 19/06/2015.  
Date of Peer Review: 20/06/2015.  
Date of Acceptance: 04/07/2015.  
Date of Publishing: 13/07/2015.

## FINANCIAL OR OTHER

**COMPETING INTERESTS:** None