

## ASTIGMATIC OUTCOME & POST OPERATIVE RECOVERY IN PATIENTS UNDERGOING PTERYGIUM EXCISION WITH CONJUNCTIVAL AUTOGRAFTS. COMPARISON BETWEEN SUTURE & AUTOLOGUS BLOOD FIBRIN

Smita Dileep Javadekar<sup>1</sup>, Sindal Deokrishna<sup>2</sup>, Kena Joshi<sup>3</sup>, MitMehta<sup>4</sup>.

1. Associate Professor, Department of Ophthalmology, KIMSUDU, Malkapur, Karad
2. Professor & H.O.D, Department of Ophthalmology, KIMSUDU, Malkapur, Karad
3. Resident , Department of Ophthalmology, KIMSUDU, Malkapur, Karad
4. Resident , Department of Ophthalmology, KIMSUDU, Malkapur, Karad

### CORRESPONDING AUTHOR:

Dr. Smita Javadekar,  
Alchemy, Vishrambag,  
Sangli – 416415.  
Maharashtra.  
E-mail: smita10157@yahoo.co.in

### HOW TO CITE THIS ARTICLE:

Smita Dileep Javadekar, Sindal Deokrishna, Kena Joshi, MitMehta. "Astigmatic outcome & Post Operative recovery in Patients undergoing Pterygium Excision with Conjunctival Autografts. Comparison between Suture & Autologous blood Fibrin". Journal of Evolution of Medical and Dental Sciences 2013; Vol2, Issue 23, June 10; Page: 4079-4090.

**ABSTRACT: AIMS:** To review the effect of surgery type on the postoperative recovery & astigmatism in pterygium surgery. **SETTINGS AND DESIGN:** Randomized comparative clinical trial. **MATERIALS AND METHODS:** Forty six patients (46 eyes) with primary pterygium were randomised to undergo pterygium surgery using either autologous fibrin glue (23 eyes) or 10-0 nylon sutures (23 eyes) to attach the conjunctival autograft. The patients were followed up 1day, 1wk, 2wks & 6 weeks. Outcome measures were keratometry changes & postoperative recovery.. The preoperative and postoperative keratometric measurements, evaluated using keratometer, were noted. **RESULTS:** Corneal astigmatism was significantly reduced in the total group from 2.94(SD- 0.52) diopter to 1.91 (sd 0.57) diopter ( $p < 0.001$ ) The reduction in astigmatism was not significantly different between the two groups

In the autologous fibrin glue group, the mean operation time was 13.96 (SD 3.2) min (range 10-20 min) and in the suture group ( $p < 0.001$ ) it was 29.78 (SD 4.6) min (range 20-35 min).

One patient in each group had partial graft dehiscence; it was successfully reattached with autologous fibrin / sutures accordingly ( $p > 0.05$ ).

The intensity of the postoperative watering, itching, were significantly lower in the autologous fibrin glue group than in the suture group ( $p < 0.001$ ). Postoperative redness was absent in 47.82% (11cases) and mild in 52.18% (13 cases) 2 weeks postoperatively in the autologous fibrin group while in sutured group 17.4% (4cases) had mild redness and 82.6% (19 cases) had moderate redness 2weeks postoperatively. **CONCLUSION:** Corneal astigmatism is reduced by

# ORIGINAL ARTICLE

---

conjunctival autografting with autologous fibrin significantly & similarly as with sutures. It also reduces surgery time with successful adherence of the auto graft and improves postoperative comfort. There are no expenses like suture & synthetic glue so there is no economical burden on the patient.

**KEY WORDS:** Pterygium, Autologous fibrin, Sutures, Conjunctival autograft, Astigmatism, Operating time, Itching, Redness

**INTRODUCTION:** Pterygium is a degenerative condition (elastotic) of bulbar subconjunctival tissues which proliferate as vascularized granulation tissue to invade the cornea, destroying the superficial layers of the stroma and Bowman's membrane, the whole being covered by conjunctival epithelium.

It is either on nasal/ temporal side in inter-palpebral area which is maximally exposed to ultraviolet rays. It is common in Asian countries due to dry sunny climates (2.4 to 30%)<sup>1</sup>. Pterygium is known to affect refractive astigmatism,<sup>2,3</sup> which can have a significant impact on vision. Several mechanisms have been suggested to explain the induced astigmatism. These include pooling of the tear film at the leading edge of the pterygium and mechanical traction exerted by the pterygium on cornea.<sup>3</sup> Surgical excision is indicated in

- 1 Extreme irritation
- 2 Diminished vision due to Astigmatism/ progression towards pupillary area
- 3 Restriction of eyeball movement
- 4 Cosmetic blemish

**NEED FOR STUDY:** For long time simple excision leaving behind bare sclera was the surgical treatment for pterygium. It has a significant recurrence rate ( 24 – 89%)<sup>4</sup> Conjunctival autograft of the bare sclera was used in 1985, by Kenyon et al <sup>5</sup> in treatment of recurrent and advanced pterygium. Autologous bulbar conjunctival transplantation has been shown to decrease the incidence of recurrence to about 5%. Sutures were used to attach the graft in position but it requires longer operating time & surgical experience. Postoperative discomfort, and local complications like scarring, infection, foreign body granuloma and chronic inflammation were also observed more.<sup>6,7</sup> Later fibrin glue was used in place of sutures which reduced operating time and post operative complications associated with sutures. The use of fibrin glue <sup>8,9,10,11</sup> above sutures improved comfort, decreased surgical time, reduced complication and lowered the recurrence rates. Fibrin glue since it is a plasma derivative it may produce allergic reactions in susceptible individuals, and there is a risk of transmission of viral diseases. Its high cost prevents its use for all types of population. Sutureless grafting has been used successfully in gingival grafts<sup>12</sup> and represents a similar mucosal membrane tissue environment to the conjunctiva of the eye.

The new method of using patient's own blood (**Autologous fibrin**) to attach graft to recipient site reduces the operating time, suture related post operative complications, over comes complications of glue, also reduces economic burden.

Astigmatic change after surgery by sutures & Fibrin glue are similar.(i.e. there is no significant difference )

## AIMS & OBJECTIVES

# ORIGINAL ARTICLE

---

- 1 To compare astigmatic change post operatively in both groups
- 2 To compare operating time in two groups (Autologous fibrin & sutures)
- 3 To compare post operative comfort in two groups.

## **MATERIALS & METHODS:**

### **SOURCE OF DATA**

Patients having pterygium registered in Ophthalmology OPD at Krishna Hospital, Malkapur, Karad, Maharashtra.

### **STUDY DESIGN**

Randomized clinical trial

### **DURATION**

1 year (Feb. 2012 to Jan. 2013)

### **SAMPLE SIZE**

Group 1 Autologous fibrin N = 23, Group 2 Sutures N = 23

### **INCLUSION CRITERIA**

Patients having nasal pterygium covering 2mm or more cornea, who gave consent for the study.

### **EXCLUSION CRITERIA**

Patients giving H/O Ocular surface infections, Ocular trauma  
H/O Bleeding disorder, anticoagulant therapy

**METHODOLOGY:** Patients having pterygium were enrolled into study after taking informed & written consent. After detailed ocular and systemic history, a thorough ocular examination including visual acuity, refraction, keratometry, ocular movements, fluorescein staining and slit lamp examination was carried out according to routine Ophthalmological proforma.

Preliminary investigations (CBC, BSL, Routine urine, ECG) were done in each & every patient

Physical fitness was taken by Physician to undergo surgery under local anaesthesia.

Patients were then randomized into two groups

- 1 Conjunctival autograft with autologous fibrin (blood)
- 2 Conjunctival autograft with sutures

**PROCEDURE:** Single surgeon performed all surgeries under operating microscope.

Peribulbar anaesthesia was given to all patients so that akinesia remaining for few hours is likely to prevent displacement of the graft.

Pterygium was excised and bare sclera was replaced by conjunctival autograft taken from upper bulbar part of conjunctiva..

In first group haemostasis was allowed to occur spontaneously without the use of cautery & autograft was attached to underlying episcleral bed by patient's own blood from limbal vessels (Autologous fibrin)

In second group autograft was sutured by 10-0 Nylon sutures (interrupted) to the surrounding conjunctiva

At the end of surgery subconjunctival Gentamicin along with dexamethasone was injected.

# ORIGINAL ARTICLE

The Operation duration was considered as the time from when the lid retractor was placed until its removal at the end of surgery

After surgery, all patients were prescribed topical Ofloxacin dexamethasone combination drops 4 times daily for 2 weeks.

All patients were examined on slit lamp 24 hrs, 1week, 2weeks, 6weeks postoperatively  
Efficacy of surgery was noted by Noting keratometry reading & BCVA 6 weeks post operatively  
Noting operating time in both groups

Noting redness as absent, mild, moderate,& severe by slit lamp examination comparing with clinical photographs.(Srinivasan et al <sup>13</sup> also used standardized slit lamp photographs)

Noting post operative discomfort like watering, itching in both groups.

**STATISTICAL ANALYSIS:** Operating time & keratometry readings were summarized by mean and standard deviation and were analyzed by 't' test.

Post operative comfort was summarized by rates and analyzed by Chi Square test

**RESULTS:** There were 23 patients in each group. In the group undergone sutured surgery there were 5males & 18 females. Minimum age in females was 26years & maximum was 70 years. Minimum age in males was 36years & maximum was 76years.

Table 1: Gender wise age (in years) of patients in Sutured group

Gender	N	Minimum	Maximum	Mean	Std. Deviation	't' value (p value)
Male	5	36	76	56.00	14.883	0.416
Female	18	26	70	52.94	14.465	(0.682)
Total	23	26	76	53.61	14.269	

In the group undergone surgery autologous fibrin glue there were 10 males & 13 females. Minimum age in females was 30years & maximum was 65 years. Minimum age in males was 36years & maximum was 65years.

Table 2: Gender wise age (in years) of patients in Autologous fibrin group

Gender	N	Minimum	Maximum	Mean	Std. Deviation	't' value(p value)
Male	10	36	65	46.10	8.452	1.539
Female	13	30	65	52.69	11.309	(0.139)
Total	23	30	65	49.83	10.495	

Table 3: Gender wise comparison of Age [Sutured v/s Autologous fibrin]:

Gender	't' value	p value
Male	1.667	0.119
Female	0.052	0.959
Total	1.024	0.311

## ORIGINAL ARTICLE

Table 4: Pre operative & post operative 6 weeks difference in astigmatism

Type of surgery	Mean pre op. K	Sd	Mean Post op. K	Sd	p value
Autologous Fibrin	2.7 D	0.45 D	1.7 D	0.4 D	<0.001
Sutured	3.18 D	0.47 D	2.13 D	0.64 D	<0.001

There was significant difference in pre operative & post operative astigmatism in both the groups ( $p < 0.001$ ),

Table 5: Comparison of differences in K value of both groups

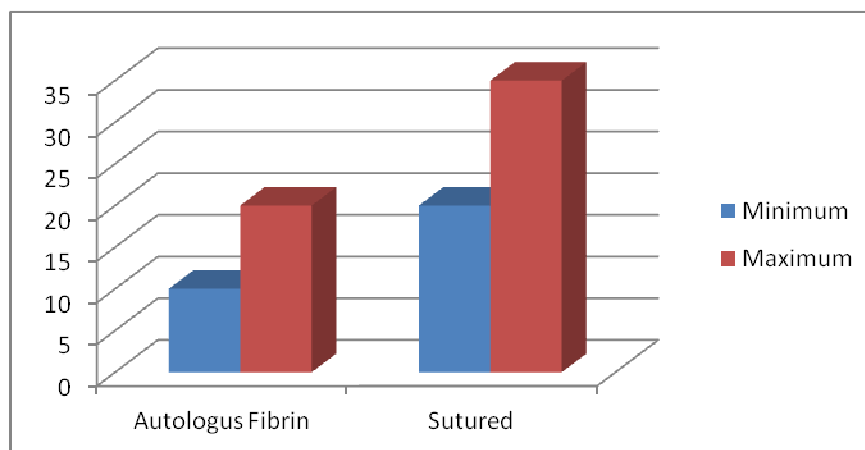
Type of surgery	Mean diff. in K	Sd	p value
Autologous Fibrin	1 D	0.33 D	
Sutured	1.05 D	0.35 D	0.597

There was no significant difference if both groups are compared ( $p > 0.001$ )

Table 6: Operating time in minutes in both groups

Operating time in minutes in both groups

Type of Surgery	Number	Minimum	Maximum	Mean	Std dev.
Autologous fibrin	23	10	20	13.96	3.212
Sutured	23	20	35	30	4.641



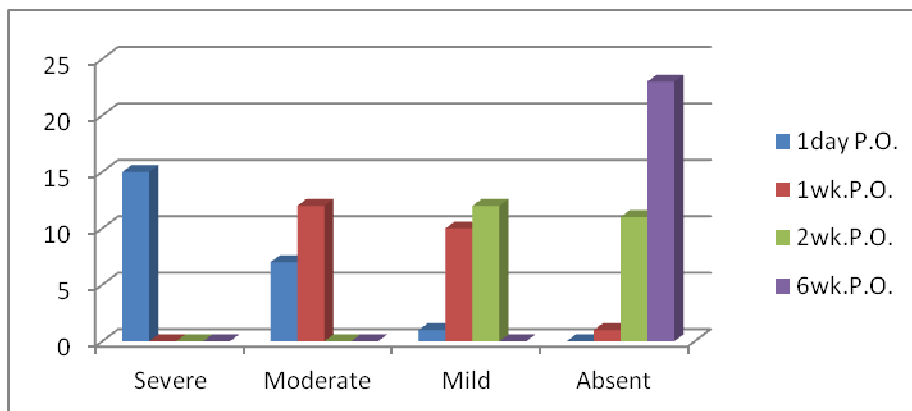
The operation duration was 13.96 (SD 3.212) minutes in the Autologous fibrin group while it was 30 (sd 4.641) in sutured group

Operative time was significantly lower in autologous fibrin group as compared to sutured group. ( $p < 0.001$ )

Table 7: Postoperative severity of redness in Autologous Fibrin group

Redness	Severe	Moderate	Mild	Absent
1day P.O.	15	7	1	0
1wk.P.O.	0	12	10	1
2wk.P.O.	0	0	12	11
6wk.P.O.	0	0	0	23

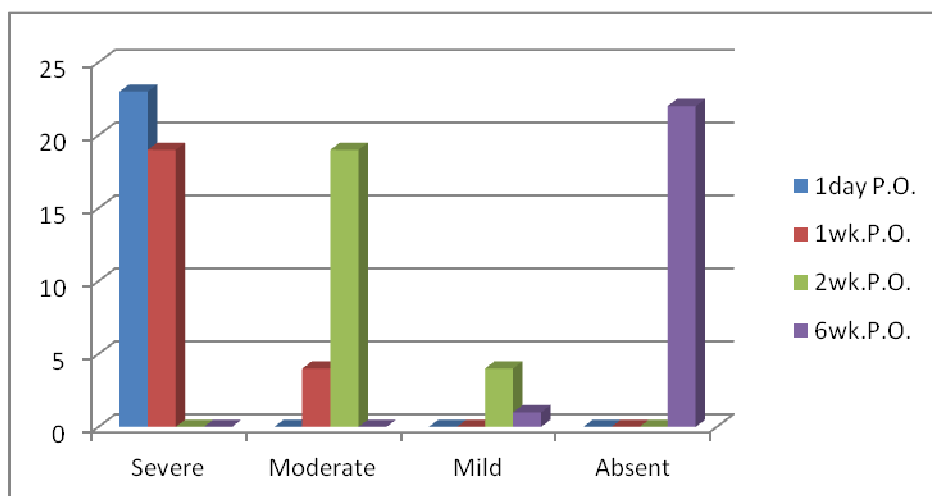
## ORIGINAL ARTICLE



In autologous fibrin group 15(65.21%) cases were severely red on first follow up while none of the case was like on further follow-ups. 7(30.43%) cases were having moderate redness on first follow up & 12(52.17%) on second but none of the cases were having it on next follow-ups. Only one (4.34%) case was having mild redness on first follow up. The number increased to 10(43.47%) & 12(52.17%) on successive follow-ups & there was no case having any type of redness on 6 week's follow up. Thus on first follow up all cases were having mild to severe redness but in 1 (4.34%) case on 1week & in 11(47.82%) cases on 2week follow up redness was absent. On last 6week's follow up redness was absent in all (100%) cases.

Table 8: Postoperative severity of redness in sutured group

Redness	Severe	Moderate	Mild	Absent
1day P.O.	23	0	0	0
1wk.P.O.	19	4	0	0
2wk.P.O.	0	19	4	0
6wk.P.O.	0	0	1	22



In sutured group eyes of all cases (100%) were severely red on first follow up. The number decreased to 19(82%) on 1week follow up & on 2week, 6week follow up there was no case with severe redness.

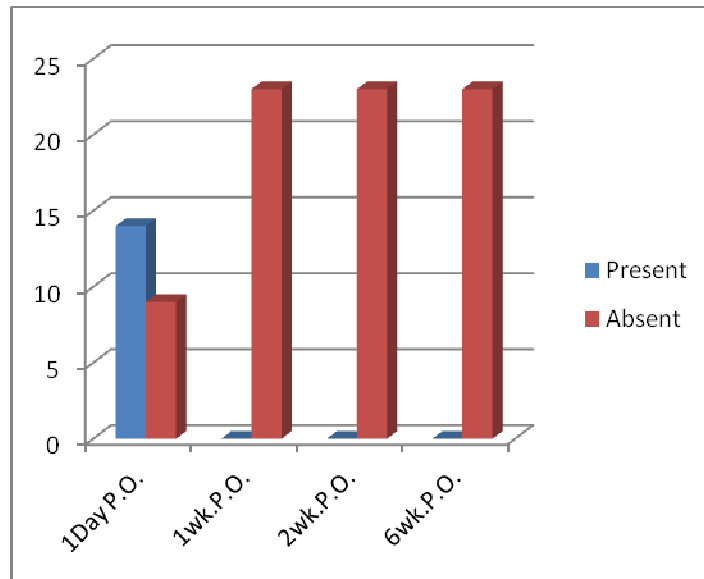
## ORIGINAL ARTICLE

There was no case with moderate redness on first follow up, but 4(17.39%) & 19(82%) cases were on 1week & 2week follow up respectively. On last follow up not a single case was having moderate redness.

On first two follow ups there was no case with mild redness but 4(17.39%) cases on 2week & 1(4.34%) case on 6week follow up was having mild redness.

Table 9: Postoperative watering in Autologous Fibrin group

Watering	Present	Absent
1Day P.O.	14	9
1wk.P.O.	0	23
2wk.P.O.	0	23
6wk.P.O.	0	23

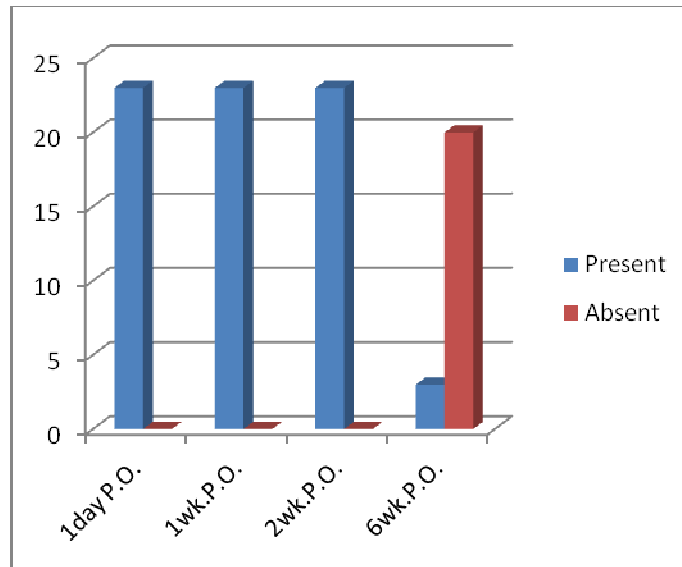


In autologous fibrin group watering was absent in 9(39.13%) cases on first follow up and was absent in all (100%) cases from 1week onwards. ( $p < 0.001$ )

Table 10: Postoperative watering in sutured group

Watering	Present	Absent
1day P.O.	23	0
1wk.P.O.	23	0
2wk.P.O.	23	0
6wk.P.O.	3	20

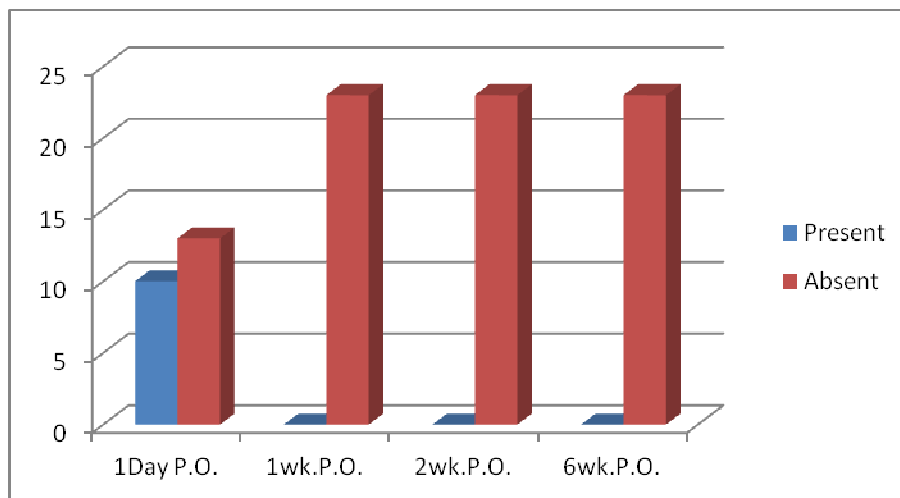
## ORIGINAL ARTICLE



In sutured group all cases (100%) were having watering on first 3 follow ups. Only on last follow up of 6week only 3(13, 04%) cases were having watering while it was absent in remaining (86.95%) cases

Table 11: Postoperative itching sensation in Autologus Fibrin group

Itching	Present	Absent
1Day P.O.	10	13
1wk.P.O.	0	23
2wk.P.O.	0	23
6wk.P.O.	0	23

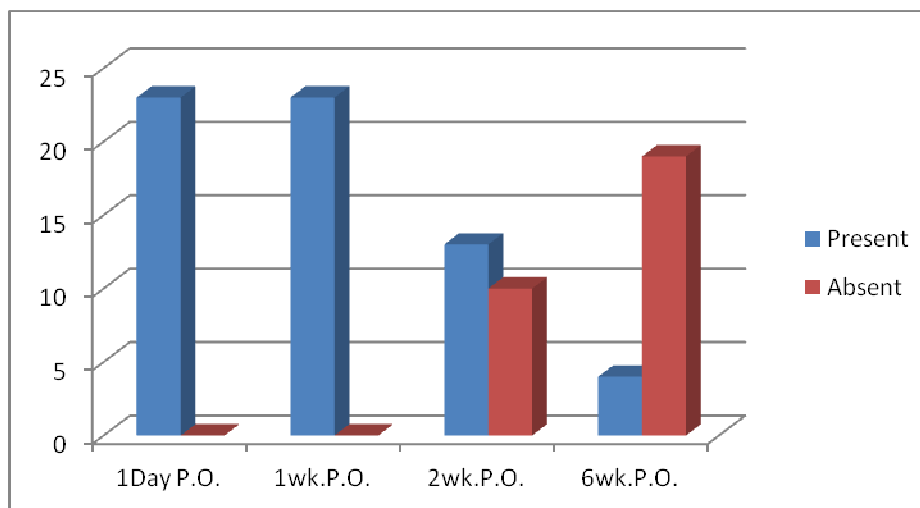


In autologous fibrin group itching was absent in 13(56.52%) on first follow up (1day p.o.) and was absent in all cases (100%) from 1week onwards ( $p < 0.001$ ).



Table 12: Postoperative itching sensation in sutured group

Itching	Present	Absent
1Day P.O.	23	0
1wk.P.O.	23	0
2wk.P.O.	13	10
6wk.P.O.	4	19



In sutured group all (100%) had itching on first two follow ups. Number of cases having itching reduced to 13(56, 52%) on 2week ( $p>0.001$ ) follow up & to 4(17.39%) on last follow up.

Postoperative dehiscence of the graft was displaced in two cases one case in each group which was replaced immediately.

There were no intra- or post-operative complications requiring further treatment. Visual acuities were not affected in any of the patients.

From all above observations it is seen that Post operative astigmatic change at end of 6weeks in both groups was significant ( $p<0.001$ ) but if this difference is compared of both groups it is insignificant ( $p>0.001$ )

Patients in whom autologous fibrin was used were almost recovered at the end of 2weeks except mild redness in 55.18% cases which is insignificant. Operating time was also significantly less ( $p<0.001$ ) in this group.

While patients in whom sutures were used operating time was significantly more as well as post operative discomfort was also significantly more at the end of 2weeks( $p< 0.001$ )

**DISCUSSION:** Various methods prevent pterygium recurrence such as conjunctival autograft, limbal and limbal–conjunctival transplant, conjunctival flap and conjunctival rotation autograft surgery, amniotic membrane transplant, cultivated conjunctival transplant, lamellar keratoplasty, and the use of fibrin glue.<sup>14</sup> All these methods use sutures or fibrin glue. Therefore patients are exposed to their complications. Usually sutures are used to attach graft but it requires longer operating time, surgical experience, postoperative discomfort, and it has local complications like scarring, infection, foreign body granuloma <sup>10,6,11</sup>. Complications such as symblepharon formation, forniceal contracture, ocular motility restriction, diplopia, scleral necrosis, and infection are much more

difficult to manage and may be sight threatening.<sup>15,16</sup> Fibrin glues are safe but they are derived from human plasma so there is theoretical risk of transmissible disease<sup>14</sup>. Fibrinogen products are deactivated by iodine solutions used to prepare conjunctiva<sup>17</sup> Srinivasan et al<sup>13</sup> reported no difference in inflammation between the fibrin glue or suture group at 1 week, but inflammation was reduced significantly in the fibrin glue group after 1 to 3 months. On the contrary, we reported significantly less inflammation in the autologous fibrin glue group than suture group at 1 week, and no difference in inflammation between these groups at 1 month. This could be due to use of autologous fibrin in our study.

Kampitak concluded that the amount of induced corneal astigmatism and timing for pterygium excision are related to the pterygium size, and reported that 2.25 mm pterygium resulted in astigmatism of 2 D, and should be considered in the limits of surgery.<sup>1</sup>

Contrary to our results, some studies show no correlation between these 2 parameters.<sup>19,20,21</sup> This contradiction might be related to the larger horizontal pterygium sizes in present study. In conclusion, pterygium results in high corneal astigmatism, which increases with the increase in horizontal length, and decreases to an acceptable level following excision. We found a significant correlation between the preoperative and postoperative astigmatic values as well as the changes in astigmatism with surgery.

In our study we found that there was no significant difference in reduction of astigmatism if both groups are compared. This correlates well with other studies.<sup>22</sup>

Our study has limitations of small sample size & short follow up. But our aim was to study reduction in astigmatism along with surgical time & post operative discomfort by using autologous fibrin. Surgical time in our small series appears no greater than current published literature.<sup>18</sup> A prospective randomised controlled trial is required to investigate the long-term efficacy of this autologous grafting technique in reducing recurrences.

**CONCLUSION:** Corneal astigmatism is significantly reduced by conjunctival autografting with autologous fibrin. These results are same as with sutures. It also reduces surgery time with successful attachment of the auto graft and improves postoperative comfort. There is no economical burden on the patient because there are no expenses like suture & commercial glue. So we recommend use of patient's own blood (autologous fibrin) as glue in pterygium excision with conjunctival autograft.

### REFERENCES:

1. Donnenfeld ED, Perry HD, Fromer S, et al. Subconjunctival mitomycin C as adjunctive therapy before pterygium excision. *Ophthalmology*. 2003; 110: 1012-26
2. Kampitak K. The effect of pterygium on corneal astigmatism. *J Med Assoc Thai*
3. Maheshwari S. Effect of pterygium excision on pterygium induced astigmatism. *Indian J Ophthalmol* 2003; 51:187-8.
4. Jaros PA, DeLuise VP. Pingueculae and pterygia *Surv Ophthalmol*. 1988; 33: 1-9.
5. Kenyon KR, Wagoner MD, Hettinger ME. Conjunctival autograft transplantation for advanced and recurrent pterygium. *Ophthalmology* 1985; 92: 1461-1470.
6. Allan BD, Short P, Crawford GJ, Barrett GD, Constable IJ. Pterygium excision with conjunctival autografting: an effective and safe technique. *Br J Ophthalmol* 1993; 77:698-701.

## ORIGINAL ARTICLE

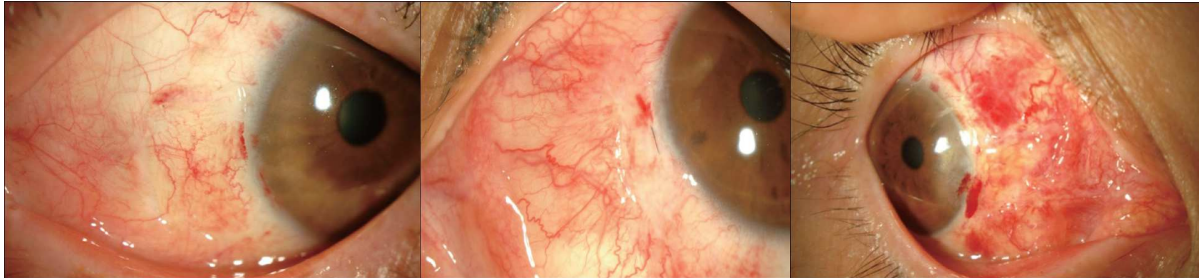
---

7. Tan D. Conjunctival grafting for ocular surface disease. *Curr Opin Ophthalmol* 1999; 10: 277–281.
8. Ayala M. Results of pterygium surgery using a biologic adhesive. *Cornea* 2008; 27: 663–6674  
Koranyi G, Seregard S, Kopp ED. Cut and paste: a no suture, small incision approach to pterygium surgery. *Br Ophthalmol* 2004; 88: 911–914.
9. Kim HH, Mun HJ, Park YJ, Lee KW, Shin JP. Conjunctivo-limbal autograft using a fibrin adhesive in pterygium surgery. *Korean J Ophthalmol* 2008; 22: 147–154.
10. Koranyi G, Seregard S, Kopp ED. Cut and paste: a no suture, small incision approach to pterygium surgery. *Br J Ophthalmol* 2004; 88: 911–914.
11. Koranyi G, Seregard S, Kopp ED. The cut-and-paste method for primary pterygium surgery: long-term follow up. *Acta Ophthalmologica Scandinavica* 2005; 83: 298–301
12. Dorfman HS, Kennedy JE, Bird WC. Longitudinal evaluation of free autogenous gingival grafts. A four year report. *J Periodontol* 1982; 53: 349–352.
13. Srinivasan S, Dollin M, McAllum P, et al. Fibrin glue versus sutures for attaching the conjunctival autograft in pterygium surgery: a prospective observer masked clinical trial. *Br J Ophthalmol* 2009;93:215-8.
14. Ang LP, Chua JL, Tan DT. Current concepts and techniques in pterygium treatment. *Curr Opin Ophthalmol* 2007; 18:308–313.
15. Solomon A, Pires RT, Tseng SC. Amniotic membrane transplantation after extensive removal of primary and recurrent pterygia. *Ophthalmology* 2001; 108: 449–460.
16. Vrabec MP, Weisenthal RW, Elsing SH Subconjunctival fibrosis after conjunctival autograft. *Cornea* 1993; 12:181–183.
17. Gilmore OJ, Reid C. Prevention of intraperitoneal adhesions: a comparison of noxythiolin and a new povidone–iodine/PVP solution. *Br J Surg* 1979; 66: 197–199.
18. . McLean C. Pterygium excision with conjunctival autografting. *Br J Ophthalmol* 1994; 78(5): 421.
19. Bahar I, Loya N, Weinberger D, Avisar R. Effect of pterygium surgery on cornea topography: A prospective study. *Cornea* 2004; 23:113-7.
20. Cinal A, Yasar T, Demirok A, Topaz H. The effect of pterygium surgery on corneal topography. *Ophthalmic Surg Lasers* 2001; 32:35-40.
21. Errais K, Bouden J, Mili-Boussen I, Anane R, Beltaif O, Meddeb Ouertani A. Effect of pterygium surgery on corneal topography. *Eur J Ophthalmol* 2008; 18:177-81.
22. Pterygium Excision and Limbal Conjunctival Autografting–Astigmatism and Cosmetism Dr. Ankur Midha, Dr. Poonam Jain, Dr. Mukesh Sharma AIOC 2009 PROCEEDINGS

## ORIGINAL ARTICLE

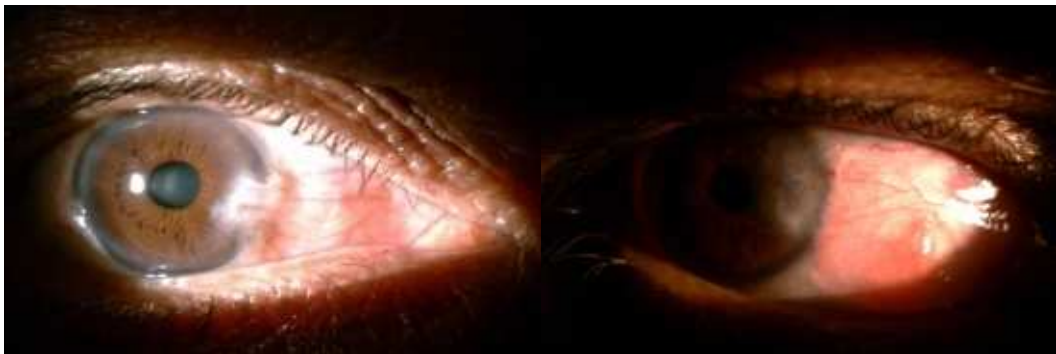All cases were followed up 1day, 1week, 2week & 6 weeks postoperatively for severity of redness of conjunctiva (on slit lamp), watering, & itching

### Redness on slit lamp



Mild Moderate Severe

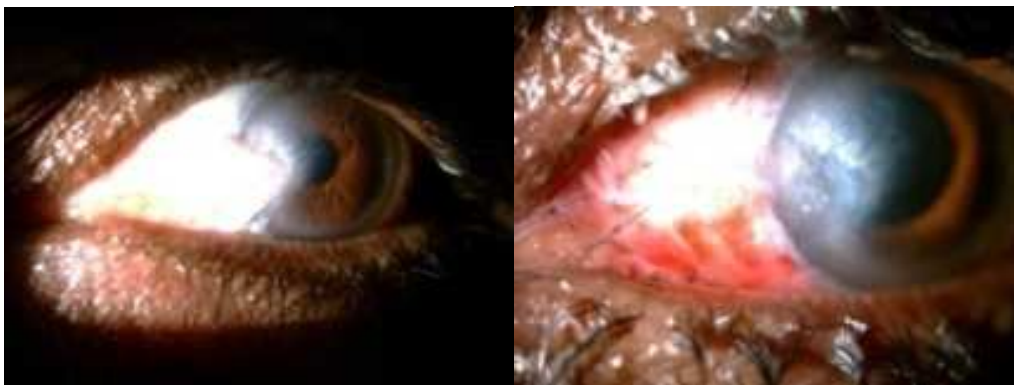
Photographs showing pre operative (A) & post operative 2weeks (B) of autologus fibrin group



A

B

Redness was absent only on last follow up in 22(95.65%) cases. In first 3 follow ups there was not a single case without redness in the sutured group.



A1

B1

Photographs showing preoperative (A1), & post operative 2 weeks (B1) in sutured group