

FUNCTIONAL OUTCOME IN MIDSHAFT CLAVICLE FRACTURE PLATING: OUR EXPERIENCE

Sunirmal Mukherjee¹, Mishil Parikh², Vinay Akka³, Ashith A. Rao⁴, Prakash D. Samant⁵, Ankit Varshneya⁶

HOW TO CITE THIS ARTICLE:

Sunirmal Mukherjee, Mishil Parikh, Vinay Akka, Ashith A. Rao, Prakash D. Samant, Ankit Varshneya. "Functional Outcome in Midshaft Clavicle Fracture Plating: Our Experience". Journal of Evolution of Medical and Dental Sciences 2014; Vol. 3, Issue 32, August 04; Page: 8829-8838, DOI: 10.14260/jemds/2014/3131

ABSTRACT: INTRODUCTION: Fracture of the clavicle constitute approximately up to 44% of injuries to the shoulder girdle most of which (upto 80%) occur in the middle one-third of clavicle shaft. Poor outcomes associated with mal-union and non-union (15%) following middle third clavicle fracture has been observed after conservative treatment of severely displaced fractures. In past few years, many have suggested operative treatment as an alternative to conservative treatment. **AIM:** To analyze the outcomes of the operative management using plate to fix mid-shaft fractures compared to conservative treatment. **MATERIALS AND METHODS:** 33 patients of clavicular fractures were treated conservatively (n=17) and surgically (n=16) according to fracture pattern and patient demands between June 2011 to June 2013 with 1 year of follow-up. Fractures were classified according to Robinson's classification and Constant and Murley shoulder score was used to assess functional outcome. All patients were followed up weekly for 4 weeks then at 8 wks, 12 wks, 6 months and 1 year. Local examination, shoulder movements were assessed and check x-rays were done at each visit. **RESULT:** Our study showed statistically significantly better union time in operative group (~7.8 weeks) compared to conservative group (~9.4 weeks). Malunion was seen in 11 (64.7%) of conserved patients with 1 (5.8%) going into non-union. 81.5% patients in operative group (13 out of 16) had good to excellent functional outcome compared to 58.8% in conservative group (10 out of 17). 4 (23.5%) had poor outcome in conservative group compared to only 1 (6.25%) in operative group. **CONCLUSION:** Our study concludes that operative treatment i.e. Open reduction and internal fixation with plating gives better functional outcome in both short and long term period compared to conservative treatment and the same should be preferred especially for type B variety fracture. Complications seen following surgery were infection (1 patient – 6.25%), implant failure (1 patient – 6.25%) and implant prominence (11 out of 16 patients – 68.7%). However none of the patients agreed for implant removal in view of implant prominence for cosmetic reason at 1 year follow-up.

KEYWORDS: Clavicle plating, functional outcome in clavicle fracture.

INTRODUCTION: Fracture of the clavicle accounts for approximately 5 to 10% of all the fractures and up to 44% of injuries to the shoulder girdle. About 70% to 80% of these fractures are in the middle third of the bone¹. Poor outcomes associated with mal-union and non-union (15%) following middle third clavicle fracture has been observed after conservative treatment of severely displaced fractures.^{2,3} In the past few years newer modalities of treatment have come up with early fixation of fracture with either an intra-medullary device⁴ or an extra-medullary plate.

With intra-medullary fixation complications like loosening and breakage of pins and pin migration and prominence is common.^{5,6} Extra-medullary fixation with plate and screws like Semi-

tubular plate, Dynamic compression plate, Reconstruction plate and low profile precontoured locking plate are used to get rigid fixation with known complications include implant prominence, implant failure, infection, skin related problems like scar and keloid.^{7,8} (Figure 3 and Figure 4).

There is still controversy among many surgeons regarding treatment of middle third clavicle fracture whether to operate or to treat conservatively in an adult patient.⁹⁻¹³ In our study we have analyzed the outcomes of the operative management using plate and screw technique to fix mid-shaft clavicle fractures compared to conservative treatment.

General consensus regarding absolute indication for surgery includes fractures with neuro-vascular deficit. Relative indications include comminuted fracture, severely displaced fracture, irreducible fracture, tenting of skin by displaced fracture fragments, open fractures, floating shoulder, shortening more than 15-20 mm, cosmetic reason and selected fracture non-union who have shoulder girdle dysfunction and are symptomatic.⁹⁻¹³

MATERIALS AND METHODS: In our study 33 patients of clavicular fractures were treated conservatively and surgically according to fracture pattern and patient demands between June 2011 and June 2013 with 1 year of follow-up. Adult patients above 18 years who had middle third clavicle fracture were included for this study after taking written consent from them. Open fractures, fractures associated with complication like head injury and associated other bone injuries were included in this study.

Patients less than 18 years of age, patients with lateral third fracture of clavicle and medial end clavicle were excluded. In our study none of the patients had neuro-vascular complications. 17 patients were treated conservatively and 16 patients were operated at our hospital. Patients for surgery were selected as per indications for surgery and patient's consent. Those with undisplaced fracture and stable fracture reduction and those with good shoulder range of motion post trauma were treated conservatively.

General information like name, age, sex, occupation and address and functional demand of patients were noted. Then a detailed history was noted regarding mode of injury like fall on the shoulder, road traffic accident, direct injury to shoulder and fall on outstretched hand. All patients were examined for pallor, pulse rate and blood pressure. Respiratory and cardio vascular system were examined for any abnormalities. Local examination regarding site of swelling, local skin condition, tenderness and crepitus were noted.

Movements of shoulder were noted which was restricted in most patients. Plain radiograph of clavicle with shoulder in anteroposterior view was taken to assess the site of fracture and the fracture type (displacement and comminution). The fractures were classified according to Robinson's classification.¹⁴ (Figure 2)

Conservative treatment used was Figure of eight bandage with arm sling. In 16 patients who were operated, fixation was done using recon plate (12 patients – 75%) and precontoured low profile locking plate (4 patients – 25%).

Routine investigation like Hb%, Total count, Differential count, ESR, Blood urea, Blood sugar, Serum creatinine, HBsAg and HIV test and ECG, chest x-ray were done before surgery. All patients were operated under general anesthesia in supine position. Incision was made on the anterior aspect centering of clavicle over the fracture site. Minimal soft tissue and periosteum dissection was done. Plate was applied on the superior aspect of clavicle after fracture reduction and proper contouring of

ORIGINAL ARTICLE

plate. (Figure 5) Stopper was used with drill bit to prevent injury to vital structure inferior to clavicle. The plate was fixed to the medial and lateral fragment with 3.5mm cortical screw and at least three screws in medial and lateral fragment were applied.

Wound was closed in layers after ensuring meticulous hemostasis and sterile dressing was applied. Suture removal was done at 10 day post-operative period. All patients of both groups were followed up every week for 4 weeks then at 8 wks, 12 wks, 6 months and 1 year. Local examination regarding skin condition, wound healing, tenderness and shoulder movements were noted in each visit. Check x-rays were done at each visit. (Figure 6) Rehabilitation of the affected extremity were done according to the stage of fracture union and time duration from day of surgery.

Union time more than 8 weeks was considered as delayed and fracture which did not unite till 12 weeks with painless mobility at fracture site was considered as non-union. The functional outcomes were assessed by Constant and Murley score¹⁵ measured at 4 week and 12 week post trauma/ post-operative period.

RESULTS: In our study road traffic accident accounted for 31(93.9%) cases and 2 (6.1%) cases were following fall on outstretched hand. Fracture was seen over age range of 20 yrs. to 75 yrs., more common in second and third decade of life, the average age was 38.7 yrs. 24 (83.3%) patients were male while 09(16.7%) patients were female.

Few associated injuries seen were scapulae glenoid fracture (2 patients), proximal tibia fracture (1patient), mandible fracture (1patient), skull fracture (1patient), and superior and inferior pubic rami fracture (1patient). Fracture was more common on right side (23 patients- 69.7%) than left side (10 patients – 30.3%). In our study majority of patients were in B1 group (14 i.e. 42.4%) followed by A2 (08 i.e. 24.2%), B2(06 i.e. 18.2%), A1(5 i.e. 15.2%). (Table 1) In our study, none of the patients belonging to type 2A1 were operated.

In our study all 16 patients operated united with an average union time of 7.8 wks. One patient (6.25%) had delayed union by 12 wks which was secondary to implant failure and loss of reduction. (Figure 7) Only one patient (6.25%) had superficial skin infection which was treated with local wound debridement and daily dressing. It eventually got healed by 17th post- operative day. 16 out of 17 patients in conservative group united with 1 (5.8%) patient going into non-union.

Average union time in conservative group was 9.4 wks. Malunion was seen in 11 patients i.e. 64.7% of conserved patient out of which 6 (35.3%) patients had visible deformity and 3 (17.6%) patient had poor functional outcome with score less than 60. Union time is statistically highly significantly associated in two modalities of treatment. (p – 0.001, chi square – 11.2) (Table 2).

Overall, functional out-come was excellent in 12(36.4%), good in 11(33.3%), satisfactory in 4 (12.1%), adequate in 1(3%) and poor in 5 (15.2) in both conservative and operative group combined. (Table 3) In conservative group, 10 patients (58.8%) had good to excellent results compared to 13 patients (81.5%) in operative group who had good to excellent outcome. 4 patients (23.5%) had poor outcome in conservative group compared to only one patient (6.25%) in operative group.(Figure 1).

DISCUSSION: In our study mid-shaft clavicle fracture occurred more commonly in males with road traffic accident causing direct trauma to shoulder as a common cause compared to indirect trauma secondary to fall on outstretched hand. Fracture occurred more commonly on the right side.

ORIGINAL ARTICLE

Most of the patients belonged to type B1 variety (42.4%) followed closely by angulated A2 variety (24.2%). Associated other bones fracture were present in 6 patients (18.2%) and should be looked for carefully, including 2 patients (6.1%) patients who had ipsilateral scapulae fracture. Union time was better in operative group compared to conservative group which is statistically significant.

The functional outcome was better in operative group compared to conservative group especially if it is a displaced or comminuted fracture. Majority (7 out of 10) of patient who had good to excellent result in conservative group had un-displaced or stable fracture pattern. 4 out of 7 patients with type B fracture (57.1%) which were conserved had poor functional outcome at both 4 weeks as well as 12 week post trauma compared to only 1 out of 13 patients with type B fracture (7.6%) had poor outcome after open reduction.

Our study concludes that operative treatment i.e. Open reduction and internal fixation with plating gives better functional outcome and better shoulder movements in both short and long term period compared to conservative treatment and the same should be preferred especially for type B variety fracture. Plating provides a rigid fixation and does not require prolonged immobilization during post-operative period which was given for 4 weeks using sling support in our patients.

(Figure 8) Complications are rare following surgery and the only patient with implant failure was due to non-compliance to post-op rehabilitation protocol and lifting heavy load by the patient before fracture union. Open reduction and internal fixation with plating is especially justified for young athlete with displaced fracture demanding good functional outcome as end result and early return to sports activity.

Implant prominence is common problem following plating which was seen in 11 patients (68.7%) in our study however none of our patient gave consent for implant removal at 1 year follow-up. No local irritation due to implant was noted in our study.

REFERENCES

1. Lazarus MD. Fractures of the Clavicle. Chapter-26, In: Bucholz RW and Heckman JD, editors, Rockwood and Green's fractures in adults, 5th edition, Philadelphia: Lippincott Williams and Wilkins, 2001; 1041-1078.
2. Jupiter JB, Leffert RD. Non-Union of the clavicle - Associated complications and surgical management. *J Bone Joint Surgery (Am)*, 1987; 69: 753-760.
3. Hill JM, McGuire MH, Crosby LA. Closed treatment of displaced middle third fractures of the clavicle gives poor results. *J Bone Joint Surgery (Br)*, 1997; 79:537-540.
4. MT, Fontijne WP. Rush pin fixation for midshaft clavicular non-union: good results in 13/14 cases. *Acta Orthop Scand*. 1999; 70: 514-516.
5. Mudd CD, Quigley KJ, Gross LB. Excessive complications of open intramedullary nailing of midshaft Clavicle fractures with the Rockwood Clavicle Pin. *Clin Orthop Relat Res*. 2011 Dec; 469(12): 3364-70 Craig EV, Basamania CJ, Rockwood CA. Fractures of the clavicle. Chapter-11, In: Rockwood CA, Matsen FA, Wirth MA, Lippitt SB, editors, The shoulder. 3rd edition Philadelphia: Saunders, 2004; 455-519.
6. Frigg A, Rillmann P, Perren T, Gerber M, Ryf C. Intramedullary nailing of clavicular midshaft fractures with the titanium elastic nail: problems and complications. *Am J Sports Med*. 2009 Feb; 37(2):352-9. Epub 2008 Dec 31.

ORIGINAL ARTICLE

7. Poigenfurst J, Rappold G, Fischer W. Plating of fresh Clavicular fractures. *Injury*, 1992; 23 (4): 237-241.
8. Chen CH, Chen JC, Wang C, et al. Semi tubular plates for acutely displaced midclavicular fractures: a retrospective study of 111 patients followed for 2.5 to 6 years. *J Orthop Trauma*. 2008; 22:463-466.
9. Duan X, Zhong G, Cen S, Huang F, Xiang Z. Plating versus intramedullary pin or conservative treatment for midshaft fracture of clavicle: a meta-analysis of randomized controlled trials. *J Shoulder Elbow Surg*. 2011 Sep; 20 (6): 1008-15. Epub 2011 Apr 9.
10. Kulshrestha V, Roy T, Audige L. Operative versus non-operative management of displaced midshaft clavicle fractures: a prospective cohort study. *J Orthop Trauma*. 2011 Jan;25(1):31-8.
11. Kleweno CP, Jawa A, Wells JH, O'Brien TG, Higgins LD, Harris MB, Warner JJ. Midshaft clavicular fractures: comparison of intramedullary pin and plate fixation. *J Shoulder Elbow Surg*. 2011 Oct; 20(7):1114-7. Epub 2011 Jul 1.
12. Tarng YW, Yang SW, Fang YP, Hsu CJ. Surgical management of uncomplicated midshaft clavicle fractures: A comparison between titanium elastic nails and small reconstruction plates. *J Shoulder Elbow Surg*. 2011 Dec 9.
13. Fu TH, Tan BL, Liu HC, Wang JW. Anatomical reduction for treatment of displaced midshaft clavicular fractures: Knowles pinning vs. Reconstruction plating. *Orthopaedics*. 2012 Jan 16; 35(1):e23-30. doi: 10.3928 / 01477447-20111122-05.
14. Robinson's CM. Fractures of the clavicle in the adult - Epidemiology and classification. *J Bone Joint Surgery (Br)*, 1998; 80: 476-484.
15. Constant CR, Murley AHG. A clinical method of functional assessment of the shoulder. *Clinical Orthopaedics and Related Research*. 1987; 214: 160-164.

| Classification | Male | | Female | | Total | Percentage |
|----------------|-----------|------------|----------|------------|-----------|------------|
| | Count | Percentage | Count | Percentage | | |
| A1 | 5 | 15.2 | 0 | 0.0 | 5 | 15.2 |
| A2 | 5 | 15.2 | 3 | 9.1 | 8 | 24.2 |
| B1 | 10 | 30.3 | 4 | 12.1 | 14 | 42.4 |
| B2 | 4 | 12.1 | 2 | 6.1 | 6 | 18.2 |
| Total | 24 | | 9 | | 33 | |

Table 1: Percentage of patients in respective fracture pattern

| Method | < 8 weeks | | > 8 weeks | | Total | Percentage |
|------------------|-----------|------------|-----------|------------|-----------|------------|
| | Count | Percentage | Count | Percentage | | |
| Conservative | 6 | 20.0 | 10 | 33.3 | 16 | 53.3 |
| Operative | 15 | 50.0 | 1 | 3.3 | 16 | 53.3 |
| Total | 20 | | 10 | | 32 | |
| P Value: 0.001 | | | | | | |
| Chi Square: 11.2 | | | | | | |

Table 2: Union time in both conservative and operative group

ORIGINAL ARTICLE

| Functional Outcome | Conservative | | Operative | | Total | Percentage |
|--------------------|--------------|------------|-----------|------------|-----------|------------|
| | Count | Percentage | Count | Percentage | | |
| Excellent | 3 | 17.6 | 9 | 56.3 | 12 | 36.4 |
| Good | 7 | 41.2 | 4 | 25.0 | 11 | 33.3 |
| Satisfactory | 2 | 11.8 | 2 | 12.5 | 4 | 12.1 |
| Adequate | 1 | 5.9 | 0 | 0.0 | 1 | 3.0 |
| Poor | 4 | 23.5 | 1 | 6.3 | 5 | 15.2 |
| Total | 17 | | 16 | | 33 | |

Table 3: Functional outcome at 4 weeks

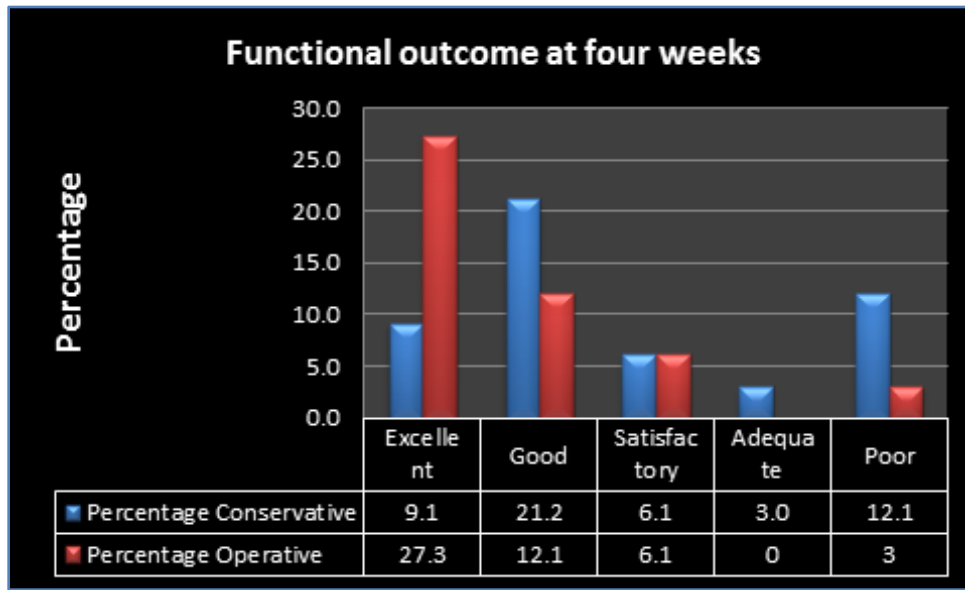


Figure 1: Bar diagram showing functional outcome in both groups

ORIGINAL ARTICLE

Figure 2: Robinson classification of clavicle fracture (Lazarus MD. Fractures of the Clavicle. Chapter-26 - Rockwood and Green's fractures in adults, 5th edition, Philadelphia: Lippincott Williams and Wilkins, 2001; 1041-1078).

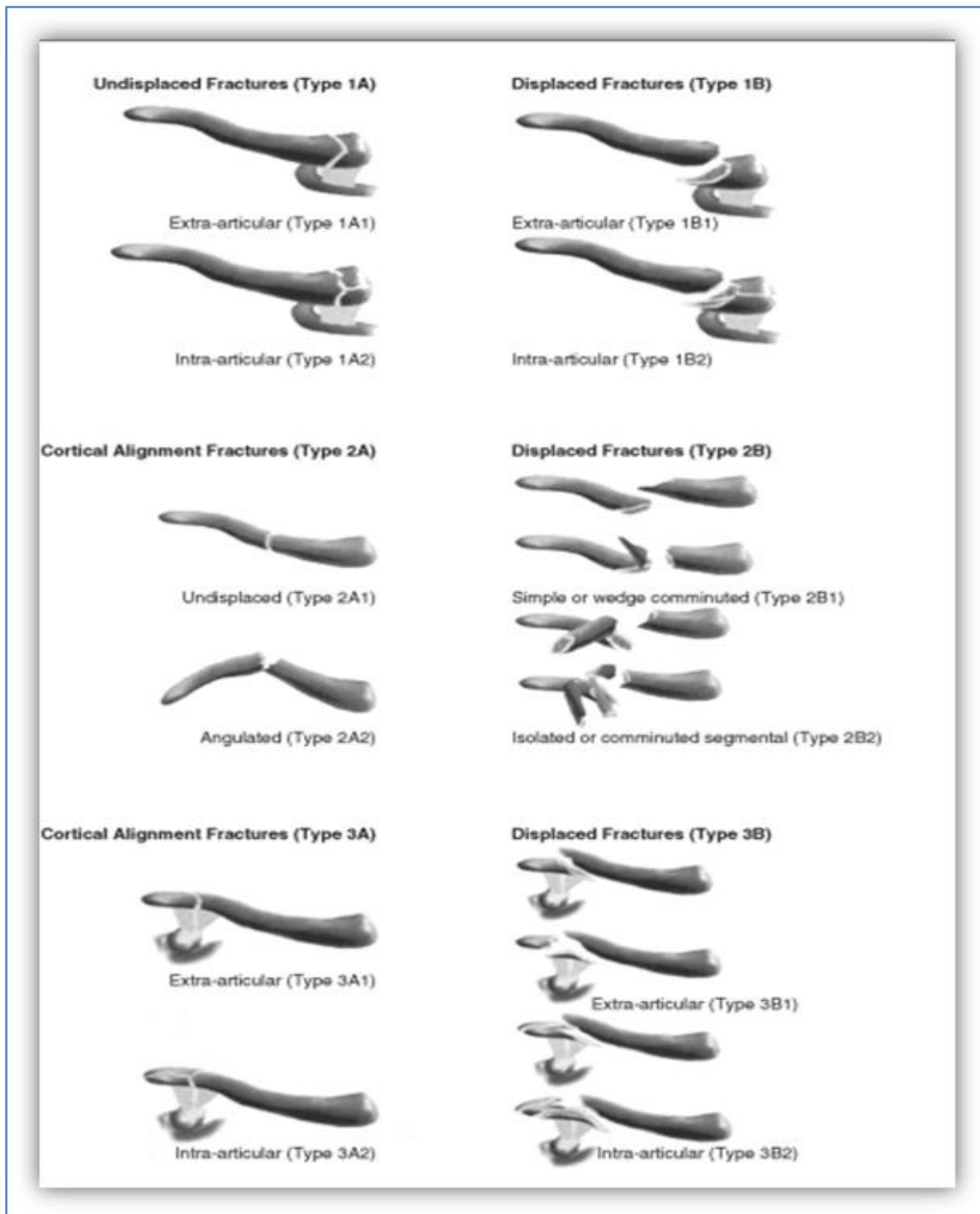


Figure 2

ORIGINAL ARTICLE

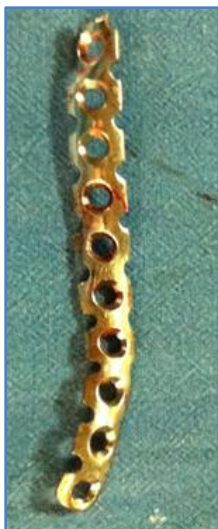

Fig. 3: Manually contoured recon plate



Fig. 4: Precontoured locking plate for clavicle

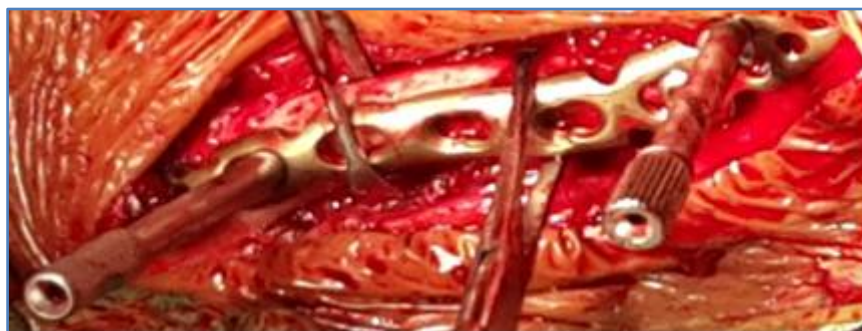


Fig. 5: Plate applied to the superior surface of clavicle

Fig. 6: Post op X-ray in a patient with type 2B1 fracture clavicle fixed with pre-contoured locking plate.

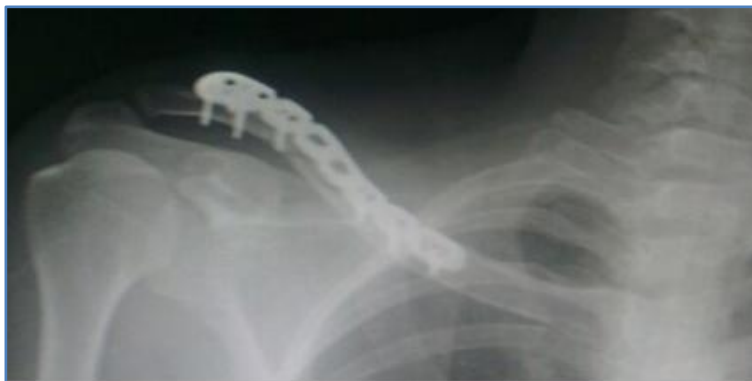

Figure 6

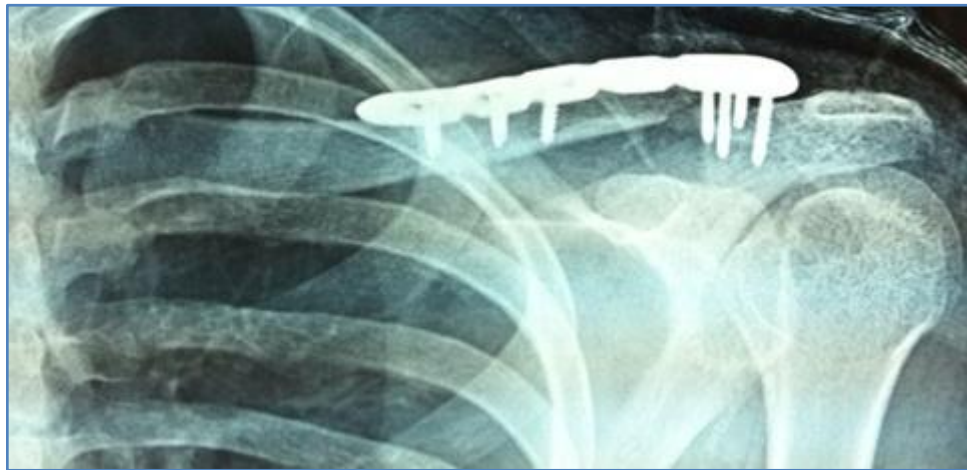

Fig. 7: One patient had implant failure which lead to poor outcome at 12 week follow-up

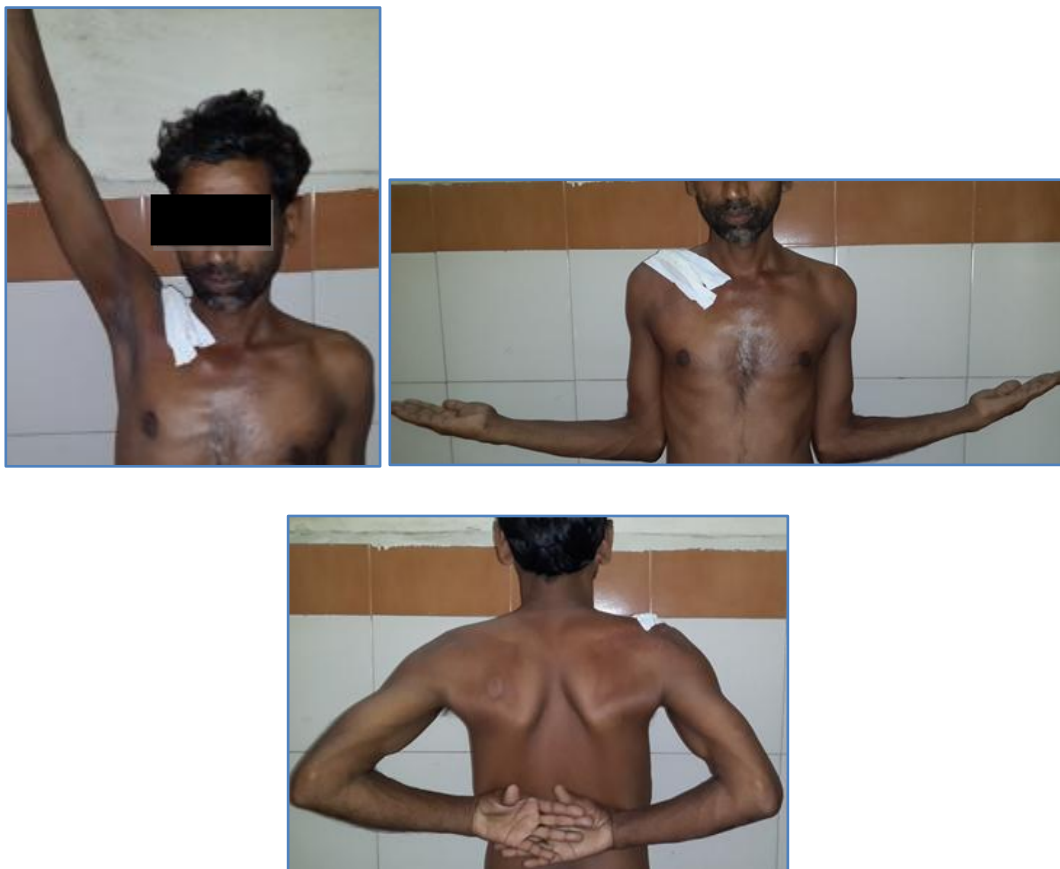

Fig. 8: One week post-op image showing full shoulder Range of Motion

AUTHORS:

1. Sunirmal Mukherjee
2. Mishil Parikh
3. Vinay Akka
4. Ashith A. Rao
5. Prakash D. Samant
6. AnkitVarshneya

PARTICULARS OF CONTRIBUTORS:

1. Registrar, Department of Orthopaedics, Padmashree Dr. D. Y. Patil Medical College and Research Centre, Nerul, Navi Mumbai.
2. Registrar, Department of Orthopaedics, Padmashree Dr. D. Y. Patil Medical College and Research Centre, Nerul, Navi Mumbai.
3. Resident Doctor, Department of Orthopaedics, PadmashreeDr. D. Y. Patil Medical College and Research Centre, Nerul, Navi Mumbai.
4. Professor, Department of Orthopaedics, PadmashreeDr. D. Y. Patil Medical College and Research Centre, Nerul, Navi Mumbai.

5. Professor, Department of Orthopaedics, PadmashreeDr. D. Y. Patil Medical College and Research Centre, Nerul, Navi Mumbai.
6. Senior Registrar, Department of Orthopaedics, PadmashreeDr. D. Y. Patil Medical College and Research Centre, Nerul, Navi Mumbai.

NAME ADDRESS EMAIL ID OF THE CORRESPONDING AUTHOR:

Dr. Sunirmal Mukherjee,
Flat No. 1801,
B-Wing Valencia,
Hiranandani Gardens,
Powai, Mumbai-400076.
Email: sunmukherjee1987@yahoo.com

Date of Submission: 18/07/2014.
Date of Peer Review: 19/07/2014.
Date of Acceptance: 30/07/2014.
Date of Publishing: 04/08/2014.