

SURGICAL MANAGEMENT OF COMPOUND DISTAL HUMERUS FRACTURE BY JESS EXTERNAL FIXATORUtkal Gupta¹, Sanjay Gupta², Gaurav Aggrawal³, Arjun Gandotra⁴, V. P. Pathania⁵**HOW TO CITE THIS ARTICLE:**

Utkal Gupta, Sanjay Gupta, Gaurav Aggrawal, Arjun Gandotra, V. P. Pathania. "Surgical Management of Compound Distal Humerus Fracture by Jess External Fixator". Journal of Evolution of Medical and Dental Sciences 2014; Vol. 3, Issue 19, May 12; Page: 5352-5366, DOI: 10.14260/jemds/2014/2597

ABSTRACT: BACKGROUND: Intraarticular displaced distal humerus fractures in adults always require open reduction and internal fixation with some plate and screw osteosynthesis after accurate reduction and alignment of fracture fragments. But high velocity trauma or gun-shot injuries often lead to a compound fracture with contamination and devitalization of soft tissue cover which requires some kind of external fixation. We thereby report the outcome of a series of ten patients who were treated definitively by extensive debridement and JESS type external fixation. This external fixator construct gave excellent fracture fragment stability and early mobilization of elbow joint. It provided patient friendly definitive fixation assembly resulting in early fracture consolidation with reasonably good range of elbow movement for such difficult fractures. **MATERIAL AND METHODS:** Ten cases of compound intercondylar distal humerus fracture between January 2007 to December 2011 were treated by early debridement & uniplanar bilateral JESS fixator application at the same sitting. This study includes cases of age group 18- 65 yrs. of which 3 were females & 7 were males. Mean age was 31.5yr. Only one case had injury to elbow with Gun-shot injury & rest were of high energy road traffic accidents. All patients reported within 40 hrs. average time to emergency department except 2 cases. A case of Gun-shot injury reported after 5 days & one case reported after 7day with pus discharge wound. According to A.O. Classification, 4 cases with C 3 type & 6 were C 2 type. All cases were operated within a mean of 8.7hrs of presenting to the emergency department. The average interval between injury & operation was 48.7 hrs. **RESULTS:** Complete painless supination pronation movement was achieved in six weeks At the end of six months of aggressive physiotherapy, the average extension was 9 degrees (range = 5 – 15 degrees) and average flexion was 106 degrees (range = 70 – 120 degrees). Clinical evaluation of elbow functions was done at sixth month using Mayo elbow score where 20% excellent, 60% good, 10% fair and 10% poor results were obtained. **CONCLUSION:** This is a relatively new technique of fixing compound intra-articular distal humerus fractures with JESS external fixator without spanning and immobilizing elbow joint has given good results, good patient compliance, least complications in our series of ten cases.

KEYWORDS: Humerus, Intercondylar, Compound, Intraarticular, Jess, External Fixator.

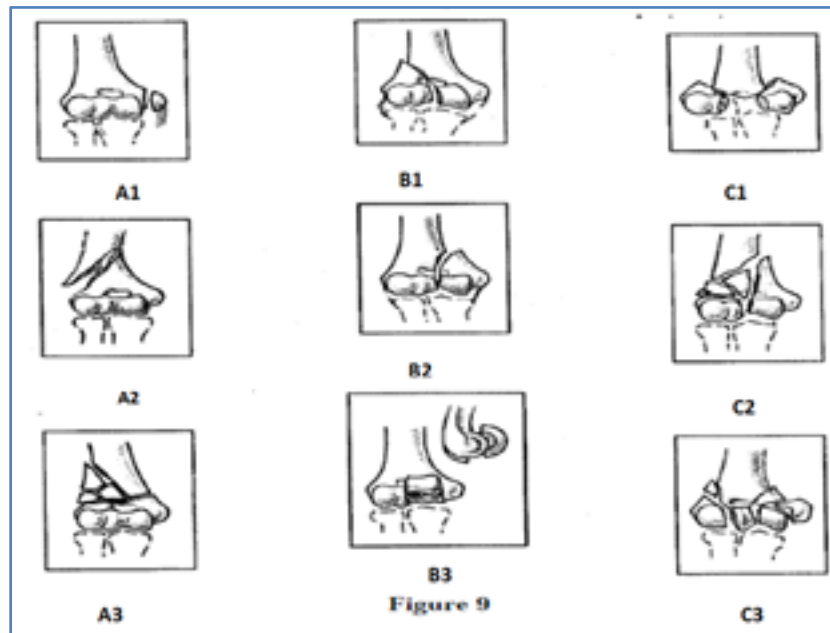
INTRODUCTION: There is an increase in incidence of high velocity injury to lower end of humerus. These cases with compound comminuted intercondylar fractures present a challenge to orthopedic surgeons.^{1,2} Controversies & challenges exist regarding management of compound comminuted intercondylar fracture distal end humerus. Dual locking anatomical or reconstruction plates have become a gold standard for open reduction & internal fixation^{3,4,5} of closed distal humerus fractures. But, severe contamination of bone fragments, bone loss, surrounding soft tissue devitalization & contamination prevents usage of reconstruction plates for these compound intra-articular fractures.

ORIGINAL ARTICLE

We treated a series of cases with compound, comminuted intercondylar distal humerus fractures with new technique of uniplanar bilateral JESS type of external fixator. This fixator was applied immediately after doing extensive debridement of the compound fracture. This frame design allows dressing of open wound, rigid anatomical fixation of fracture fragments & very early mobilization of elbow even when the open wound is still in process of healing.

CLASSIFICATION: Intercondylar fractures of the distal humerus are the most difficult fractures involving the humerus in adults. The overall incidence of this fracture in adults is small, and comprises less than 0.5% of all fractures. The overall review of the incidence and the distribution of the injury leads one to the observation that although this injury occurs infrequently, but when it does, the nature of injury is commonly severe and not uncommonly associated with injury to surrounding soft tissue and nerves.⁶

The A.O. classification: The A.O. classification of the fractures at this level is widely used and is the basis of the orthopedic trauma association (OTA) alpha numeric classification system.

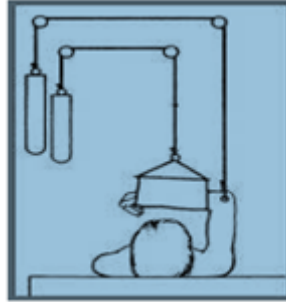


MODALITIES OF MANAGEMENT:

CLOSED TECHNIQUES:

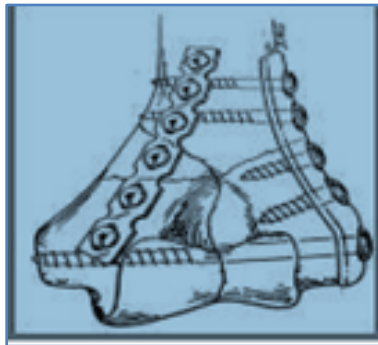
A) **Cast Immobilization:** This involves closed manipulation and immobilization in cast. This management represents the worst of both worlds, due to inadequate reduction and prolonged immobilization.^{7,8}

B) **Traction:** Most popular of the closed technique, used only in type intravenous injury. Commonest method is the overhead olecranon pin traction. This method is very cumbersome and requires prolonged stay in the hospital. Accurate reduction is not possible and reporting methods are inconsistent. Only very small series are documented supporting this method.



C) **Bag of Bones Technique:** promoted by Eastwood and Thomas, where the arm is placed in a cuff & collar sling with elbow in as much flexion as possible. Elbow is left hanging free and early mobilization of hand, shoulder and elbow is encouraged.

Open Reduction and Internal Fixation:



Open reduction and internal fixation with plating is well accepted as the standard treatment for these fractures. This allows for a painless elbow motion and maximizes the likelihood of full functional restoration of the brachium while the anatomically reduced and internally fixed distal humeral fracture fragments heal.⁹⁻¹⁴

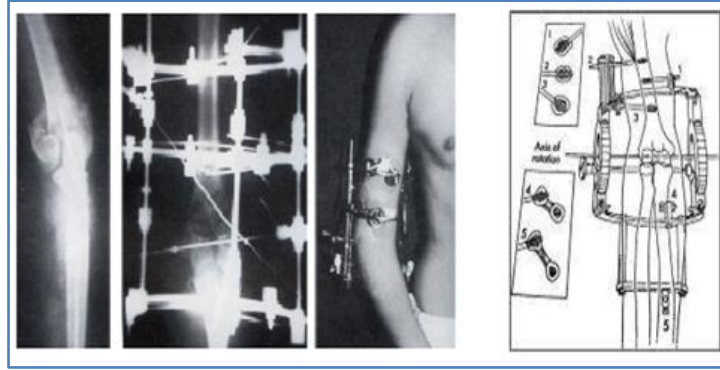
Surgery is best performed within the first 24 to 48 hours. If the wound is open, individual judgment must be exercised in management. All factors relating to the possibility of infection must be considered, such as type of wound, time of surgery, associated vascular injury and environment in which the wound occur.¹⁵⁻²⁰

If all factors are optimal, rigid internal fixation for these intraarticular fractures is advised when the wound is a Gustilo type I or type II. Secure fixation is a definite deterrent to infection in such wounds. However, extensive internal fixation should not be used for type III open wounds or injuries inflicted in excessively contaminated areas. Similarly, in cases where surgery is delayed for fear of increasing rather than reducing the chance of infection, it is recommended that the wound should be treated by irrigation and debridement before open reduction and internal fixation is carried out.^{21, 22}

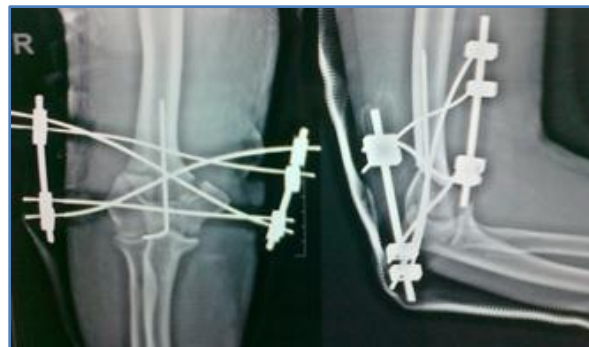External Fixator has been used for blast injuries involving fractures of lower end of humerus.²³⁻²⁷

Ring fixator and compass elbow hinge external fixator have been applied for badly comminuted fractures of distal humerus.²⁸⁻³¹

ORIGINAL ARTICLE



JOSHI'S EXTERNAL STABILISATION SYSTEM (JESS):




A simple, light, highly modular mini external fixator system which systematically addresses a wide range of complex problems in the management of forearm and hand. Invented by Dr. B. B. Joshi from Bombay. This system has high safety profile and unparalleled ease of application. It can be applied easily by any surgeon in even the most remote areas with minimum instrumentation.³²⁻³⁴ It provides a simpler alternative to the presently available modalities of treatment. It allows minimum invasive techniques.

JESS has following Components:

Link Joints: This is the basic clamping unit of jess system. It has cross holes at different levels. One oval hole and other round hole perpendicular to it. Three sizes, 2x2, 3x3, 4x4. The small size and design of the clamping unit allows inter digital application comfortable. It can hold wires of very small sizes.

Tightening of the grub screw clamps the rods and wires. The connecting rod is placed through the lower hole and the wire placed in the upper hole. The wire has pressure from both sides, hence has less chances of loosening.




ORIGINAL ARTICLE

Universal Link Joint: This consists of tightening screws on both ends of the joint. This link joint can hold all sizes of rods up to 4mm diameter. It has an advantage over the other joints as when part of assembly is removed, it does not affect the other components as it independently clamps both rods.



Connecting Rods: These are smooth steel rods of diameter varying from 2mm to 4mm. They are available in different length as per indication. The connecting rods can be bent to the required shape using simple instrumentation.



MATERIAL & METHODS: Ten cases of compound intercondylar distal humerus fracture between January 2007 to December 2011 were treated by early debridement & uniplanar bilateral JESS fixator application at the same sitting. Age group was between 18yrs – 65yrs of age, of which 3 were females & 7 males. Mean age was 31.5yrs. Only one case was of gun-shot injury to elbow & rest were of high energy road traffic accidents. All reported within 40 hrs. average time to emergency department except 2 cases. A case of gun-shot injury reported after 5 days & one case reported after 7 day with pus poring wound. According to A.O. classification, 4 cases were with C 3 type & 6 were C 2 type. All cases were operated within 8.7 hrs. of presenting to the emergency department. The average interval between injury & operation was 48.7 hrs.

OPERATIVE TECHNIQUE: Tourniquet was applied in all cases but inflated only if required. This helped in appropriate debridement & removal of devitalized, avascular tissue. In supine position an extensile lateral approach (Kocher's) to elbow joint & distal humerus was used for debridement & external fixator application. We preferred lateral approach, as, the usual posterior approach necessitates incising, cutting or splitting and then repairing the already intact extensor mechanism of elbow in presence of contamination and some duration of immobilization is required for its proper healing till an aggressive mobilization schedule could be followed.

This lateral approach was further preferred as the compound wound on all the cases was on anterolateral or posterolateral aspect which was included in the surgical incision on lateral aspect of elbow. A sterile sheet roll was kept below elbow to improve the exposure. After adequate soft tissue debridement, fractured bone edges were curetted. Contaminated very small fragments without soft tissue attachment were discarded. Pulsatile lavage with normal saline, povidone iodine, and H2O2

ORIGINAL ARTICLE

solution was done to sterilize the wound as possible. The bony fragments containing the articular surface were realigned and reduced achieving a good reconstruction of trochlea.

A thin K wire was introduced from lateral epicondylar area to medial epicondylar area, after holding the fragments with large reduction forceps & stabilization with K-wire, a 4.5mm or 5mm cannulated cancellous screw was used to secure the fragments rigidly. C-Arm assistance was used to confirm reduction. After this, remaining fragments were rearranged to reconstruct the medial & lateral column.

Palpation, direct visualization under C-Arm (image intensifier) are used to confirm accurate reduction. K-wires are used to temporarily stabilize the fragments checking the varus & valgus position of elbow. Two cross K-wires & two horizontal wires are used to stabilize the distal humerus fracture & uniplanar bilateral frame constructed to rigidly hold the anatomically aligned fragments. If the sterilization of wound is adequate, wound is closed over closed suction drain or the wound is left open for regular dressing for delayed secondary closure or skin grafting or flap coverage if required.

POST OPERATIVE TREATMENT: Arm sling pouch was used for support & no post-operative Plaster of Paris slab support was used. Gradual passive mobilization was started on 3rd day as pain & swelling subsided. Patient was discharged after 5 to 15 days depending on the condition of wound. At the time of discharge, patients were advised active assisted mobilization & maintenance of sling support in between. First few follow up visits were at weekly interval & then at 6th, 12th, 18th, 24th week when clinico-radiological evaluation was done. The final clinical evaluation was done at 6 months. The elbow & forearm movements were measured with standard goniometer. The results graded according to Mayo's elbow performance score.

CLINICAL EVALUATION: The functional results were assessed by the use of Mayo's elbow performance score which includes separate evaluations of pain, range of movement, stability of fracture site & functional outcome.

The overall score were then classified as follows:

FUNCTION	POINT SCORE
Pain	
None	45
Mild	30
Moderate	15
Severe	0
Motion	
arc 100°	20
arc 50° - 100°	15
arc < 50°	5
Stability	
Stable	10
moderately instable	5
Gross	0
Daily function	

ORIGINAL ARTICLE

combing hair	5
feeding oneself	5
Hygiene	5
putting on shirt	5
putting on shoes	5
Total	100
Mayo's Elbow score	

Score Greater Than 90°	Excellent
Score between 75 To 89°	Good
Score between 60 To 74°	Fair
Score below 60°	Poor

Sr. No.	Age/ sex	Mode of injury	Type of fracture	Range of movements at 6 months	Weeks required for complete radiological fracture union
1.	34yr/ M	RTA	C3 compound Gr III B	10° -70°	18 weeks
2	20yr/ M	RTA	C21 compound Gr II	10° - 120°	10 weeks
3	18yr/ F	Gun shot on elbow	C3 compound Gr III A	15° - 110°	12 weeks
4	60yr/ F	RTA	C2 compound Gr II	10°- 1 20°	12 weeks
5	35yr/ F	RTA	C2 compound Gr II	5° - 120°	12 weeks
6	22yr/ M	RTA	C2 compound Gr III A	10° - 120°	10 weeks
7	36yr/ M	RTA	C3 compound Gr III B	10° - 70°	16 weeks
8	30yr/ M	RTA	C3 compound Gr III A	10°- 100°	14 weeks
9	20yr/ M	RTA	C2 compound Gr II	5° - 120°	12 weeks
10	40yr/ M	RTA	C2 compound Gr III A	5° - 110°	12 weeks

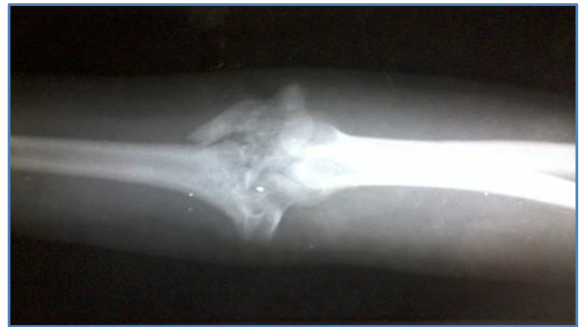OBSERVATIONS (on the basis of pain, range of movements & complete radiological union)

ORIGINAL ARTICLE

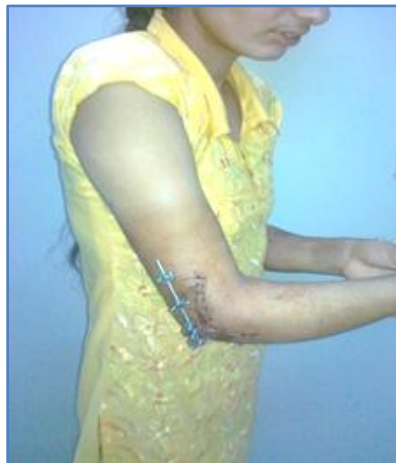Patient C



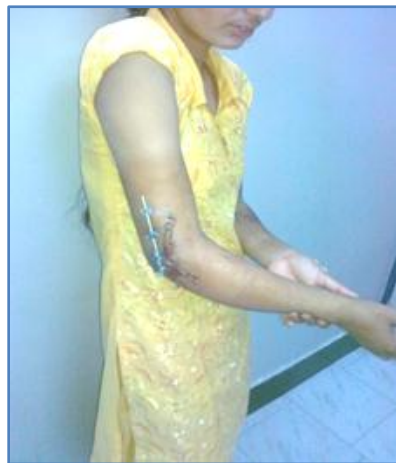X-ray of compound gun shot injury elbow



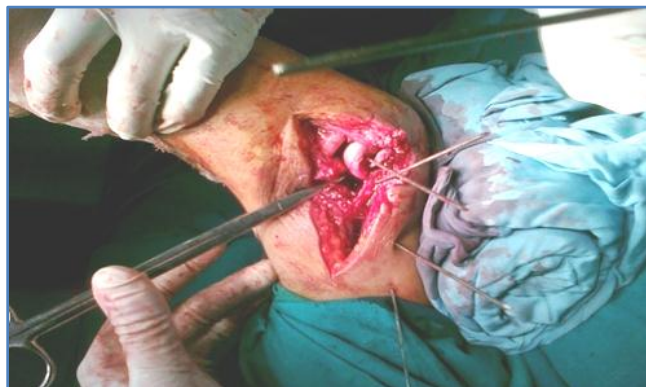Compound gun shot injury elbow



30° Extension on 3rd post OP

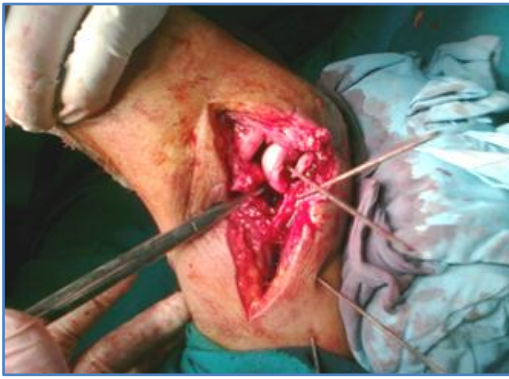


90° Flexion on 3rd post OP day

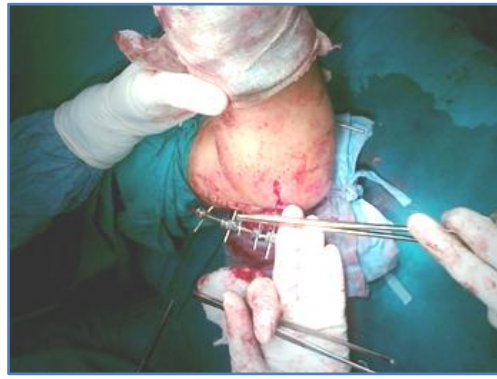

Articular alignment achieved with k wires in position

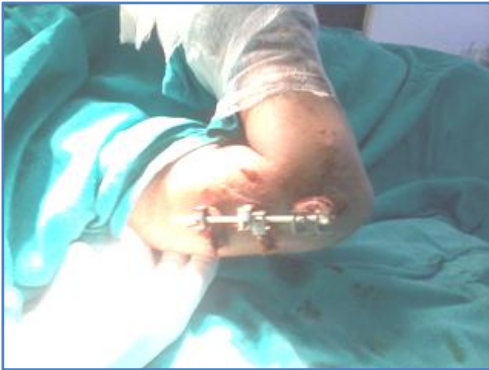ORIGINAL ARTICLE



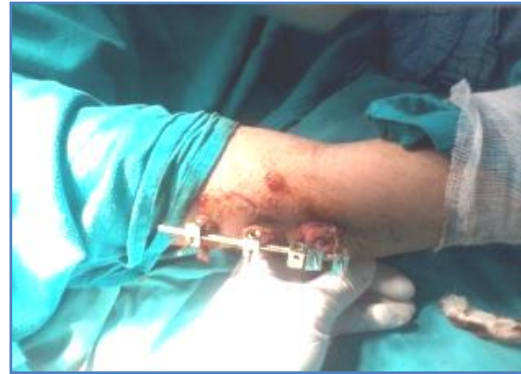k wires & exposed aligned fracture fragments on lateral aspect of elbow



Intra op photo after complete JESS fixator fixation

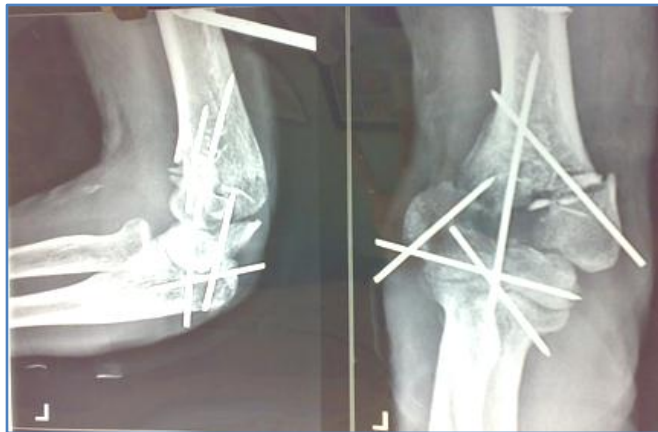

Manipulation of elbow at 6th week under anesthesia as the patient did not comply the physiotherapy mobilization schedule achieving 120° intra op flexion



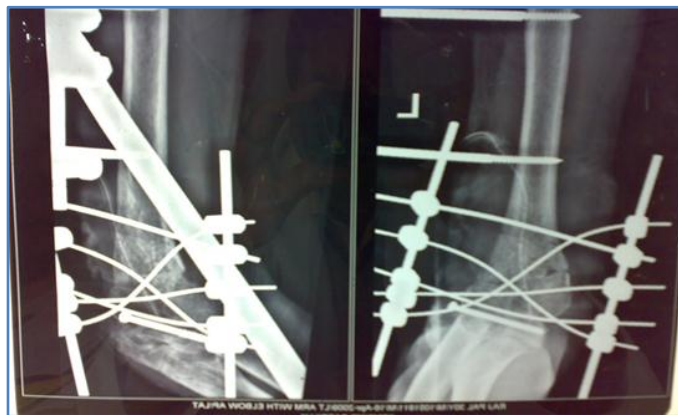Manipulation under anesthesia achieving complete extension

Patient D

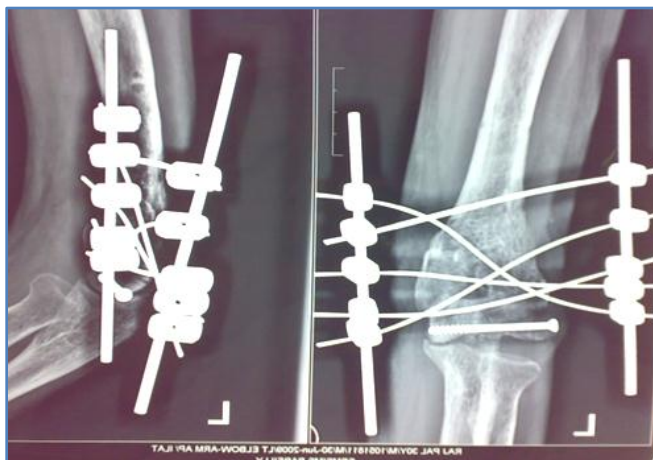

Immediate debridement and k wire stabilization as the viability of crushed forearm distal to the elbow fracture was controversial

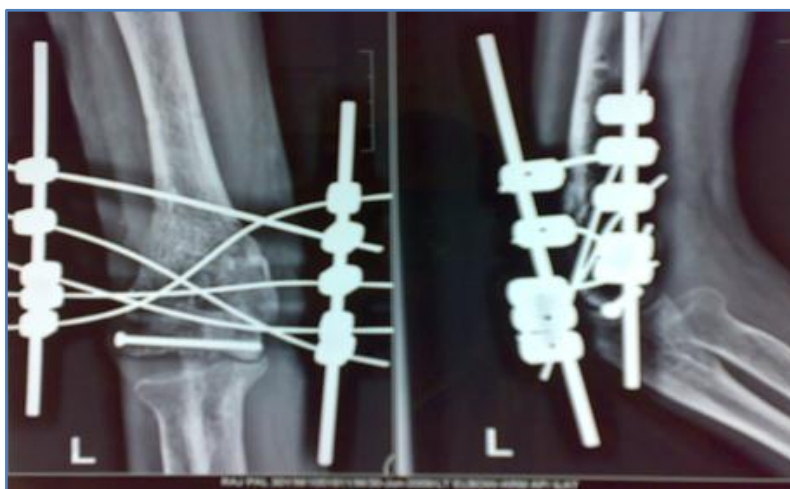ORIGINAL ARTICLE



6th week X-ray showing fracture in process of union along with an AO fixator stabilizing the dislocated elbow

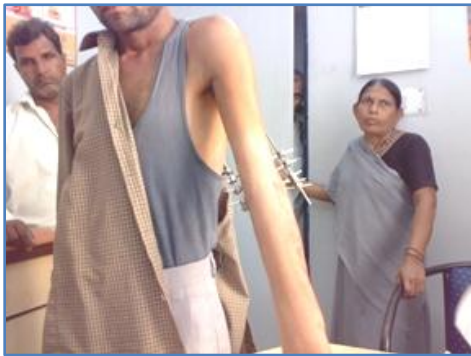

Fracture union with JESS fixator at 12th week

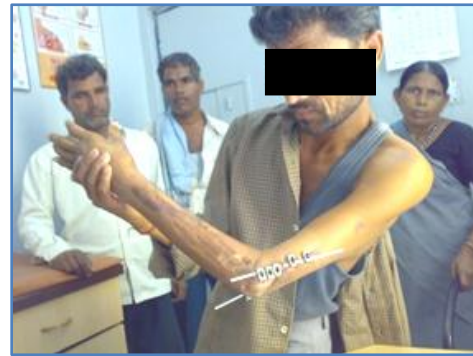

Complete consolidation of fracture at 18th week just before removal of fixator

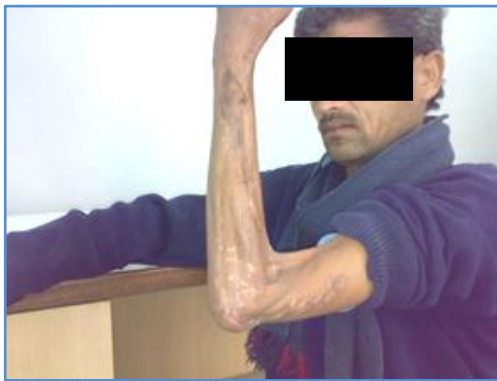ORIGINAL ARTICLE



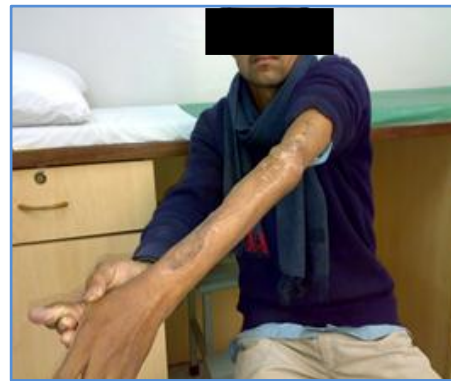0° or complete extension at 12th week



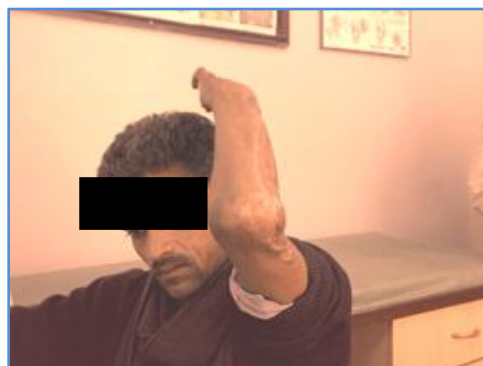80° flexion at 12th week



100° flexion at 16th week



Complete extension at 16th week



120° flexion at 24 week

ORIGINAL ARTICLE

SUMMARY: There were 10 patients, 7 male and 3 female with mean age 31.5 years who were treated by the above technique.

SL. No.	Age/ sex	Mode of injury	Injury and admission time interval	Injury and surgery time interval	Duration of hospital stay days	Type of fracture	Range of movements at 6 months	Weeks required for complete radiological fracture union	Observed mayo's elbow score at 6 months
1.	34yr/ M	RTA	7 days (192 hrs.)	7 day & 6 hrs. (198hrs)	15	C3 compound Gr III B	10°-70°	18 weeks	45 = poor
2	20yr/ M	RTA	3hrs	9hrs	5	C21 compound Gr II	10° - 120°	10 weeks	95 = excellent
3	18yr/ F	Gun shot on elbow	5days (120hrs)	5 days 10 hrs. (140hrs)	10	C3 compound Gr III A	15° - 110°	12 weeks	80 = good
4	60yr/ F	RTA	12 hrs.	18 hrs.	7	C2 compound Gr II	10° - 120°	12 weeks	85 = good
5	35yr/ F	RTA	18hrs	28hrs	5	C2 compound Gr II	5° - 120°	12 weeks	90 = excellent
6	22yr/ M	RTA	6hrs	12hrs	7	C2 compound Gr III A	10° - 120°	10 weeks	80 = good
7	36yr/ M	RTA	12hrs	20hrs	10	C3 compound Gr III A	10° - 70°	16 weeks	70 = fair
8	30yr/ m	RTA	12hrs	20hrs	7	C3 compound Gr III A	10° - 100°	14 weeks	75 = good
9	20yr/ M	RTA	12hrs	18hrs	5	C2 compound Gr II	5° - 120°	12 weeks	85 = good
10	40yr/ M	RTA	18hrs	24hrs	7	C2 III A compound	5° - 110°	12 weeks	85 = good

RESULT: The mean age of patients was 31.5 years. Average 12.8 weeks were required for complete radiological and clinical union of fracture. External fixator was removed at the completion of fracture union.

Aggressive active assisted physiotherapy was started after complete fracture union. The average range of movements achieved at six months after active aggressive physiotherapy at home which was supervised during the routine regular hospital visits was 97 degree range of elbow flexion and extension. Complete painless return of supination and pronation movement comparable to uninjured opposite elbow, was achieved in all patients in six weeks as pop slab immobilization was not used. There were three patients who reported at around one and half year after injury who had 5 to 140 degree range of painless movement. Clinical evaluation of elbow functions was done at sixth

ORIGINAL ARTICLE

month using Mayo elbow score where 20% excellent, 60% good, 10% fair and 10% poor results were obtained.

Pin tract infection, loss of soft tissue cover, and resultant delayed wound healing resulted in elbow stiffness in two cases where fair and poor results according to Mayo's elbow score were obtained.

DISCUSSION: Type C compound fractures of distal humerus are difficult to manage even after availability of many advanced anatomical fixation plates for distal humerus fracture. The management algorithm for these fractures is appropriate debridement with multiple K wires for temporary stabilization along with above elbow slab application till at least three weeks till the wound heals and the tissues become relatively free of infection. This immobilization period results in intraarticular and periarticular adhesions and resultant joint stiffness.

After this definitive plating with anatomical or reconstruction plates is done by posterior approach under cover of long term antibiotic therapy to prevent recurrence of infection. But the end results are never satisfactory in such cases for surgeon as well as patient in spite of two surgeries and increased monetary expenses and hospital stay.

But in our study we have achieved good results with one stage surgery with fewer expenses, less antibiotics, early post op mobilization from 3rd day onwards after surgery. After meticulous debridement good compression across fractured surfaces along with rigid fixation was achieved by cannulated cancellous lag screw for fixing inter-condylar articular fragments and the uniplanar bilateral JESS external fixator frame which span across the medial and lateral column fractures with its bent and pre-tensioned thick K wire construct compressing the fractures. Minimum metal implant in the injured area assured least chances of deep infection. Regular dressings and even secondary closure could be done without disturbing the fixator.

Checking the articular surface alignment and prevention of any K wire or bony fragment obstructing the olecranon fossa was important to achieve good intra-op and post op range of movements. There was no complaint of pin skin junction pain as is common in Illizarov fixator in thigh and leg. In only one case, patient had pin tract infection, which resolved with dressings and antibiotics.

CONCLUSION: This relatively new technique of fixing compound intraarticular distal humerus fractures with JESS external fixator without spanning and immobilizing the elbow joint has shown good results, good patient acceptance, least complications in our series of ten cases. We recommend this fixation technique with JESS construct to give good results in such difficult cases.

REFERENCES:

1. Pajarinen J, Bjo"rkenheim JM. Operative Treatment Of Type C Intercondylar Fractures of The Distal Humerus: Results after A Mean Follow- Up Of 2 Years In A Series Of 18 Patients. *J Shoulder Elbow Surg* 2002; 11: 48-52.
2. Sanders RA, Raney EM, Pipkin S. Operative Treatment of Bicondylar Intraarticular Fractures of the Distal Humerus. *Orthopedics* 1992; 15: 159-63.
3. Helfet DL, Schmeling GJ. Bicondylar Intra-Articular Fractures of the Distal Humerus. *Clin Orthop Relat Res* 1993; 292: 26-36.
4. Henley MB. Intra-Articular Distal Humeral Fractures in Adults. *Orthop Clin North Am* 1987; 18: 11-23.

ORIGINAL ARTICLE

5. Holdsworth BJ, Mossad MM. Fractures of the Adult Distal Humerus: Elbow Function after Internal Fixation. *J Bone Joint Surg Br* 1990; 72: 362-5.
6. Crenshaw AH. Fractures of Shoulder Girdle, Arm and Forearm. In: *Campbell's Operative Orthopedics*. 9th Ed. St. Louis: Mosby; 1998. P. 2809-13.
7. Kinik H, Atalar H, Mergen E. Management of Distal Humerus Fractures in Adults. *Arch Orthop Trauma Surg* 1999; 119: 467-9.
8. Schatzker J. Fractures of the Distal End of the Humerus. In: Schatzker J, Tile M, Editors. *The Rationale of Operative Fracture Care*. Berlin: Springer; 1987. P. 71-87.
9. Aitken GK, Rorabeck CK. Distal Humeral Fractures in the Adult. *Clin Orthop Relat Res* 1986; 191-7.
10. Allende CA, Allende BT, Allende BL, Bitar I, Gonzalez G. Intercondylar Distal Humerus Fractures—Surgical Treatment And Results. *Chir Main* 2004; 23: 85-95.
11. Bickel WA, Perry RE. Comminuted Fractures of The Distal Humerus. *Jama* 1963; 184: 553-7.
12. Cassebaum WH. Open Reduction of T & Y Fractures of the Lower End of the Humerus. *J Trauma* 1969; 9: 915-25.
13. Gabel G, Hanson G, Bennett JB, Noble PC, Tullos HS. Intraarticular Fractures of the Distal Humerus in the Adult. *Clin Orthop Relat Res* 1987: 99-108.
14. Jupiter JB, Neff U, Holzech P, Allgower M. Intercondylar Fractures of the Humerus: An Operative Approach. *J Bone Joint Surg Am* 1985; 67: 226-39.
15. Grant SD, Gorczyca JT, Pugh KJ. Open Distal Humeral Fractures. In: *Proceedings of the 1996 Annual Meeting of the Orthopaedic Trauma Association*; 1996 Sep 27–29; Boston, Mass. Rosemont (IL): Orthopaedic Trauma Association; 1996. P. 269.
16. Jupiter JB. Complex Fractures Of The Distal Part Of The Humerus And Associated Complications. *Instr Course Lect* 1995; 44: 187-98.
17. Ring D, Jupiter JB. Complex Fractures Of Distal Humerus And Their Complications. *J Shoulder Elbow Surg* 1999; 8: 85-97.
18. Abzug JM, Dantuluri PK. Use Of Orthogonal Or Parallel Plating Techniques To Treat Distal Humerus Fractures. *Hand Clin*. 2010 Aug; 26(3):411-21, vii. doi: 10.1016/j.hcl.2010.05.008.
19. Markus Windolf, Edgardo Ramos Maza, Boyko Gueorguiev, Volker Braunsten, Karsten Schwieger. Treatment Of Distal Humeral Fractures Using Conventional Implants. Biomechanical Evaluation Of A New Implant Configuration. *BMC Musculoskeletal Disorders* 2010, 11:172.
20. Sanchez-Sotelo J, Torchia ME, O'Driscoll SW. Complex Distal Humeral Fractures: Internal Fixation with A Principle-Based Parallel-Plate Technique. *J Bone Joint Surg Am*. 2007 May; 89(5): 961-9.
21. Rajasekaran S. Early Versus Delayed Closure of Open Fractures. *Injury* 2007; 38: 890-5.30.
22. Weitz-Marshall AD, BosseMJ. Timing of Closure of Open Fractures. *J Am Acad Orthop Surg* 2002;10: 379-84.
23. Ring D, Jupiter JB, Toh S. Salvage of Contaminated Fractures of The Distal Humerus With Thin Wire External Fixation. *Clin Orthop Relat Res* 1999: 203-8.
24. Stavlas P, Gliatis J, Polyzois V, Polyzois D. Unilateral Hinged External Fixator of The Elbow In Complex Elbow Injuries. *Injury*. 2004 Nov; 35(11): 1158-66.

ORIGINAL ARTICLE

25. Hall Jeremy, Schemitsch Emil H, Mckee Michael D. Use Of A Hinged External Fixator For Elbow Instability After Severe Distal Humeral Fracture Journal Of Orthopaedic Trauma: August 2000 - Volume 14 - Issue 6 - Pp 442-445.
26. Skaggs David L, Hale Julia M, Buggay Shane, Kay Robert M. Use Of A Hybrid External Fixator For A Severely Comminuted Juxta-Articular Fracture Of The Distal Humerus. Journal Of Orthopaedic Trauma: August 1998 - Volume 12 - Issue 6 - Pp 439-442.
27. Ring David, Jupiter Jesse B, Toh Satoshi. Salvage Of Contaminated Fractures Of The Distal Humerus With Thin Wire External Fixation, Clinical Orthopaedics & Related Research: February 1999 - Volume 359 - Issue - Pp 203-208.
28. Skaggs DL, Hale JM, Buggay S, Kay RM. Use Of A Hybrid External Fixator For A Severely Comminuted Juxtaarticular Fracture Of The Distal Humerus. J Orthop Trauma 1998; 12: 439-42.
29. Stavlas P, Gliatis J, Polyzois V, Polyzois D. Unilateral Hinged External Fixator Of The Elbow In Complex Elbow Injuries. Injury 2004; 35: 1158-66.
30. Yian Edward, Karunakar Mahadav. Distal Humerus Fractures. Emedicine Orthopaedic Surgery/1239515- Overview.
31. Chaudhary S, Patil N, Bagaria Et Al. Open Intercondylar Fractures of The Distal Humerus: Management Using A Mini External Fixator Construct. J Of Shoulder & Elbow Surgery, 465- 470, May/ June 2008.
32. Gulati S, Joshi BB, Milner SM. Use Of Joshi External Stabilizing System In Postburn Contractures Of The Hand And Wrist: A 20-Year Experience. J Burn Care Rehabil 2004; 25: 416-20.
33. Joshi BB. Percutaneous Internal Fixation Of Fractures Of The Proximal Phalanges. Hand 1976; 8: 86-92.
34. Patel MR, Joshi BB. Distraction Method for Chronic Dorsal Fracture Dislocation Of The Proximal Interphalangeal Joint. Hand Clin 1994; 10: 327-37.

AUTHORS:

1. Utkal Gupta
2. Sanjay Gupta
3. Gaurav Aggrawal
4. Arjun Gandotra
5. V. P. Pathania

PARTICULARS OF CONTRIBUTORS:

1. Associate Professor, Department of Orthopaedics, SRMS Institute of Medical Sciences, Bareilly, U.P.
2. Associate Professor, Department of Orthopaedics, SRMS Institute of Medical Sciences, Bareilly, U.P.
3. Senior Resident, Department of Orthopaedics, SRMS Institute of Medical Sciences, Bareilly, U.P.

4. Junior Resident, Department of Orthopaedics, SRMS Institute of Medical Sciences, Bareilly, U.P.
5. Professor, Department of Orthopaedics, SRMS Institute of Medical Sciences, Bareilly, U.P.

NAME ADDRESS EMAIL ID OF THE CORRESPONDING AUTHOR:

Dr. Utkal Gupta,
 OPD 6, Department of Orthopedics,
 SRMSIMS, Nainital Road,
 Bhojipura, Bareilly, U. P.
 Email: utkal_gupta2003@yahoo.co.in

Date of Submission: 26/03/2014.
 Date of Peer Review: 27/03/2014.
 Date of Acceptance: 01/05/2014.
 Date of Publishing: 12/05/2014.