

## CASE REPORT

### AN UNUSUAL CASE OF SOLITARY FIBULAR METASTASIS AS THE FIRST SIGN OF GASTRIC CARCINOMA

Vivek Patre<sup>1</sup>, Brijesh Arora<sup>2</sup>, Anup Kumar Das<sup>3</sup>, Sanjay Thulkar<sup>4</sup>, Meghnath Pawar<sup>5</sup>

#### HOW TO CITE THIS ARTICLE:

Vivek Patre, Brijesh Arora, Anup Kumar Das, Sanjay Thulkar, Meghnath Pawar. "An Unusual case of Solitary Fibular Metastasis as the First Sign of Gastric Carcinoma". Journal of Evolution of Medical and Dental Sciences 2014; Vol. 3, Issue 09, March 03; Page: 2251-2254, DOI: 10.14260/jemds/2014/2134

**ABSTRACT:** Symptomatic solitary bony metastasis in distal appendicular skeleton as the first sign of asymptomatic malignant gastric tumor is extremely uncommon. We report an unusual case of fibular metastases from gastric carcinoma. In this case, bony metastasis was the initial manifestation of gastric carcinoma.

**KEYWORDS:** Gastric adenocarcinoma, Magnetic resonance imaging, Skeletal metastases.

**INTRODUCTION:** Carcinoma of the stomach is an extremely common malignant neoplasm. It disseminates mostly by lymphatics. The hematogenous spread to the distant organs occurs, though at a very late stage. The liver is most commonly affected in 30% cases via the portal radicles followed by lung in 10% cases in autopsy series. No tissue or organ is exempt from the blood-borne metastasis of this carcinoma. Rare distant sites of metastasis include brain, bones, kidney, adrenal and spinal cord<sup>1,2</sup>. Osseous metastases from primary gastric carcinoma are uncommon and it is seen in 0-3% cases in clinical series while up to 17.5% incidence has been reported in autopsy series<sup>2,3</sup>. The involvement of distal appendicular skeleton at presentation is very rare. We report a case of gastric carcinoma with fibular metastases as presenting symptoms.

**CASE REPORT:** A 68 years old man was presented with pain and swelling in upper part of right leg which is gradually increasing in size since 3 months. The plain radiography of right knee revealed a slightly expansile osteolytic lesion at the proximal end of fibula with cortical destruction (Fig.1). Investigations in hospital including x-ray chest, Ultrasonography abdomen, Computed Tomography (CT) chest performed was unremarkable. Bone scan showed intense tracer activity isolated to upper end of fibula, but failed to reveal the primary site. The magnetic resonance imaging (MRI) of right knee showed destruction of proximal end of fibula with diffuse infiltrative abnormal signal in the adjacent muscles, which was intermediate on T1-weighted image (Fig. 2a) and high on T2-weighted image (Fig. 2b). After injection of gadolinium diethylenetriaminepenta-acetic acid (Gd-DTPA) strong enhancement of soft tissue lesion seen. An excisional biopsy of lesion shows islands of metastatic tumor showing glandular differentiation. The stroma is desmoplastic with focal osteoclastic type of giant cell. Immunohistochemical stain for cytokeratin and epithelial membrane antigen were positive in the tumor cells (Fig. 3). The final pathological diagnosis was interpreted as metastatic adenocarcinoma. In search for primary site gastrointestinal series were considered and he underwent-oesophagogastroduodenoscopy which revealed small irregular ulcer in lesser curvature of stomach, biopsy of that showed adenocarcinoma of stomach.

**DISCUSSION:** Metastatic carcinoma is the most common malignancy involving the musculoskeletal system. In a patient with bone pain which is unexplained or out of proportion to traumatic event,

## CASE REPORT

---

neoplastic disease must be considered. In a patient with metastatic adenocarcinoma with unknown primary 5-20% may present as skeletal metastases as the first lesion [4]. In skeletal metastases of known organ, most common primary site is breast or prostate, while in cases with skeletal metastases of unknown origin, the primary site is lung, pancreas, liver and kidney 4.

Due to rarity of skeletal metastases, stomach carcinoma is classified in group of ossophobe tumors. The development of bony metastases is believed to occur as a discontinuous hematogenous process. In abdominal cancer, the liver series as first filter to tumor emboli to the second filter lung. It is also possible that hepatic filter may be bypassed via the thoracic duct. Once the pulmonary bed is seeded, there is high likelihood of secondary to bones etc. via the systemic circulation 2. Bony metastases from stomach cancer relates closely to signet ring or poorly differentiated carcinoma and has a high tendency to occur in those with lymph node involvement. Usually it is also associated with invasive cancer such as third or fourth boormann type. Skeletal secondary from carcinoma of stomach are usually osteolytic type and less commonly lytic sclerotic type 3,5.

Osseous metastases are rarely seen at presentation in gastric carcinoma for distant metastasis as the first sign of this neoplasm an incidence of 5.4% was reported in one series of 1100 patients, but none, however presented with bony metastases 2. As is clear solitary osseous metastases at presentation is even rarer. It can easily be mistaken for a primary tumor of the bone. Bony metastasis, in general, present in axial or proximal appendicular skeleton in patients who are more than 40 years of age while primary bone tumors usually occur in the appendicular skeleton in patients younger than 40 years 4.

Distal appendicular bony metastases are distinctly rare 6 and are usually part of a disseminated disease. Jaffe in his discussion of osseous metastasis has started "It is only exceptionally located in a bone distal to the knee joint and hardly over in a bone distant to the elbow joint" 7. The rarity of bony metastasis in the peripheral bones inspite of high frequency of bony involvement in carcinomas may be related to the unusual mechanism of hematogenous spread. Primary malignancies order the keen and malignant emboli get depended in liver and lung, simultaneously the communication with the vertebral venous plexus permits the deposition of emboli to the axial skeleton but the more peripheral bones don't share in this sluggish reversible system of venous anastomosis 8,9. In spite of this rarity metastatic lesions should be included in the differential diagnosis of lytic lesions of the bones of distal appendicular skeleton.

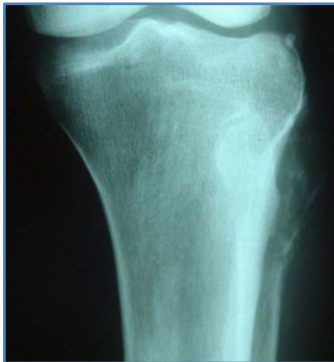The survival rate for patients with metastatic adenocarcinoma is very poor. The treatment is primarily palliative and the aim of treatment is to relieve pain, to prevent development of pathological fracture, to improve mobility and if possible to prolong survival. The important factors which must be considered while treating distal bony metastasis include whether the lesion is solitary or part of disseminated disease and the general condition of patient and expected survival. If the metastasis is part of disseminated disease only symptomatic treatment e.g. palliative radiotherapy is enough. If no other lesions are present after thorough investigation then radical treatment e.g. amputation may be done.

In summary, this case as well as review of literature suggests that bony metastases of distal appendicular skeleton are rare in gastric carcinoma. These can be an initial presentation of an occult gastric carcinoma.

## CASE REPORT

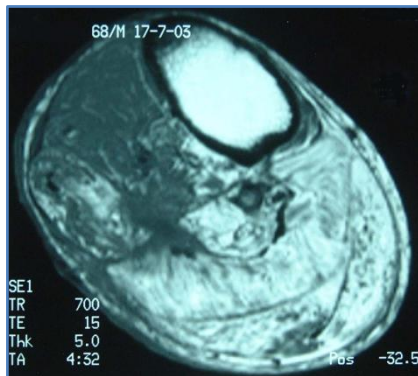
### REFERENCES:

1. Remine WH, Priestley JT, Berson J. Cancer of the stomach. Saunder S, Philadelphia 1964; pp 145.
2. Birla RK, Bowden L. Solitary bony metastasis as the first sign of malignant gastric tumor or of its recurrence. *Ann Surg*, 1975; 182: 45-49.
3. Yoshikawa K, Kitaoka H. Bony metastasis of gastric cancer. *Jpn J Surg*, 1983; 13: 173-176.
4. Simon MA, Karluk MB. Skeletal metastasis of unknown origin: diagnostic strategy for orthopaedic surgeons. *Clin Orthop*, 1982; 166: 96-103.
5. Nioshidsi H, Koga S. Clinicopathological study of gastric cancer with bony metastasis. *Gan To Kagaku Ryoho*, 1987; 14: 1717-1722.
6. Rangrajan V, Dau S, Purandare N, Shah S. Unusual lower limb skeletal metastases from carcinoma of the cervix: Detection by F-18 FDG PET / CT. *Clinical Nuclear Medicine*, 2010; 35: 534-536.
7. Jaffe HL. Tumors and tumorous conditions of bones and joints, Leaand Febiger. Philadelphia pp, 1958; 589-604.
8. Batson OV. Function of vertebral veins and their role in spread of metastasis. *Ann Surg*, 1940; 112: 138-149.
9. Hulvey RB. Peripheral bone metastasis. *Am J Roentgenol Rad Ther*, 1964; 91: 155-160.



**Figure 1**

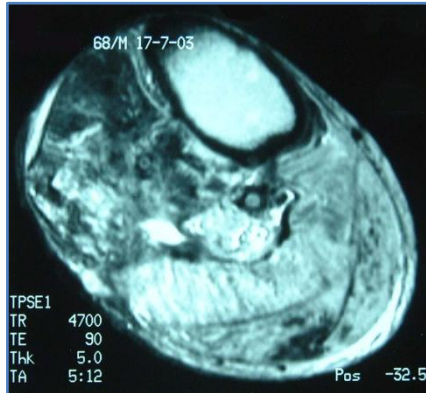
Plain X ray right knee AP view showing a slightly expansile lesion with cortical destruction at the proximal end of fibula.



**Figure 2a:**

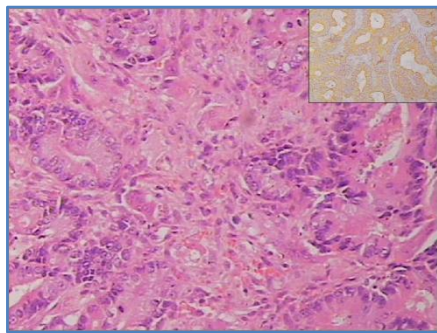
Axial MR image of right knee showing destruction of proximal end of fibula with diffuse infiltrative abnormal signal in the adjacent muscles, which was intermediate on T1 - weighted image (Fig. 2a) and High on T2 - Weighted image (Fig. 2b).

## CASE REPORT



**Figure 2b**

Weighted Image



**Figure 3**

Microscopic section examined from the excised specimen showed well-formed glands in a desmoplastic stroma with scattered osteoclastic giant cells (mark with arrow). There was strong immunoreactivity for cytokeratin (inset).

### AUTHORS:

1. Vivek Patre
2. Brijesh Arora
3. Anup Kumar Das
4. Sanjay Thulkar
5. Meghnath Pawar

### PARTICULARS OF CONTRIBUTORS:

1. Senior Resident, Department of Radiodiagnosis, All India Institute of Medical Sciences, New Delhi, India.
2. Senior Resident, Department of Medical Oncology, All India Institute of Medical Sciences, New Delhi, India.
3. Senior Resident, Department of Pathology, All India Institute of Medical Sciences, New Delhi, India.

4. Additional Professor, Department of Radiodiagnosis, All India Institute of Medical Sciences, New Delhi, India.
5. Senior Resident, Department of Orthopaedics, All India Institute of Medical Sciences, New Delhi, India.

### NAME ADDRESS EMAIL ID OF THE CORRESPONDING AUTHOR:

Dr. Vivek Patre,  
Assistant Professor,  
Department of Radiodiagnosis,  
Pt. J. N. M Medical College, Jail Road,  
Raipur, Chhattisgarh, India.  
E-mail: vivek\_patre@yahoo.com

Date of Submission: 26/12/2013.  
Date of Peer Review: 27/12/2013.  
Date of Acceptance: 16/01/2014.  
Date of Publishing: 27/02/2014.