

A STUDY ON DE QUERVAIN'S STENOSING TENOSYNOVITIS ANALYZING THE RESULTS OF DIFFERENT CONSERVATIVE TREATMENT MODALITIESSreejith T. G¹, Althaaf Mohamed A. H²**HOW TO CITE THIS ARTICLE:**

Sreejith T. G, Althaaf Mohamed A. H. "A Study on De Quervain's Stenosing Tenosynovitis Analyzing the Results of Different Conservative Treatment Modalities". Journal of Evolution of Medical and Dental Sciences 2015; Vol. 4, Issue 78, September 28; Page: 13649-13653, DOI: 10.14260/jemds/2015/1951

ABSTRACT: OBJECTIVE: The purpose of this study is to find out, which should be the initial treatment of choice in a case of DQTS that can provide the best symptomatic relief. Comparison was between conservative treatment as against steroid injection. **MATERIALS AND METHODS:** A prospective randomized study was conducted on patients with dequervain's disease, in order to compare the outcome of conservative treatment as against steroid injection. Study was conducted on a total of 46 patients who were selected from KMCT Medical College during January 2015 to June 2015. Out of this 40 were female and only 6 were male patients **RESULTS:** Study reveals 82.61% excellent results in group treated with steroid injection as compared to 17.39% in conservatively treated patients. A good result of 17.39% was noted in steroid treated cases while conservative patients showed 13.04%. Conservatively treated patients had a very poor out come in 69.57% patients **CONCLUSION:** Patients who were treated with steroids had better prognosis compared to those underwent conservative management

KEYWORDS: DQTS, steroid injection, conservative treatment.

INTRODUCTION: The gold standard treatment of de Quervain's Stenosing Tenosynovitis (dqts) is surgery. But many a times there happens a delay for surgery, due to various reasons like relief with analgesics, lifestyle modifications and personal inconveniences. The purpose of this study is to find out, which is the best conservative measure suited for this patient during this period. Dequervain's disease is a repetitive stress syndrome predominantly affecting the abductor pollicis longus (APL) and the extensor pollicis brevis (EPB) tendons, as it passes through the first dorsal compartment of the wrist.^[1,2,3,4] It is also known as radial styloiditis. Patients complained of pain and inflammation over the the radial styloid region which is exacerbated by movement and activity requiring ulnar deviation with a clenched fist and flexion of thumb at metacarpophalangeal joint.^[5,6] Wringing of cloth, gripping a golf club, lifting a child, or hammering a nail etc are some specific activities that are observed to increase the inflammation.^[6] Physical examination showed swelling and tenderness in the region of the first dorsal compartment. Finklestein's test turned positive for all selected patients giving a painful response over the styloid process of the radius.^[1,2,5] This was mainly due to a restricted gliding of the APL and EPB tendons in the narrow compartment caused by thickening of the extensor retinaculum and compressing the APL and EPB tendons.^[1,2,5] Management differs based on the severity of the condition, which include anti-inflammatory medication, corticosteroid injections, and occupational therapy, and If symptoms persist despite a trial of conservative care, surgical intervention may be warranted. Surgical correction is done by releasing the pressure of first dorsal compartment, including any sub-compartments, followed by immobilization and occupational therapy.

ORIGINAL ARTICLE

MATERIALS AND METHODS: A prospective randomized study was conducted on patients with dequervain's disease, to compare the outcome of conservative treatment as against steroid injection. All the patients were confirmed as a case of DQTS after proper clinical examination and detailed history. Every alternate case of DQTS was given conservative management and steroid injection. A total of 46 patients participated in the study, out of which 40 were female and only 6 were male patients.

INCLUSION AND EXCLUSION CRITERIA: All clinically diagnosed new patients were included. Patients with recurrence, with diabetes and cardiac manifestations, with peripheral vascular disease and patients with trauma of same hand were all excluded from the study. Complications of steroid injections like secondary rupture and fibrosis were not included in the study as the duration was short term.

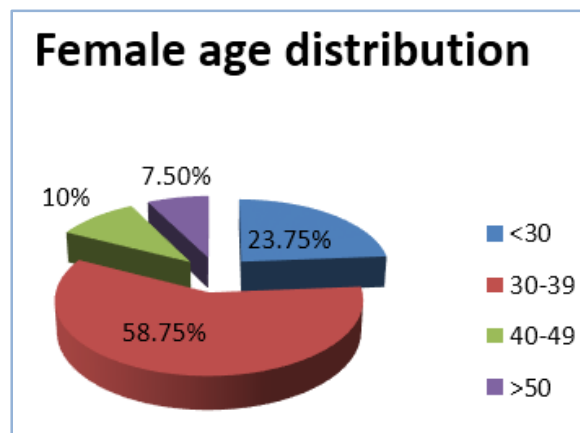
CONSERVATIVE GROUP: Every alternate set of patients were given conservative treatment using, splints, NSAID's, rest, occupational therapy, physiotherapy etc.

STERIOD INJECTION GROUP: Under aseptic conditions the other set of patients were given injection of a steroid like triamcinolone or hydrocortisone mixed with 2% xylocaine into the sheath of the affected tendons.

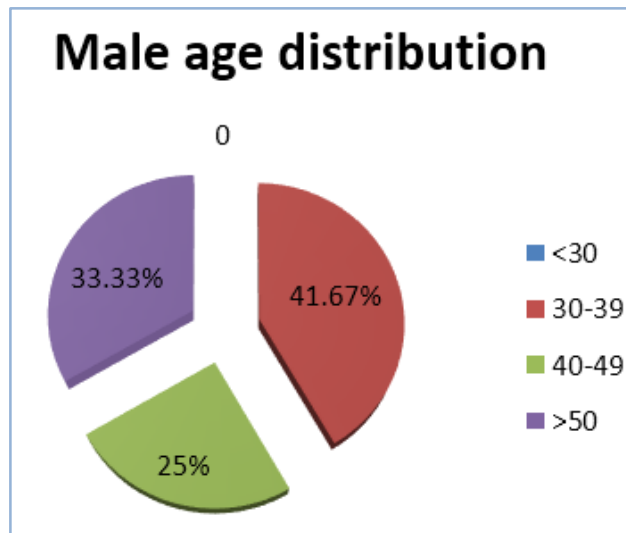
Follow-up of all the patients were done at the end of one week and two weeks from the initiation of treatment.

RESULT: A total of 92 patients participated in the study, out of which 80 were female and only 12 were male patients. It was noted that more patients were from the age group 30-40 years. Most of the people are right handed and tend to use their right hand more than the left, and we feel that's the reason for more number of right side DQTS. Result evaluation was based on the clinical examination findings at the end of one week and after two weeks.

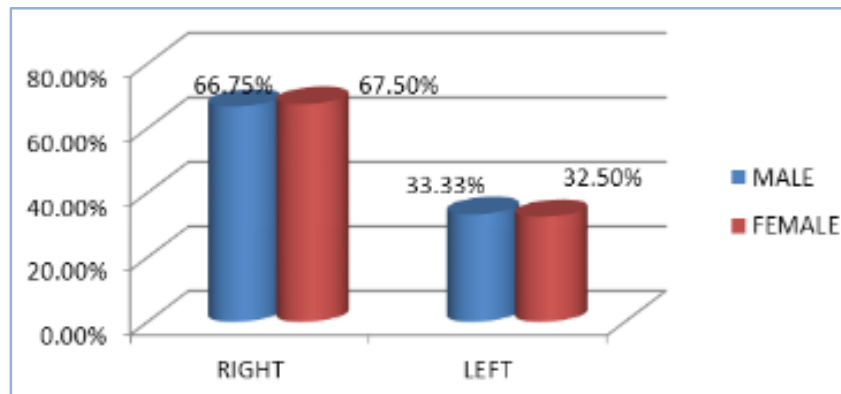
Age	Male	Female
<30	0	19(23.75%)
30-39	5(41.67%)	47(58.75%)
40-49	3(25%)	8(10%)
>50	4(33.33)	6(7.5%)



ORIGINAL ARTICLE



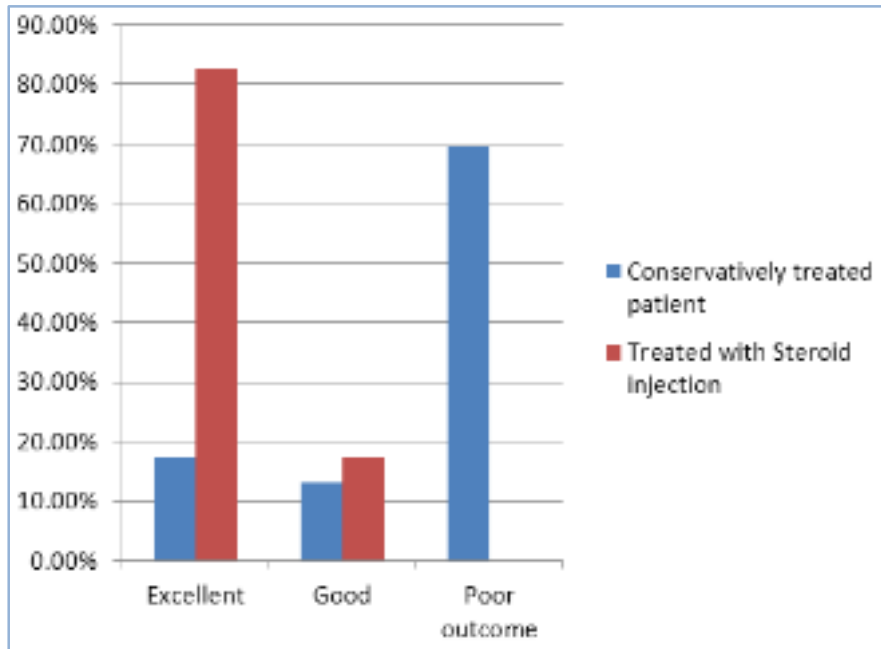
Effected side	Male	Female
Right	8 (66.67%)	54 (67.5%)
Left	4 (33.33%)	26 (32.5%)



Our study reveals 82.61% excellent results in group treated with steroid injection as compared to 17.39% in conservatively treated patients. A good result of 17.39% was noted in steroid treated cases while conservative patients showed 13.04%. Conservatively treated patients had a very poor outcome in 69.57% patients

Prognosis	Conservatively treated patient	Treated with Steroid injection
Excellent	8(17.39%)	38(82.61%)
Good	6(13.04%)	8(17.39%)
Poor outcome	32(69.57%)	0(0%)

ORIGINAL ARTICLE



CONCLUSION: Our study, concluded that patients who were treated with steroids had better prognosis compared to those underwent conservative management. The inflammatory process occurring in this disease can be very effectively controlled by local infiltration of the steroid into the tendon sheath. The result achieved with in one to two weeks is superior in comparison to conservative treatment using NSAID's, splints and occupational therapy.

REFERENCES:

1. Anderson M, Tichenor CJ. A patient with de Quervain's tenosynovitis: a case report using an Australian approach to manual therapy. *Phys Ther.* 1994; 74(4):314-26.
2. Ilyas AM, Ast M, Schaffer AA, Thoder J. De Quervain tenosynovitis of the wrist. *J Am Acad Orthop Surg.* 2007; 15(12):757-64.
3. Lamphier TA, Long NG, Dennehy T. Dequervain's disease: an analysis of 52 cases. *Ann Surg.* 1953; 138(6):832-41.
4. Wolf JM, Sturdivant RX, Owens BD. Incidence of de Quervain's tenosynovitis in a young, active, population. *J Hand Surg.* 2009; 34(1):112-5.
5. Jaworski CA, Krause M, Brown J. Rehabilitation of the wrist and hand following sports injury. *Clin Sports Med.* 2010; 29(1):61-80.
6. Rettig AC. Wrist and hand overuse syndromes. *Clin Sports Med.* 2001; 20(3):591-611.

ORIGINAL ARTICLE

<

AUTHORS:

1. Sreejith T. G.
2. Althaaf Mohamed A. H.

PARTICULARS OF CONTRIBUTORS:

1. Assistant Professor, Department of Orthopaedics, KMCT Medical College, Calicut.
2. Ortho Resident, Department of Orthopaedics, KMCT Medical College, Calicut.

FINANCIAL OR OTHER

COMPETING INTERESTS: None

NAME ADDRESS EMAIL ID OF THE CORRESPONDING AUTHOR:

Dr. Sreejith T. G,
Assistant Professor,
Department of Orthopaedics,
KMCT Medical College,
Calicut.
E-mail: dr.althaaf@hotmail.com

Date of Submission: 19/09/2015.
Date of Peer Review: 21/09/2015.
Date of Acceptance: 24/09/2015.
Date of Publishing: 28/09/2015.